

Juh-Wen Cheung¹
Jia-Fwu Shyu³
Chih-Chuan Teng⁴
Tien-Hua Chen^{1,2}
Cheng-Hsi Su¹
Yi-Ming Shyr¹
Jaang J Wang³
Chew-Wun Wu¹
Wing-Yui Lui¹
Jiang-Chuan Liu³

¹ Department of Surgery, Taipei Veterans General Hospital;

² Department of Anatomy, National Yang-Ming University; ³ Department of Biology and Anatomy, National Defense Medical Center; and ⁴ Chang Gung Institute of Technology, Taipei, Taiwan, R.O.C.

Key Words

carpal tunnel syndrome;
Lanz classification;
palmar cutaneous branch of median nerve;
palmaris longus

The Anatomical Variations of the Palmar Cutaneous Branch of the Median Nerve in Chinese Adults

Background. In a detailed analysis of the palmar cutaneous branch of median nerve (PCN) in the Chinese adults, we tried to evaluate its anatomic variation and clinical significance.

Methods. Observations were described in all the 60 specimens of the PCN at the wrist.

Results. The PCN was present in all 60 specimens and in most cases (88.3%) it originated from the radial side of the median nerve and the average length from the palmaris longus was 1.4cm; ulnarward (11.7%); only 5 cases (4.1%) were located at ulnar side and extended beyond the palmaris longus, the average distance being 0.3cm. Its mean point of origin was 3.2cm proximal to the distal wrist crease and the variations of the PCN in Lanz classification were: group 0 (31.7%), group 1 (40%), group 2 (15%), group 3 (0%) and group 4 (13.3%).

Conclusions. Longitudinal incision located 1cm on the ulnar side from palmaris longus could avoid injury to the PCN during decompression for carpal tunnel syndrome.

The anatomy of the palmar cutaneous branch of median nerve (PCN) at the wrist has been documented by many authors.^{1,2} Usually the median nerve passes below the flexor retinaculum and gives off the PCN, which distributes to the skin over the lateral part of the palm. In patients with carpal tunnel syndrome, the median nerve under the flexor retinaculum is tightly packed with the long flexor tendons of the finger with their surrounding synovial sheaths. The decompression of median nerve by sectioning the transverse carpal ligament (flexor retinaculum) is well accepted as the treatment of choice for patients with carpal tunnel syndrome. In 1972, Carroll and Green called attention to the possibility of PCN damage as a source of painful dysesthesia follow-

ing surgery for carpal tunnel syndrome.³ Taleisnk recommended a curved longitudinal incision located on the ulnar side of the long axis of the ring-finger ray.⁴ Hobbs concluded that the transverse carpal ligament should be located on the ulnar side of the long axis of the middle finger to prevent damage to the PCN.⁵ These studies have influenced surgeons to shift their incisions more toward the ulna in the interthenar area.

Neuroma of the PCN is a common complication of anterior wrist surgery after carpal tunnel decompression.⁶ To avoid injury to the PCN, a comprehensive evaluation of its distribution in the wrist region is essential. To understand this, we analyzed in detail the anatomical distribution of the PCN in the Chinese adults.

Received: January 23, 2003.
Accepted: October 8, 2003.

Correspondence to: Tien-Hua Chen, MD, Department of Surgery, Taipei Veterans General Hospital, 201, Sec. 2, Shih-Pai Road, Taipei 112, Taiwan.
Tel: +886-2-2875-7652; Fax: +886-2-2875-7537; E-mail: chen_th@vghtpe.gov.tw

This study provides not only important information for decreasing PCN injury but also racial differences in the PCN distribution.

METHODS

The series consisted of 120 PCNs without wrist surgery from specimens at the gross anatomy laboratories of the National Defense Medical Center, Taipei, Taiwan. The specimens were from 60 Chinese adults cadavers (48 male, 12 female). The median nerve was identified between the tendon of flexor carpi radialis and palmaris longus (PL) and then was picked up. Each PCN was identified using blunt dissection, and was traced proximally to its intraneural origin from the median nerve. Each PCN was then carefully dissected distally, dividing the skin overlying its course and tracing individual branches radially, and towards the ulna until its terminations in the under surface of the skin. We used the Lanz classification to group the variations encountered.² In addition, measurements of the following distances were also performed: a) the distance between the PCN radially to palmaris longus, b) the distance between the origin of the PCN to the distal palmar crease, and c) the distance between the ulnar side of the PCN to the palmaris longus (Fig. 1).

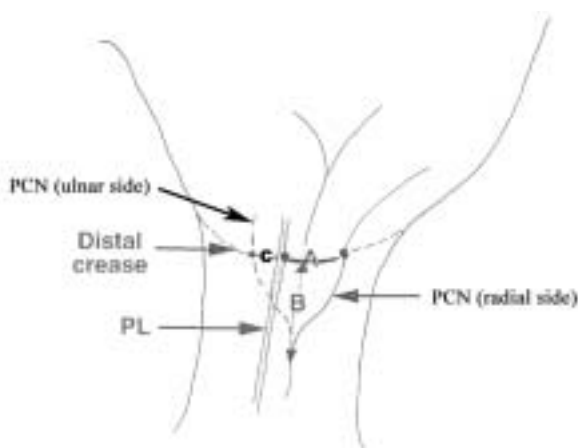


Fig. 1. Forearm and wrist reference points: (A) distance between the palmar cutaneous branch of median nerve (PCN) radially to the palmaris longus (PL), (B) distance between the origin of PCN to the distal palmar crease and (C) the distance between the ulnar side of the PCN to the PL.

Table 1. Details of the cadaveric limbs dissected

	Average	Range
Origin proximal to distal wrist crease	3.2 cm	1.2 - 6.5 cm
Length of radial branches from PL	1.4 cm	0.6 - 3.7 cm
Length of ulnar branches from PL	0.3 cm	0 - 0.8 cm

PL = palmaris longus.

Table 2. Classification of the variation of the median nerve related to the source of the anatomical findings (n = 120)

Group	n	%	p value
0	38 (12)	31.7 (48)	0.118
1A	30 (3)	25.0 (12)	0.158
1B	4 (3)	3.3 (12)	0.099
1C	14 (1)	11.7 (4)	0.469
1D	0 (0)	0.0 (0)	—
2	18 (5)	15.0 (20)	—
3A	0 (0)	0.0 (0)	0.551
3B	0 (0)	0.0 (0)	—
3C	0 (0)	0.0 (0)	—
4A	10 (1)	8.3 (4)	0.690
4B	6 (0)	5.0 (0)	0.590
Total	120 (25)		NS

For statistical analysis, Chi-squared test was used to compare our results with those of Stančić *et al.*⁷

RESULTS

The PCNs were present in all 60 cadavers. They were located under the tendons of PL and flexor carpi radialis. Most of the PCNs (106 specimens, 88.3%) originated from radial side of the median nerve. The average distance between the PCN and the PL at the level of distal wrist crease was 1.4 cm with a maximum of 3.7 cm. A total of 14 specimens (11.7%) of the PCNs originated on the ulnar side, but only 5 specimens (4.1%) extended beyond the PL. The average distance between the PCN and the PL at the level of distal wrist crease was 0.3 cm (range, 0 - 0.8 cm). The mean distance of the origin of the PCN to the distal wrist crease was 3.2 cm (range, 1.2 - 6.5 cm) (Table 1).

The variations of the PCN were classified as follows (Table 2 and Fig. 2).

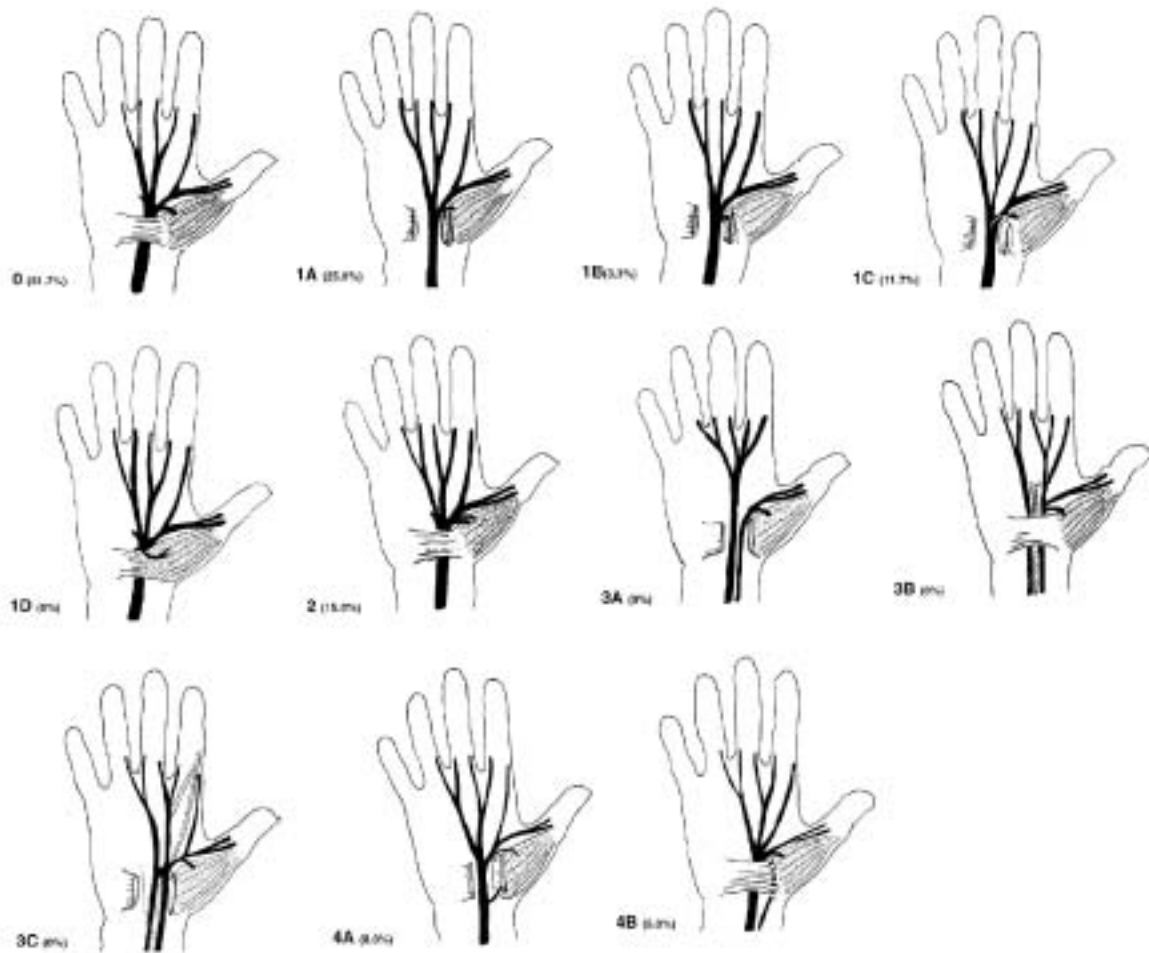


Fig. 2. The Lantz classification of anatomical the median nerve at the wrist in Chinese adults. Group 0 - regular branch of the median nerve. Group 1- variations of the course of the thenar branch: subgroup 1A - subligamentous; subgroup 1B - transligamentous; subgroup 1C - ulnarwards; subgroup 1D - supraligamentous. Group 2 - accessory branches of the median nerve at the distal carpal tunnel. Group 3 - high division of the median nerve: subgroup 3A - without an artery or muscle; subgroup 3B - with artery; subgroup 3C - with lumbrical muscle. Group 4 - accessory branches proximal to the carpal tunnel: subgroup 4A - direct in the thenar muscle; subgroup 4B - joint another branch. (From Ulrich Lantz 1975).

Group 0: In 38 specimens (31.7%), the PCNs branched above the flexor retinaculum.

Group 1: In 48 specimens (40%), the PCNs branched under the flexor retinaculum.

- Subgroup 1A, subligamentous, (25%);
- Subgroup 1B, transligamentous, (3.3%);
- Subgroup 1C, on the ulnar side, (11.7%);
- Subgroup 1D, supraligamentous, (0%).

Group 2: In 18 specimens (15%), distal accessory PCN branches of the median nerve to the carpal tunnel.

Group 3: No specimens in the high division of the median nerve.

Group 4: In 16 specimens (13.3%), proximal accessory

PCN to the carpal tunnel.

- Subgroup 4A, directly in the thenar muscle, (8.3%);
- subgroup 4B, joining another branch, (5%).

DISCUSSION

The PCN which is the last branch of the median nerve given off in the forearm, was present in all dissected specimens. Its origin was on average 3.2 cm proximal to the distal wrist crease, which differed from the results of Bezerra (4.6 cm)⁸ and Hobbs (8.4 cm).⁵ The shortest distance of the origin proximal to the wrist crease was

1.2 cm, which did not correspond to the results of Bezerra or Hobbs. The longest distance was 6.5 cm, which was similar to that of Bezerra (6.68 cm). However, they differed from the results of Hobbs (21.5 cm) due to high division of the PCN.

The PCN often originated on the radial side (88.3%) of the median nerve and the average distance between radial branches and palmaris longus was 1.4 cm (range, 0.6 to 3.7 cm), which is similar to the results of Hobbs⁵ (1.6 cm to the long axis of middle finger). Only in 14 specimens (11.7%) did the PCN originate on the ulnar side. The average distance between radial branches and palmaris longus was 0.3 cm, which was not different from the results of Hobbs (0.4 cm to the long axis of middle finger). In no specimen did a branch pass more than 1 cm. Therefore, a longitudinal incision placed 1 cm on the ulnar side to the PL can prevent damage to the nerve.

There were no statistical differences in the comparison of variations of PCN in the Chinese adults with the results by Stančić *et al.* ($p = 0.235$).⁷ In the Chinese subjects, the most common was group 1 (40%). Group 0 (48%) was the most common seen in a study by Stančić *et al.* As pointed out by Spinner, the transligamentous course of the PCN is of clinical importance in that the nerve may be compressed within the ligament.⁹ In our study, the subjects with transligament branches (1B) consisted of 3.3%, which was less than that (12%) reported by Stančić *et al.*

In our study, the distal accessory PCN appeared in 15% of the specimens (group 2), which was less than that reported by Stančić *et al.* (20%). The proximal accessory PCN appeared in 13.3% of the specimens (group 4), which was more than that reported by Stančić *et al.* (4%). Therefore, we emphasize the need for more precise surgical exploration. Incomplete decompression is a common complication occurring in up to 20% of the operations for carpal tunnel syndrome.¹⁰ This can be prevented by accurate dissection.

In 1972, Carroll and Green³ discussed the significance of anatomical details of the PCN in the wrist region and highlighted the problem of injury to this nerve, which could lead to postoperative symptoms ranging from mild annoyance to major hand disability. In 1973, Taleisnik⁴ dissected 12 cadaver hands and defined the origins, courses, and branches of the PCN. Taleisnik recom-

mended that a curved longitudinal incision be located on the ulnar side of the ring-finger ray and extend through the skin, subcutaneous tissue and transverse carpal ligament, but we found that the ulnar nerve might be injured by Taleisnik's method (unpublished finding). MacDonald *et al.* found a 12% complication rate in 186 operative cases of carpal tunnel released using the methods of Taleisnik.¹¹ Hobbs⁵ dissected 25 fresh adult cadaver hands and suggested that all branches of the PCN be avoided during carpal tunnel decompression if the skin incision is made 1 cm ulnar to the axis of the third metacarpal. In this study, we made incision using Hobb's method which could injure the PCN. The tendon of the palmaris longus is the most prominent object on the ventral surface of the flexed forearm. It can be easily localized for the operative landmark during wrist surgery. In addition, in no specimen did a branch of the PCN extend greater than 1 cm medial to the PL in our dissections. Therefore, we suggest that longitudinal incision be made 1 cm medial to the palmaris longus (Fig. 3). In our finding, the palmaris longus tendon was absent in 11 (9.1%) specimens.¹² If the patient had no PL, we suggested the Dr. Taleisnik's method to make a curved longitudinal incision located on the ulnar side of the axis of the ring-finger ray to identify the ulnar nerve.

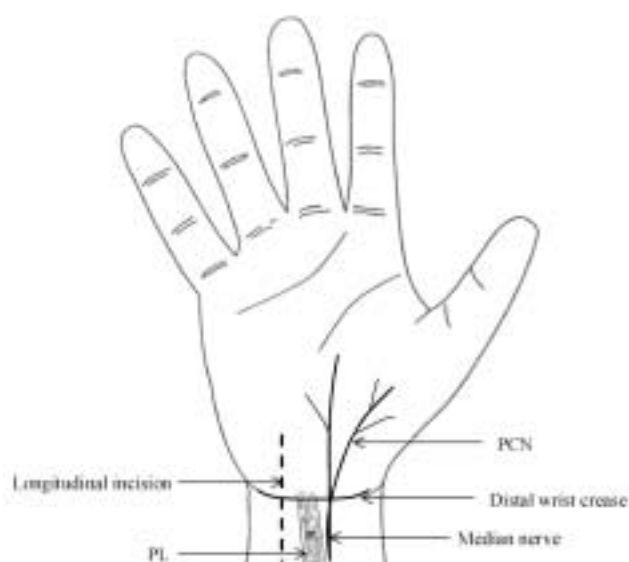


Fig. 3. Suggested incision for carpal tunnel decompression. As indicated, the longitudinal incision 1 cm medial to the palmaris longus (PL). PCN = palmar cutaneous branch of the median nerve.

It is important to bear in mind that the longitudinal incision 1cm medial to the PL will obtain great benefits for the PL during carpal tunnel syndrome decompression.

REFERENCES

1. Williams PL, Warwick R. *Gray's Anatomy*, 36th ed. London: Churchill Livingstone Publishers, 1980:1098-9.
2. Lanz V. Anatomical variations of the median nerve in the carpal canal. *J Hand Surg* 1977;2:44-53.
3. Carroll RE, Green DP. The significance of the palmar cutaneous nerve at the wrist. *Clin Orthop* 1972;83:24-8.
4. Taleisnk J. The palmar cutaneous branch of the median nerve and the approach to the carpal tunnel. *J Bone Joint Surg Am* 1973;12:12-7.
5. Hobbs RA, Magnussen PA, Tonkin MA. Palmar cutaneous branch of the median nerve. *J Hand Surg Am* 1990;15A:38-43.
6. Das SK, Brown HG. In search of complications in carpal tunnel decompression. *Hand* 1976;8:243-9.
7. Stančić MF, Eškinja N, Stošić A. Anatomical variations of the median nerve in the carpal tunnel. *Int Orthop* 1995;19:30-4.
8. Bezerra AJ, Carvalho VC, Nucci A. An anatomical study of the palmar cutaneous branch of the median nerve. *Surg Radiol Anat* 1986; 8:183-8.
9. Spinner MS. *Injuries to the Major Branches of the Peripheral Nerves of the Forearm*, 2nd ed. Philadelphia: W. B. Saunders, 1978;162-3.
10. Kulick MI, Gordillo G, Javidi T, Newmayer WL III. Long-term analysis of patients having treatment for carpal tunnel syndrome. *J Hand Surg Am* 1986;11:59-66.
11. MacDonald RI, Lichtman DM, Hanlon JJ. Complications of surgical release for carpal syndrome. *J Hand Surg Am* 1978;3:70-6.
12. Zaung ZC, Chen TH, Shyu JF, Lui WY, Liu JC. The relationship between the palmaris longus tendon and the palmar cutaneous branch of the median nerve. *J Plastic Reconstr Surg ROC* 2001;10:1-6.