

Case Report

J Chin Med Assoc

2004;67:37-40

Meng-Cheng Chiang¹

Wei-Hsian Yin^{1,3}

Hsu-Lung Jen¹

Mason Shing Young²

¹Division of Cardiology,

²Department of Internal Medicine,
Cheng-Hsin General Hospital and

³Institute of Clinical Medicine, National
Yang-Ming University School of
Medicine, Taipei, Taiwan, R.O.C.

Implantation of a Passive Fixation Dual Chamber Pacemaker in a Patient with Persistent Left Superior Vena Cava

Electrode instability and displacement have been reported in patients who underwent pacemaker implantation via persistent left superior vena cava. An active-fixation system, and sometimes epicardial pacing, is necessary to maintain pacing stability. We report the case of a 76-year-old man with a left superior vena cava who required dual-chamber permanent pacing. Passive-fixation atrial and ventricular leads were successfully inserted and produced good long-term pacing and sensing. To the best of our knowledge, this is the first reported case of implantation of a dual-chamber pacemaker via persistent left superior vena cava in Taiwan.

Key Words

dual-chamber pacemaker;

passive-fixation lead;

persistent left superior vena cava

Congenital abnormalities of the great vessels are common but important causes of pacemaker electrode instability, and persistent left superior vena cava (PLSVC) emptying into the coronary sinus is the most common of these.¹ It is possible to introduce a pacemaker lead into the right ventricle for single ventricular pacing.^{2,3} However, successful dual-chamber pacemaker implantation is rare, owing to difficulties in accessing the right atrial appendage and in achieving a stable electrode position. In reviewing the literature, we found that less than ten cases have been reported worldwide.⁴⁻¹⁰ In this report, we describe the successful implantation of a dual-chamber pacing system via a PLSVC using passive-fixation leads in both the right atrium and right ventricle, which obtained stable long-term pacing and sensing. To the best of our knowledge, this is the first report of a successful transvenous dual-chamber pacemaker implantation through this approach in Taiwan.^{11,12}

CASE REPORT

A 76-year-old man was admitted because of recur-

rent dizziness, fatigue, and exertional dyspnea occurring over 1 month. He had visited another hospital two days prior to admission, where a 24-hour Holter recording had revealed intermittent sinus bradycardia down to 26 beats/min, with junctional escape rhythm and frequent pauses of up to 2.7 seconds. A permanent dual-chamber pacemaker, Synchrony III 2028L (Pacesetter Systems, Sylmar, CA, USA), was implanted on June 26th, 1998. The incision was made in the left pectoral region, and the left cephalic vein was isolated. A bipolar ventricular electrode lead (Pacesetter, Membrane E 1450T-58cm, Sweden) was introduced via the left cephalic vein first. Then we made a left subclavian vein puncture, and a bipolar atrial J-lead (Pacesetter, Membrane E 1420T-52cm, Sweden) was inserted. Fluoroscopy during implantation revealed that both pacing catheters followed an abnormal course along the left border of the thoracic spine and entered the right atrium after passing through the coronary sinus. We used the wide loop technique reported by Hsiao *et al.*¹² to form a loop in the right atrium, and successfully advanced the ventricular lead into the right ventricular apex. A stable ventricular pacing threshold of 0.5V was obtained with

Received: September 3, 2002.

Accepted: September 2, 2003.

Correspondence to: Wei-Hsian Yin, MD, Division of Cardiology, Department of Internal Medicine, Cheng-Hsin General Hospital; 45, Cheng-Hsin Street, Pei-Tou, Taipei 112, Taiwan.
Tel: 886-2-2826-1242; Fax: 886-2-2826-1242; E-mail: yin.wh@msa.hinet.net

the tined lead tip located in the antero-apical part of the right ventricle. Ventricular pacing impedance was 560 ohms, and R-wave amplitude was 12 mV. The atrial lead positioning was done with the stylet slightly curved so that the “J-shaped” atrial lead could reach the interatrial septum; it was then fixed passively without much difficulty. Atrial pacing threshold was 0.7 V, pacing impedance was 620 ohms, and P-wave amplitude was 5.0 mV. The post-procedure electrocardiogram and chest radiography (Fig. 1) confirmed normal pacemaker function and stable electrode lead positions. We reviewed the preoperative chest X-ray film, which showed a crescentic shadow between the aortic arch and the middle third of the left clavicle. However, the patient’s preoperative echocardiographic study did not show any significant abnormal findings.

The patient has been doing well for 45 months as of this writing, and no displacement of the pacing leads or malfunctioning of the pacemaker has been demonstrated. Anticoagulation therapy using warfarin has been continued to prevent thrombo-embolic complications.

DISCUSSION

PLSVC, with or without right superior vena cava (RSVC), occurs in approximately 0.5% of the population, and is usually discovered incidentally and during pacemaker implantation procedures.⁶ Zerbe *et al.* reported that 4 out of 661 consecutive patients with permanent endocardial VVI pacing had the pacing lead introduced through a PLSVC.³ Identification of this anomaly is important because it may complicate proper positioning of an endocardial electrode during implantation; sometimes epicardial pacing is necessary.^{6,13} If a PLSVC has been identified before implantation, the presence or absence of a RSVC will probably be known. A RSVC would present an easier approach and would therefore be preferred, unless there was a strong reason to avoid operating on the patient’s dominant right side. More commonly, a PLSVC will be discovered unexpectedly at the time of implantation. At this point, the operator should proceed rather than abort the procedure. An assessment of the route of the PLSVC with intraoperative venography may prove helpful.¹¹ Even if placement through

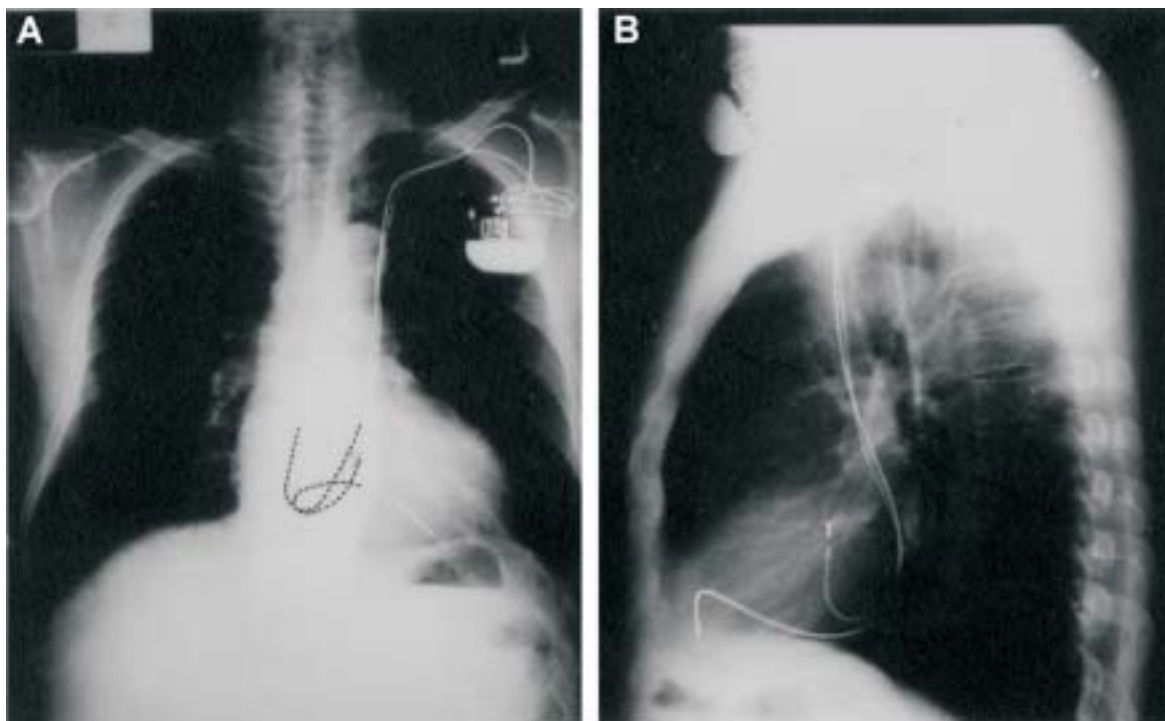


Fig. 1. The post-procedure chest radiography showed the ventricular lead tip located in the antero-apical part of the right ventricle and the atrial lead located at the interatrial septum. Both pacing catheters followed an abnormal course along the left border of the thoracic spine and entered the right heart chambers after passing through the coronary sinus.

the PLSVC fails, one should not incise the right subclavian area before ascertaining presence of a RSVC by means of venography or percutaneous catheter passage. If a RSVC is absent or diminutive, an epicardial route is then the only alternative.⁴

The presence of PLSVC may be suspected from the examination of a chest X-ray film and diagnosed by echocardiography or cardiac catheterization.^{12,14,15} On chest X-ray, it may present a widening of aortic shadow, paramedian bulging, paramedian strip, and crescentic shadow between the aortic arch and the middle third of the clavicle;¹² a dilated coronary sinus on two-dimensional echocardiography also indicates the possible presence of a PLSVC.¹⁴ However, not all patients with PLSVC have such findings, and only 68% of patients have been diagnosed successfully with transthoracic two-dimensional echocardiography.¹⁵ It is suggested that two-dimensional echocardiography, when combined with peripheral venous injection of contrast medium, will reliably demonstrate such an anomaly, and thus provides important information before pacemaker implantation.¹⁶ Our case presented a crescentic shadow between the aortic arch and middle third of the clavicle in his chest X-ray, but the echocardiographic study did not have any significant findings, so we did not perform contrast echocardiographic study on him. We discovered the PLSVC unexpectedly during the operation.

When the pacemaker lead enters the right atrium through a PLSVC and the coronary sinus, it often forms a loop in the right atrium and then enters the right ventricle. Rarely, a lead may reach the right ventricle without forming a loop.⁷ Ramsdale *et al.* did not recommend atrial loop formation, and considered that it might give rise to lead instability.¹⁷ However, most operators,^{3,4,8,12} including us, believe that the right atrial loop should remain to prevent dislodging forces. Different techniques^{3,6,12} have been proposed to advance the ventricular pacing lead in patients with PLSVC, and appropriate looping of a stylet can facilitate insertion of a lead to the right ventricle by directing the lead into the tricuspid orifice.^{3,12} Usually, the atrial lead can also be positioned satisfactorily at the interatrial septum,⁴ in the right atrial appendage,⁵ anterior wall⁹ or lower right atrium,¹¹ using an appropriately curved stylet and various maneuvers.

The proper choice of electrode has also been contro-

versial. Traditionally, active-fixation leads have been recommended to prevent the instability induced by the strange course of the electrodes, and this has been reported to produce excellent long-term ventricular pacing and sensing.^{8,9,18} However, several authors have reported that stable ventricular pacing can easily be obtained with the use of modern, passively-fixed tined or wedge flange leads.^{3,6,7,12} As for the atrial lead, some operators prefer active-fixation systems to reduce the risk of dislodgment and to allow for more choice of suitable sites for stable function than passive-fixation leads allow.^{7,9,19} However, this has also been challenged by other authors who have reported excellent long-term results using passive-fixation leads.^{4,6,8,11}

In our case, we used the wide loop technique reported by Hsiao *et al.*¹² to form a loop in the right atrium, and successfully advanced the passive-fixation ventricular lead in the right ventricular apex. For atrial pacing, a "J-shaped" atrial lead was used and passively fixed in the interatrial septum without much difficulty. Despite the known difficulties of using PLSVC as venous access, it was not as difficult as we had imagined it would be to successfully implant passive-fixation atrial and ventricular leads through this approach. As of the writing of this report, the patient has been followed for 45 months and is still without symptoms; an electrocardiogram and chest X-ray film confirm normal pacemaker function and stable electrode positions. Considering that the use of active-fixation leads is not without danger,¹⁰ and that there is no good evidence that the cause of the electrode displacement is the abnormal anatomy by itself, we endorse the use of both atrial and ventricular passive-fixation leads as a first choice in patients with PLSVC. Only when difficulty is encountered in obtaining or maintaining a stable electrode position should the electrode be actively fixed or an epicardial pacemaker implanted.

REFERENCES

1. Ward DE, Clarke B, Schofield PM, Jones S, Dawkins K, Bennett D. Long term transvenous ventricular pacing in adults with congenital abnormalities of the heart and great arteries. *Br Heart J* 1983;50:325-9.
2. Trigano JA. Permanent pacing through a persistent left supe-

- rior vena cava in 39 collected cases. *Clin Prog Electrophysiol Pacing* 1986;4:45-52.
3. Zerbe F, Bornakowski J, Sarnowski W. Pacemaker electrode implantation in patients with persistent left superior vena cava. *Br Heart J* 1992;67:65-6.
 4. Westerman GR, Baker J, Dungan WT, Van Devanter SH. Permanent pacing through a persistent left superior vena cava: an approach and report of dual-chambered lead placement. *Ann Thorac Surg* 1985;39:174-6.
 5. Zardo F, Nicolosi GL, Burelli C, Zanuttini D. Dual-chamber transvenous pacemaker implantation via anomalous left superior vena cava. *Am Heart J* 1986;112:621-2.
 6. Dirix LY, Kersschot IE, Fierens H, Goethals MA, Daele GV, Claessen G. Implantation of dual-chamber pacemaker in a patient with persistent left superior vena cava. *PACE* 1988;11:345-5.
 7. Roberts DH, Bellamy CM, Ramsdale DR. Implantation of a dual chamber pacemaker in a patient with persistent left superior vena cava. *International J Cardiol* 1992;36:242-3.
 8. Ashida Y, Mori T, Kuroda H, Ishiguro S, Hara Y, Tonomoto N. Transvenous dual chamber pacing via a unilateral left superior vena cava. *PACE* 1998;21:137-9.
 9. Antonelli D, Rosenfeld T. Implantation of dual chamber pacemaker in a patient with persistent left superior vena cava. *PACE* 1997;20:1737-8.
 10. Van Nooten G, Verbeet T, Deuvaert FE. Atrial perforation by a screw-in electrode via a left superior vena cava. *Am Heart J* 1990;119:1439-40.
 11. Huang SC, Kong CW, Chen CY. Permanent pacing through a persistent left superior vena cava: a case report of passive fixation atrial lead placement. *Acta Cardiol Sin* 1995;11:97-100.
 12. Hsiao HC, Kong CW, Wang JJ, Chan WL, Wang SP, Chang MS, Chiang BN. Right ventricular electrode lead implantation via a persistent left superior vena cava: an improved technique. *Angiology* 1997;48:919-23.
 13. Hussain A, Chakravarty S, Chaikhoui A, Smith JR. Congenital absence of superior vena cava: unusual anomaly of superior systemic veins complicating pacemaker placement. *PACE* 1981;4:328-34.
 14. Hibi N, Fukui Y, Nishimura K, Miwa A, Kambe T, Sakamoto N. Cross-sectional echocardiographic study on persistent left vena cava. *Am Heart J* 1980;100:69-76.
 15. Zellers TM, Hagler DJ, Julsrud PR. Accuracy of two-dimensional echocardiography in diagnosing left superior vena cava. *J Am Soc Echocardiogr* 1989;2:132-8.
 16. Foale R, Bourdillon PD, Somerville J, Rickards A. Anomalous systemic venous return: recognition by two-dimensional echocardiography. *Eur Heart J* 1983;4:186-95.
 17. Ramsdale DR, Charles RG. Endocardial pacing in a patient with sinus node dysfunction and absent right superior vena cava. *Br Heart J* 1984;52:230-2.
 18. Hellestrand KJ, Ward DE, Bexton RS, Camm AJ. The use of active fixation electrodes for permanent endocardial pacing via a persistent left superior vena cava. *PACE* 1982;5:180-4.
 19. Robbins EJ, Ruiter JH. Atrial pacing via unilateral persistent left superior vena cava. *PACE* 1986;9:594-6.