

Wen-Chiung Lin^{1,2,3,4}
Jia-Hwia Wang^{2,3}
Chao-Jun Wei^{2,3}
Cheng-Yen Chang^{2,3}

¹ Department of Radiology, Tri-Service
General Hospital;

² Department of Radiology, Taipei Veterans
General Hospital, and

³ Department of Radiology, National
Yang-Ming University School of
Medicine;

⁴ Department of Radiology, National
Defense Medical Center, Taipei, R.O.C.

Key Words

CT urography;
urinary tract;
urinary tract abnormalities;
urolithiasis

Assessment of CT Urography in the Diagnosis of Urinary Tract Abnormalities

Background. To evaluate the accuracy of helical computerized tomography urography (CTU) in diagnosing urinary tract disease.

Methods. We collected 102 patients who underwent CTU from March 2001 to September 2002. The clinical symptoms of these patients included: flank pain or hematuria, which were clinically suggestive of urinary system disorders. All patients received CT scan with or without intravenous contrast medium administration, except patients who had allergy history or poor renal function. Reformatted CT urography was performed and the accuracy of imaging diagnosis was evaluated.

Results. Of these 102 patients, 40 cases were proved to have urolithiasis, 24 cases were with renal or ureteral tumors, and there were 38 cases of other urinary system disorders (including inflammation, ureteral stricture and congenital anomalies). Precontrast CTU correctly diagnosed 39 of 40 urolithiasis cases (97.5%). Precontrast and contrast-enhanced CTU were performed in the non-urolithiasis group and correctly diagnosed 23 cases of renal or ureteral tumors, 4 cases of congenital disorder (2 duplications, 1 congenital renal agenesis due to VATER syndrome and 1 retrocaval ureter). Five of 34 patients with chronic inflammatory process of urinary tract or ureteral stricture were indistinct from malignancies according to the imaging of CT urography.

Conclusions. CTU is good modality for demonstration of urinary tract disorders. It is better in showing radiolucent stones and non-opacified urinary system. CTU demonstrates more soft tissue information than IVU in the patients with urinary tract tumors. CTU may be an alternative modality for patients with deterioration of renal function or allergic history of contrast medium.

Intravenous urography (IVU) has long been the major and first-line modality in evaluating GU tract abnormalities. However, the imaging findings are prone to be affected by artifacts (bowel gas or bowel content), and poor or non-opacified urinary tract (due to impairment renal function).^{1,2} For radiolucent stones, IVU is also limited. The aforementioned conditions are in prejudice of instantly and correctly diagnosing urinary tract abnormalities. These situations not only for the clinician to order extra examinations for further evaluation urinary tract disorders, but the final diagnosis and proper management for patient with acute clinical symptoms will also be delayed.³ Because of the limitations in correctly diagnosing urinary tract abnormality by IVU, a more accurate and rapid substitute modality for IVU is war-

ranted. With improvement in examination techniques of CT, helical CT scan has become an alternative modality in evaluating urinary tract abnormalities, especially for urolithiasis.¹ The good imaging resolution and rapid examination time of helical CT significantly improves examination course compared to that of IVU. But the axial images of CT may cause some interpretation difficulties for clinicians who are familiar to analyze coronal images for IVU. Reformatted 3-dimension (3D) CT urography from thin-cut axial helical CT scan can create a coronal imaging which is like the imaging of IVU. Three-dimensional CT urography is not only easily interpreted by the clinicians who are unfamiliar with axial CT image, but it also improves the accuracy in diagnosing urinary tract abnormalities.⁴ Here we performed reformat-

Received: April 16, 2003.
Accepted: November 4, 2003.

Correspondence to: Jia-Hwia Wang, MD, Department of Radiology, Taipei Veterans General Hospital, 201, Sec.2, Shih-Pai Road, Taipei 112, Taiwan.
Tel: +886-2-2871-2121, ext 3342; E-mail: Lin620102@yahoo.com.tw

ted CT urography for patients with clinical symptoms that highly suggested urinary tract abnormalities, and evaluated the diagnostic value of CT urography.

METHODS

From March 2001 to September 2002, 102 consecutive patients (61 men and 41 women, age ranged from 5 to 84 years old, mean age 53.4 years) who had acute renal colic or hematuria that highly suggested urinary tract abnormalities underwent non-enhanced helical and excretory phase CT for evaluating the urinary system. Women who were pregnant or prepared for pregnancy were excluded from this study. The non-enhanced and excretory phase, contrast-enhanced helical CT studies were performed with a multidetector row CT scanner (Light Speed QX/I version 1.3; GE Medical Systems, Milwaukee, WI, USA). CT scans were obtained from the kidneys to the bladder with the following technique: a collimator of 5 mm, a pitch of 6, and with 200 mAs. Images were reconstructed at a thickness of 2.5 mm with intervals of 1.25 mm. Three-dimensional (3D) reconstructions of the non-

enhanced and excretory phase, contrast-enhanced helical CT scans were performed at a workstation (GE Advantage for Windows 4.0; GE Medical Systems) by an experienced technician supervised by a radiologist who is expert in genitourinary radiology. The 3D reconstructions in coronal and bilateral 25- to 35-degree coronal oblique projections were created with multiple planar reconstructions (MPR). Retrospective comparison the results of the CT urography with other clinical results (pyeloureteroscopy, surgery or spontaneous passage of the urolithiasis), and imaging examinations (retrograde pyelography or sonography) were performed.

RESULTS

Of these 102 patients, 40 cases were proven to have urolithiasis, 24 cases were with renal or ureteral tumors, and there were 38 cases of other urinary system disorders (including 34 cases of inflammation and ureteral stricture, 4 cases of congenital anomalies). Precontrast CTU correctly diagnosed 39 of 40 urolithiasis cases (97.5%) (Figs. 1, 2). Precontrast and contrast-enhanced CTU were

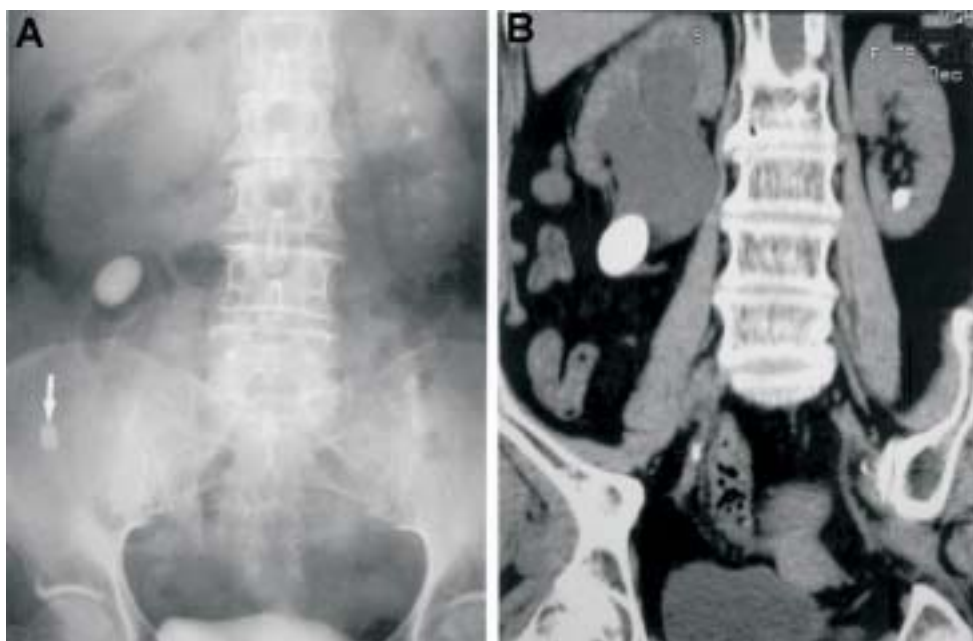


Fig. 1. A 79-year-old male patient presented with acute right flank pain. (A) The intravenous urography (IVU) shows 1 calcified stone at the right flank region. The right kidney is not opacified due to deterioration of renal function. Therefore, the obstruction level of urinary tract cannot be shown. (B) Non-contrast CT urography clearly demonstrates stone located at right uretero-pelvic junction with marked right hydronephrosis. An appendicolith noted in Fig. 1A (arrow) is also depicted by the CT scan as an associated finding.

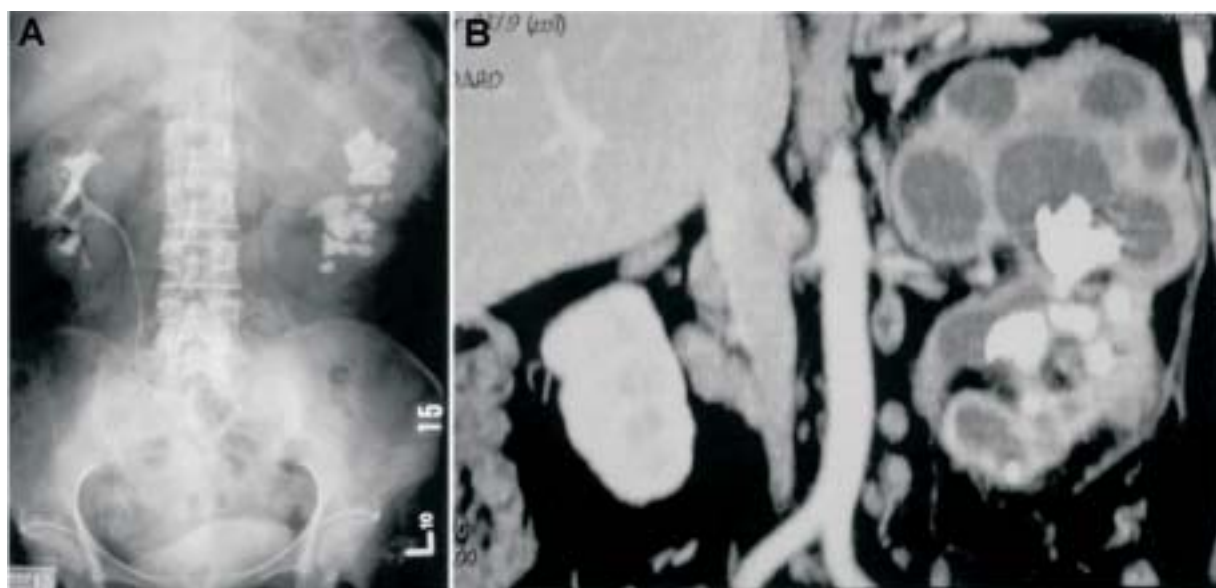

Fig. 2. A 56-year-old woman with history of diabetes mellitus, clinically manifested as fever and left flank pain. (A) IVU shows minimal enhancement of left kidney, with suspicious space occupying mass at upper pole. A staghorn stone of the left kidney is also noted. (B) CT urography shows multiple loculated cysts of the upper pole of the left kidney and staghorn stone within the left renal pelvis. Xanthogranulomatous pyelonephritis was diagnosed by CT urography with subsequently surgical confirmation.

performed in the non-urolithiasis group and correctly diagnosed 23 cases of 24 renal or ureteral tumors (95.8%) (Fig. 3), and 4 cases of congenital disorders (100%) (Figs. 4, 5) (2 duplications, 1 congenital renal agenesis due to VATER syndrome and 1 retrocaval ureter). Twenty-nine of 34 patients (85.3%) with chronic inflammation of GU tract or ureteral stricture were correctly diagnosed by CT urography (Fig. 6). CT urographic findings of the remaining 5 of 34 patients could not be distinguished from neoplasm of urinary tract (Fig. 7). The final diagnosis of malignancy was excluded in these 5 patients only after biopsy or brushing cytology by ureteroscopy.

DISCUSSION

Because of the good imaging resolution and rapid examination time of helical CT scan, it has become a promising modality for diagnosing urinary tract abnormalities. By improvement of the computer technique, 3D CT urography reformatted from axial thin-cut multi-slice CT imaging is capable of providing more diagnostic information than that by conventional CT.⁴ The radiation dose is also markedly reduced by using the design of multiple-detector of helical CT scan. Recent study showed

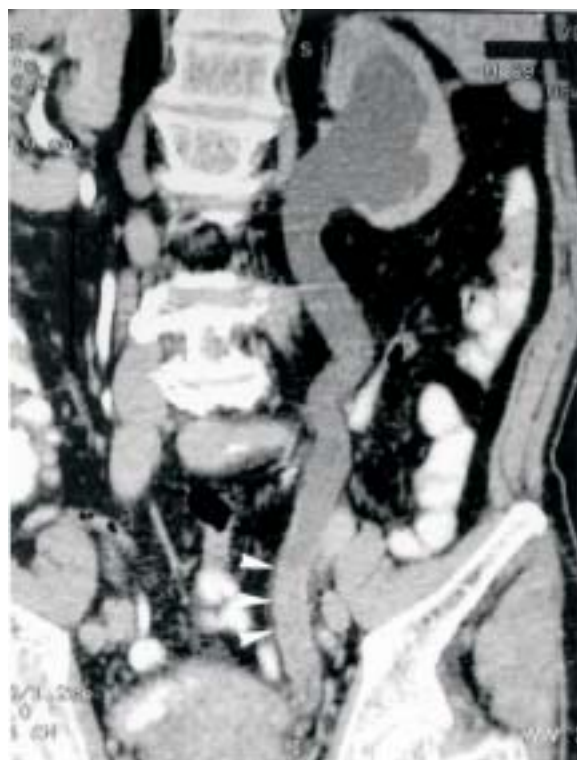

Fig. 3. A 69-year-old man with gross hematuria for 1 month. CT urography shows marked left hydronephrosis and hydroureter. Note increased soft tissue density of the left distal ureter (arrowheads) which causes obstruction uropathy. Urothelial cell tumor of the left distal ureter was impressed, and was proved by surgery.

that the radiation dose of CT urography was similar or just slightly greater than that of IVU.⁵

According to our results, CT urography displayed extremely high accuracy in diagnosing urolithiasis (sensitivity 97.5%, specificity 100%). Because most urolithiasis

is radiopaque on CT scan, non-enhanced CT urography is sufficient in diagnosing urolithiasis without intravenous contrast medium administration. According to 1 recent study, noncontrast CT demonstrated superior sensitivity to IVU in detecting renal tract calculi.¹ By using

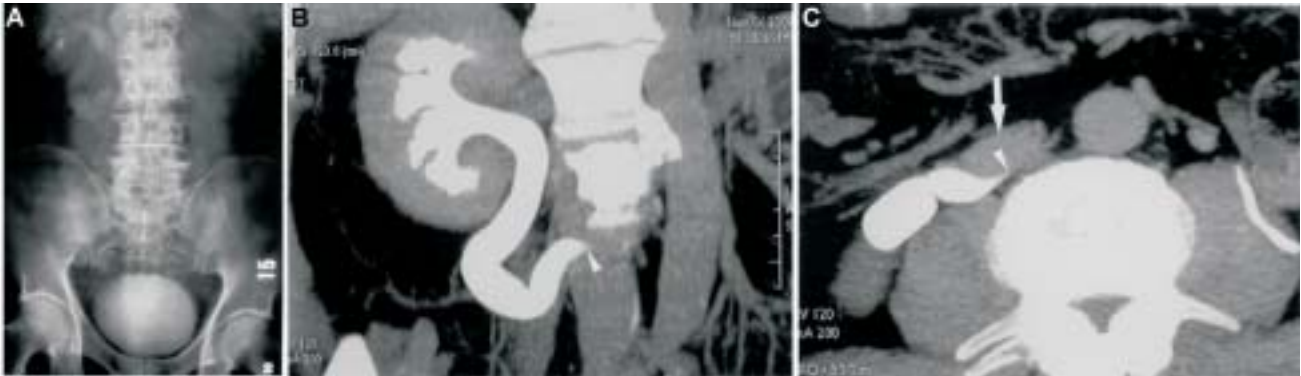


Fig. 4. A 48-year-old man with clinical presentation of right flank pain. (A) IVU shows moderate hydronephrosis and hydroureter of the right side with the presence of a tortuous right ureter. (B, C) Post-contrast CT and reformatted CT urography show the same findings of IVU, however, bird beak-like narrowing at the upper third of the right ureter (arrowheads), which is compressed by IVC (arrow), is clearly demonstrated. Retrocaval ureter was diagnosed.

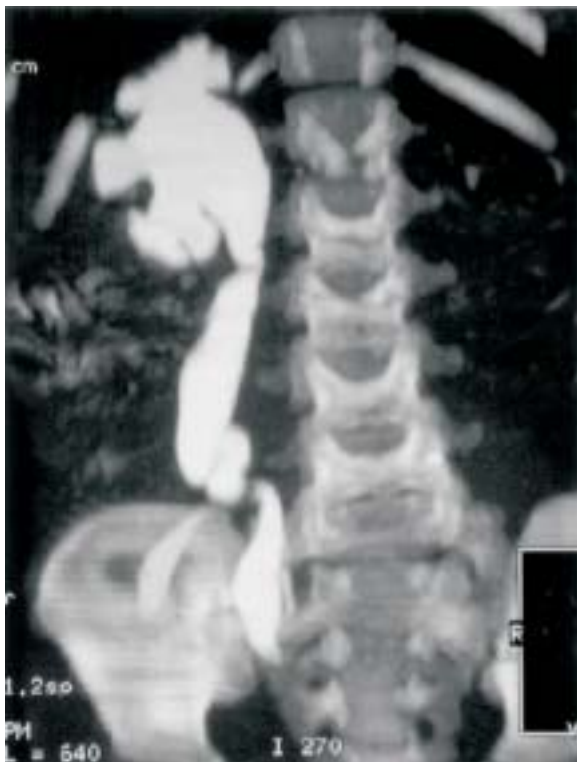

Fig. 5. A 5-year-old boy with a history of congenital heart disease who presented with symptoms of recurrent urinary tract infection. CT urography shows agenesis of the left kidney. Marked right hydronephrosis and hydroureter is also noted. VATER syndrome of this boy was diagnosed.

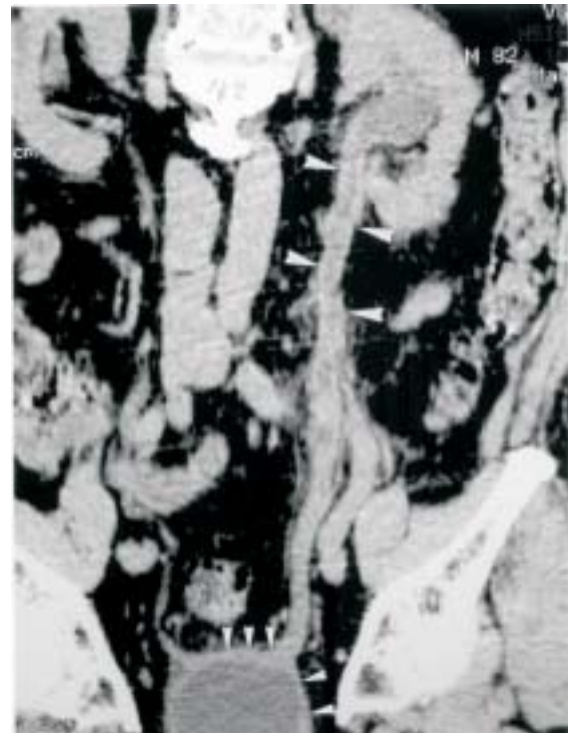

Fig. 6. A 82-year-old man with clinical manifestation of left flank pain and dysuria. The non-contrast CT urography shows irregular thickening of the entire left ureter and urinary bladder wall (arrowheads). Chronic inflammatory process was impressed. Biopsy was performed and revealed granulomatous change histopathologically. The diagnosis of urinary TB was made.

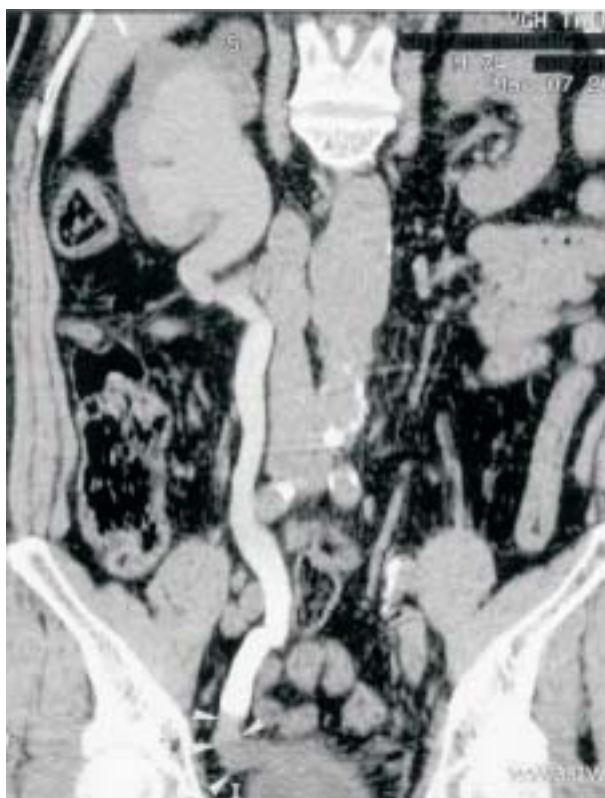

Fig. 7. A 74-year-old man with gross hematuria for 1 week. The CT urography was performed after retrograde pyelography. It shows marked right hydronephrosis and hydroureter caused by soft tissue density (arrowheads) at the right distal ureter. The CT urographic findings suggest right distal ureter neoplasm. However, the result of biopsy showed only some inflammatory cells infiltration.

non-enhanced CT urography as the diagnostic modality for patients with clinical suspicion of urolithiasis, the unwarranted side effects due to IV contrast medium during IVU could also be prevented. Furthermore, it is also beneficial in improving the diagnostic rate of urolithiasis when analyzing radiographs in conjunction with CT scans and CT urography.⁴ Although almost all renal stones are radiopaque on CT scan, in extremely rare conditions, they are radiolucent due to variable component of renal stones.² In just 1 of our cases, radiolucency of the renal stone with only mild marginal calcification was noted in the renal pelvis; which was falsely interpreted as renal pelvic tumor. Other studies also reported that phleboliths might mimic renal stones at the pelvic region, especially in those patients who lack adipose tissue at the pelvic cavity, which may cause diagnostic pitfalls.^{6,7} We did not encounter this situation in our patients, probably

due to the number of cases being limited. However, our experience suggests that 3D reformatted CT urography can provide more information in distinguishing phleboliths from renal stones than can conventional axial CT scan, by viewing the anatomic relationship with multiplanar images.

CT urography also has good potential for diagnosing neoplasms in the urinary tract. In our 102 patients with clinical manifestations of urinary tract disorders, CT urography correctly detected 23 out of 24 patients with urinary tract tumors (1 angiomyolipoma, 21 urothelial cell carcinomas, 1 renal cell carcinoma, 1 rhabdomyosarcoma of the urinary bladder), which were proved by surgical intervention and biopsy. In our experience, CT urography has superior sensitivity in detecting neoplasms in the urinary system than IVU does, especially in patients with impaired renal function so that the urinary system could not be opacified on IVU. CT urography is also better in demonstrating the extent of tumor involvement than axial conventional CT scan. However, CT urography is limited in detecting early neoplasms arising from the urothelial epithelium, which can be better demonstrated on ureteroscopy, just as in 1 of our patients, who had early superficial urothelial cell carcinoma of the ureter, and was misinterpreted as negative findings on CT urography.

We also detected 4 congenital urinary abnormalities (including 2 cases of duplication with ectopic ureter, 1 case of retrocaval ureter, and 1 renal agenesis of VATER syndrome). We found that CT urography was effective in diagnosing these congenital disorders; the same conclusion was also made by another investigation.⁸ CT urography also provides more information than IVU in determining the nature of ureteral stenosis,⁵ and our result also supports this point. Twenty-nine of 34 patients were correctly diagnosed as ureteral stenosis by CT urography, which was proved by ureteroscopy. However, in our experience, CT urography is sometimes limited in differentiating chronic inflammatory process from neoplastic change. In our 34 patients with ureteral stricture or chronic inflammation, the images of CT urography initially could not distinguish 5 cases of chronic inflammatory change from urinary neoplasms (Fig. 7). According to the result of CT findings with histopathologic confirmation in our study, increased soft tissue density due to soft tissue edema or fibrotic change in inflammatory

changes of the urinary tract may mimic neoplasm. Since chronic inflammatory processes of urinary tract may have confusing imaging findings that are indistinct from malignancy, we suggest follow-up of the patient's clinical course and histopathological correlation are necessary.

In conclusion, CT urography is a newly developed modality for evaluating urinary tract abnormalities. Our preliminary results show CT urography is exceptional in diagnosing urinary tract abnormalities, especially in urolithiasis. It also can provide more information on the non-urinary tract abnormality of the patients. Considering the diagnostic value and immediate proper management for patients of urinary tract disorders, CT urography is a promising examination and should be an alternative or substitute modality for IVU.

ACKNOWLEDGEMENTS

This study was supported by a grant from Veterans General Hospital (VGH91-227), Taipei, Taiwan, R.O.C.

REFERENCES

1. Niall O, Russell J, MacGregor R, Duncan H, Mullins J. A comparison of noncontrast computerized tomography with excretory urography in the assessment of acute flank pain. *J Urol* 1999;161:534-7.
2. Hamm M, Wawroschek F, Weckermann D, Knopfle E, Hackel T, Hauser H, *et al.* Unenhanced helical computed tomography in the evaluation of acute flank pain. *Eur Urol* 2001;39:460-5.
3. Vieweg J, Teh C, Freed K, Leder RA, Smith RH, Nelson RH, *et al.* Unenhanced helical computerized tomography for the evaluation of patients with acute flank pain. *J Urol* 1998;160:679-84.
4. Van Beers BE, Dechambre S, Hulcelle P, Materne R, Jamart J. Value of multislice helical CT scans and maximum-intensity-projection images to improve detection of ureteral stones at abdominal radiography. *Am J Roentgenol* 2001; 177:1117-21.
5. Caoili EM, Cohan RH, Korobkin M, Platt JF, Francis IR, Faerber GJ, *et al.* Urinary tract abnormalities: initial experience with multi-detector row CT urography. *Radiology* 2002; 222:353-60.
6. Preminger GM, Vieweg J, Leder RA, Nelson RC. Urolithiasis: detection and management with unenhanced spiral CT—a urologic perspective. *Radiology* 1998;207:308-9.
7. Katz DS, Lane MJ, Sommer FG. Unenhanced helical CT of ureteral stones: incidence of associated urinary tract findings. *Am J Roentgenol* 1996;166:1319-22.
8. Kim JK, Cho KS. Pictorial review: CT urography and virtual endoscopy: promising imaging modalities for urinary tract evaluation. *Br J Radiol* 2003;76:199-209.