

Case Report

Isolated Oculomotor Nerve Palsy Due to Head Injury

Yo-Tsen Liu^{1,2}
Yi-Chung Lee^{1,2}
Hsiu-Chih Liu^{1,2}

¹ The Neurological Institute, Taipei Veterans General Hospital;

² The Department of Neurology, National Yang-Ming University School of Medicine, Taipei, Taiwan, R.O.C.

Traumatic isolated oculomotor nerve palsy with negative imaging studies is extremely rare. We reported such a case who after head injury had normal brain computerized tomography (CT), magnetic resonance imaging (MRI), and angiography. The absence of other neurological signs and normal brain MRI indicated the lesion was most likely within the subarachnoid space, as the other important structures near the third nerve, such as the brainstem, cavernous sinus and orbit, were undamaged. The prognosis of traumatic oculomotor palsy is usually poor. Generally speaking, patients experience more rapid and complete recovery of ptosis than of extraocular movements, while pupillary size and light reflex show the least degree of recovery. Further case collections with modern imaging studies are needed to clarify the mechanisms and clinical characteristics associated with this phenomenon.

Key Words

head injury;

traumatic oculomotor nerve palsy

Oculomotor nerve palsy following closed head trauma may be caused by direct injury of the nerve or by indirect compression of the nerve by an expanding supratentorial hematoma. Direct traumatic oculomotor nerve palsy is uncommon and is usually associated with subarachnoid hemorrhage, skull fracture, aneurysm, carotid-cavernous fistula or midbrain lesion.¹⁻³ Brain computerized tomography (CT) is recommended in acutely traumatized patients with the third nerve palsy to rapidly evaluate blood, bone, and supratentorial structures.⁴ Cerebral angiography is indicated when a vascular anomaly is the possible etiology.² A complete imaging investigation for traumatic oculomotor nerve palsy should include brain magnetic resonance imaging (MRI), because CT may fail to detect midbrain damage and oculomotor nerve root avulsion.³ Traumatic isolated oculomotor nerve palsy with negative imaging studies is extremely rare. Here we report a case of isolated oculomotor nerve palsy after head injury with normal brain CT, MRI and angiography. Prognosis and possible mechanisms are also discussed.

CASE REPORT

In May 2002, a 55-year-old woman was transported to the emergency department following a motor vehicle accident. While riding a motorcycle, she was struck from behind by a truck and lost consciousness for several minutes. On examination, she was alert, but with retrograde amnesia concerning events related to the accident. She had abrasion wounds on her left frontal and periorbital regions and had complete ptosis of the left eye with a fixed and dilated pupil measuring 6 mm in diameter. Her left eye could only move outward and depress inward (Fig. 1A). Otherwise, her neurological examination was without focal abnormality.

Skull X-ray studies and orbital CT immediately after the accident were normal. Brain MRI with T1 and T2 weighted images and cerebral angiography were arranged 3 weeks after the onset and both failed to reveal abnormal findings. The patient was discharged without specific treatment. Three months later, ptosis was partially resolved, and there was restoration of ocular motion in the direction of adduction. Four months

Received: November 11, 2002.

Accepted: October 7, 2003.

Correspondence to: Dr. Hsiu-Chih Liu, Neurological Institute, Taipei Veterans General Hospital, 201 Sec. 2, Shih-Pai Road, Taipei 112, Taiwan.

Fax: +886-2-2873-8696; E-mail: hcliu@vghtpe.gov.tw

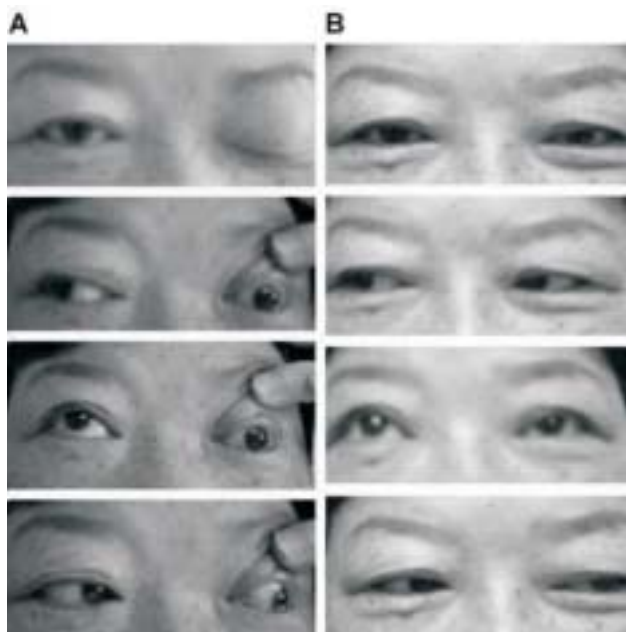


Fig. 1. (A) Three weeks after the accident, the patient had complete ptosis of the left eye and total limitation in the inward and upward ocular movement. (B) Four months after the accident, the ptosis was almost completely resolved, and the inward movement of the left eye was restored. However, there was still some limitation in the upward ocular movement.

after the accident, ptosis was almost completely resolved. Inward and downward movement of the left eye was restored (Fig. 1B). However, upward palsy and the 4mm dilated pupil persisted.

DISCUSSION

Traumatic isolated oculomotor nerve palsy with negative imaging studies is extremely rare. Nagaseki *et al.* have identified 6 patients with internal ophthalmoplegia from a population of 929 patients admitted with head injury.⁵ Only 1 patient had isolated oculomotor nerve palsy with normal brain CT, although MRI was not performed in this patient. A 3-month follow-up of this patient demonstrated persisted anisocoria. Muthu *et al.* reported the sole case of traumatic isolated oculomotor nerve palsy with normal MRI and cerebral angiography.⁶ Throughout 10-month follow-up, the patient experienced partial improvement in third nerve palsy. Our patient presented with isolated complete left third nerve palsy with negative imaging studies, and was the second case reported with a

complete investigation including brain MRI. These 2 similar cases implied that isolated traumatic nerve palsy with negative image studies is not an accidental finding. The absence of other neurological signs and normal brain MRI indicated that the lesion was most likely within the subarachnoid space. Oculomotor nerve root avulsion was the most favored mechanism, as the other important structures near the third nerve, such as the brainstem, cavernous sinus and orbit, were undamaged.⁷

Although the current patient showed continued improvement in oculomotor nerve palsy and was expected to achieve full recovery, the prognosis of traumatic oculomotor palsy is usually poor. In a series described by Tokuno *et al.*, none of the 10 patients with oculomotor nerve palsy achieved complete recovery after 3-18 months of follow-up.¹ In another series by Memon *et al.*, only 1 of 12 patients recovered fully in the 6 months to 3 years after the traumatic event.⁸ Generally speaking, patients experienced more rapid and complete recovery in ptosis than in extraocular movements, while pupillary size and light reflex showed the least recovery.¹⁻⁸ Difference of functional recovery of muscles innervated by the oculomotor nerve might suggest topographical arrangement of the nerve fibers for each muscle. In our patient, favorable functional recovery of the levator palpebrae superioris, medial rectus and inferior rectus suggest that their fibers were spatially associated in the oculomotor nerve.

In conclusion, isolated oculomotor nerve palsy due to head injury with normal complete imaging studies is rare. Further case collections with modern imaging studies are needed to clarify the mechanisms and clinical characteristics associated with this phenomenon.

ACKNOWLEDGEMENT

The study was supported in part by a grant from the Taipei Veterans General Hospital (VGH-318).

REFERENCES

1. Tokuno T, Nakazawa K, Yoshida S, Matsumoto S, Shingu T, Sato S, *et al.* Primary oculomotor nerve palsy due to head in-

- jury: analysis of 10 cases. *No Shinkei Geka* 1995;23:497-501.
2. Walter KA, Newman NJ, Lessell S. Oculomotor palsy from minor head trauma: initial sign of intracranial aneurysm. *Neurology* 1994;44:148-50.
 3. Balcer LJ, Galetta SL, Bagley LJ, Pakola SJ. Localization of traumatic oculomotor nerve palsy to the midbrain exit site by magnetic resonance imaging. *Am J Ophthalmol* 1996;122:437-9.
 4. McCann JD, Seiff S. Traumatic neuropathies of the optic nerve, optic chiasm, and ocular motor nerves. *Curr Opin Ophthalmol* 1994;5:3-10.
 5. Nagaseki Y, Shimizu T, Kakizawa T, Fukamachi A, Nukui H. Primary internal ophthalmoplegia due to head injury. *Acta Neurochir* 1989;97:117-22.
 6. Muthu P, Pritty P. Mild head injury with isolated third nerve palsy. *Emerg Med J* 2001;18:310-1.
 7. Bianchi-Marzoli S, Brancato R. Third, fourth, and sixth cranial nerve palsies. *Curr Opin Ophthalmol* 1997;8:45-51.
 8. Memon MY, Paine KWE. Direct injury of the oculomotor nerve in craniocerebral trauma. *J Neurosurg* 1971;35:461-4.