

Min-Che Tung  
William J. Huang  
Kuang-Kuo Chen

Division of Urology, Department of Surgery, Taipei Veterans General Hospital and Department of Urology, National Yang-Ming University, School of Medicine, Taipei, Taiwan, R.O.C.

---

**Key Words**

male infertility;  
varicocele;  
varicocelectomy

## Modified Subinguinal Varicocelectomy for Painful Varicocele and Varicocele-associated Infertility

**Background.** Patients with varicocele comprise 15% of males in general population. Varicocele is considered the most cost-effectively treatable cause of male infertility. We introduce a modification in technique of subinguinal varicocelectomy and review the outcome of 58 patients from July 2000 to July 2002.

**Methods.** Four out of the 58 cases had both pain and infertility. For the 31 infertility patients, 8 (25.8%) were azoospermic, and testis biopsy was also performed. Post-operatively, we followed these patients on every-3-month basis with semen analysis, physical recovery and situation of fecundity. Patients with painful varicocele (n = 31) were also followed with physical check-up and optional semen analysis.

**Results.** Fifty-four men had left varicocele only, while 4 had bilateral lesions. In the painful varicocele group, 28 of 31 patients (90%) felt complete resolution of pain and 3 patients (10%) felt partial resolution of pain. In the infertility group, 8 patients had asthenospermia only, 15 had oligo-asthenospermia and 8 were azoospermic. During the follow-up, 6 out of the 23 non-azoospermic couples (32%) got spontaneous pregnancy in 7 months in average. For the 8 azoospermic patients, the simultaneous testicular biopsy revealed Sertoli-cell-only syndrome in 4, maturation arrest in 3 and hyalinization of tubules in 1. However, they stayed azoospermic after the procedure. In oligo-asthenospermic patients (n = 15), mean sperm concentration improved from 6.1 to  $24.2 \times 10^6/cc$  ( $p < 0.02$ ). Improvement in morphology and motility were only significant in the patients with grade 3 varicocele.

**Conclusions.** The newly modified technique of subinguinal varicocelectomy is an effective procedure to either eliminate the pain of varicocele or improve the semen parameters in infertility patients. The procedure is also very promising in avoiding complication and residual lesions.

Varicocele is common, affecting about 15% of the male general population.<sup>1</sup> However, it comprises one-third of the cases seen in daily male infertility service.<sup>2</sup> In patients suffering from male infertility, varicocele is also considered 1 of the most promising treatable causes. Most of the published reports agreed on the benefits of varicocelectomy in improving sperm quality and pregnancy rates as well as eliminating painful sensation in the scrotum.<sup>3,4</sup> The goal of varicocelectomy is to disrupt all internal venous drainage of the testis, except the veins of vas deferens.<sup>5</sup> Since the first introduction of varicocelectomy by Tulloch in 1955,<sup>6</sup> many sur-

gical modifications have been developed, such as retroperitoneal approach to transect the internal spermatic vein by Palomo,<sup>7</sup> trans-inguinal ligation,<sup>8</sup> sub-inguinal ligation by Marmar,<sup>9</sup> and laparoscopic supra-inguinal ligation. Till now, they are all still available in different institutes to treat patient according to the surgeons' preference or facility availability.

At our institution, we use sub-inguinal approach varicocelectomy under spinal anesthesia. The spermatic artery, lymphatics and vas compartment are preserved in these procedures. Here we present the outcome of the treatment, as well as the details of our modifications in

---

Received: June 27, 2003.  
Accepted: March 3, 2004.

---

Correspondence to: William J. Huang, MD, PhD, Division of Urology, Department of Surgery, Taipei Veterans General Hospital, 201, Sec. 2, Shih-Pai Road, Taipei 112, Taiwan.  
Tel: +886-2-2875-7519 ext 307; Fax: +886-2-2875-7540; E-mail: jshuang@vghtpe.gov.tw  
This work has been reported at the Annual Meeting of Taiwanese Association of Andrology, March 9, 2003.

techniques.

## METHODS

A total of 58 patients with varicocele receiving subinguinal varicocelectomy from July 2000 to July 2002 were reviewed. The diagnosis was made by physical examination. The grading of varicocele was classified to grade 1: palpable only with Valsalva's maneuver; grade 2: palpable tortuous vein without Valsalva's maneuver; and grade 3: easily visible through the scrotal skin. For patients with only grade 1 varicocele, the caliber of the engorged veins was also measured by Doppler ultrasound. The indications for treatment were either with painful scrotum or with infertility problem. Reviewing the chief complaint of these patients, 27 (46.5%) were due to painful scrotum only, 27 (46.5%) were due to infertility dysfunction, and the other 4 (7%) suffered from both pain and infertility. For the infertility group ( $n = 31$ ), semen analysis and hormone profiles were recorded. According to the results of semen analysis, they were further stratified into 3 subgroups, namely azoospermia, oligo-asthenospermia and asthenospermia only.

Most of the operations were performed by 1 surgeon (WJH), and some cases were done by senior residents and supervised by the same surgeon. The patient was put in supine position under spinal anesthesia. The incision was made transversely about 2 to 2.5 cm at the level of external inguinal ring, just outside the pubic tubercle (Fig. 1). The dissection was advanced caudally toward the direction of the ipsilateral testicle. The external ring was not opened, therefore the inguinal canal was kept intact. By lifting up the wound using a thyroid retractor, the spermatic cord could be identified by the appearance of the "blue color" of the spermatic veins. After loosening of the spermatic cord by moving it medially and laterally, the cord could be looped and then easily externalized by a Penrose drain without tension. The tissues external to the spermatic cord were examined first for any engorged veins; if present, they were ligated accordingly. The external and intermediate spermatic fascias were opened to expose the internal spermatic veins and fat. The engorged internal spermatic veins were identified and dissected carefully with mosquito clamps. While the vessel was iso-

lated, a loop of 4-0 silk was passed beneath, and then the loop end was divided to make double ties (Fig. 2). The vessel was ligated at both ends, and severed with sharp scissors. Manipulating the mosquito clamps under the target vessel by a gentle up-and-down movement helped to differentiate a vein from an artery or a lymphatic vessel. One could identify the "watershed phenomenon" of pulsation inside an artery (Fig. 3). Lymphatics were characterized by their crystal clear intravascular contents. The compartment of vas deferens was protected and left un-

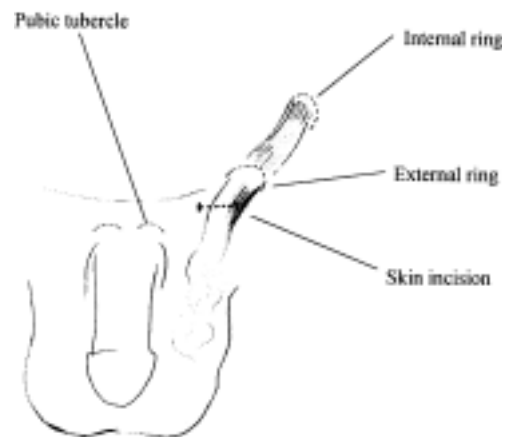


Fig. 1. The skin incision in left subinguinal varicocelectomy.

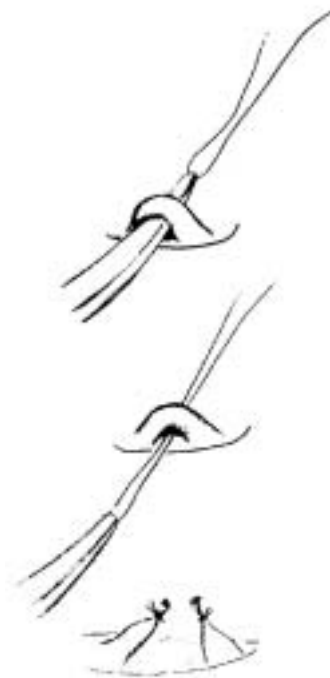
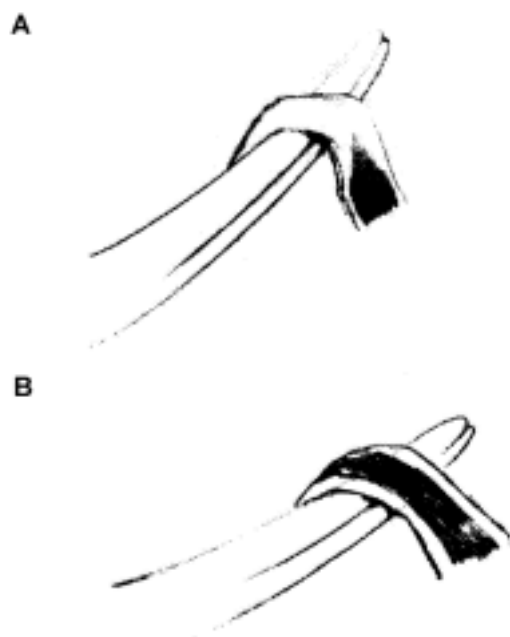


Fig. 2. A loop of 4-zero silk passed beneath the target vessel, and then the loop end divided to make double ties.



**Fig. 3.** The “watershed phenomenon”. (A) Lifting the mosquito clamps from beneath the vessel. (B) Lowering down the mosquito clamps slowly till the pulsation of blood is identified. By maneuvering the movement from A to B, an artery presents the watershed phenomenon.

touched except when abnormally engorged veins were evident. After the procedures performed inside the spermatic cord were completed, the wound was then closed with 4-0 Vicryl materials subcutically. In general, the testicle was not delivered from the wound; therefore, the gubernacular veins were not controlled. In patients with engorged superficial veins in the scrotum, doing vein ligation just inside the spermatic cord seems not adequate. Further delivering of testicle and checking the veins draining at the other direction of the testicle should be done. Fortunately, there was no such case in the present cohort. When the whole procedure was completed, a urethral catheter was inserted to drain the residual urine and then removed. The patients were discharged in the next morning.

For patients with infertility ( $n = 31$ ), we checked semen analysis every 3 months starting after the operation. For patients with painful varicocele ( $n = 31$ ), they were also followed with physical check-up, and optional semen analysis.

The Wilcoxon signed-rank test was used to compare preoperative and postoperative values. The data of semen parameters are presented as mean  $\pm$  standard deviation (SD). A  $p$ -value of  $< 0.05$  was considered significant.

## RESULTS

None of the 58 patients who underwent this procedure reported immediate discomfort. The use of analgesics was limited. The mean age of the painful varicocele group was 28.3 years (range 10-72). The mean age of the infertility group was 34.5 years (range 22-48). The 4 patients having both painful varicocele and infertility were assigned to the infertility group. The average operating times in the painful group and infertility group were similar ( $91.7 \pm 18.6$  vs.  $87.6 \pm 14.5$  minutes). Overall, 4 of 58 patients (7%) had bilateral varicoceles. The rest had left varicocele only. Of the 31 patients with painful varicocele, 3 had bilateral varicoceles. Of the patients with infertility only, 1 had bilateral varicoceles. In the painful group, the varicocele grading was grade 1 in 3 patients, grade 2 in 11 and grade 3 in 20 patients. In the infertility group, the grading was grade 1 in 3 cases, grade 2 in 15 and grade 3 in 6 patients.

Among the infertile patients, 8 were azoospermic, 15 were oligo-asthenospermic and 8 were with asthenospermia only. In the 8 azoospermic patients, the simultaneous testis biopsy revealed Sertoli-cell-only syndrome in 4, maturation arrest in 3 and hyalinization of tubules in 1. They stayed azoospermic in the follow-up period and were not included in the subsequent statistics of semen parameters in this study.

In the painful group, the average follow-up was 6 months (range 2 to 21). There was no intraoperative complication. Twenty-eight of the 31 (90%) patients achieved complete resolution of pain and the other 3 had partial resolution of pain. Postoperative complications included 1 hematoma (3.2%) and 1 residual varicocele (3.2%) that were found 6 months post procedure.

In the infertility group, the average follow-up was 7 months (range 2 to 16). Average infertility duration was 2.5 years (range 0-8). There were no intraoperative or postoperative complications. Only 1 patient (4.3%) had occasional residual throbbing ache. Six patients' wives (32%) got spontaneous pregnancy during the follow-up period. In the oligo-asthenospermic subgroup ( $n = 15$ ), sperm concentrations (mean  $\pm$  SD) increased significantly from  $6.1 \pm 4.3$  to  $24.2 \pm 21.0 \times 10^6/cc$  ( $p < 0.02$ ), and motility from  $36.4 \pm 17.8\%$  to  $45.7 \pm 21.9\%$  ( $p < 0.03$ ) (Table 1). In the asthenospermic subgroup, there was no statistically significant increase of motility.

**Table 1. The change of parameters in semen analysis after subinguinal varicocelectomy**

		Pre-op	Post-op	P <sup>a</sup>
Sperm count ( $\times 10^6$ /c.c.)	For oligoasthenospermia (n = 15)	6.1 $\pm$ 4.3	24.2 $\pm$ 21.0	< 0.02
	For grade 2 (n = 15)	19.3 $\pm$ 14.9	26.4 $\pm$ 20.1	< 0.04
	For grade 3 (n = 13)	33.5 $\pm$ 19.4	38.9 $\pm$ 15.8	< 0.05
Sperm motility (%)	For oligoasthenospermia (n = 15)	36.4 $\pm$ 17.8	45.7 $\pm$ 21.9	< 0.03
	For grade 3 (n = 13)	46.8 $\pm$ 22.6	61.8 $\pm$ 16.8	< 0.02
Sperm morphology (%)	For oligoasthenospermia (n = 15)	56.3 $\pm$ 25.3	57.5 $\pm$ 24.4	> 0.05
	For grade 3 (n = 13)	54.5 $\pm$ 21.2	62.3 $\pm$ 19.4	< 0.03

<sup>a</sup>Wilcoxon signed-rank test.

In patients with grade 1 varicocele, no further statistics were done owing to the available data being too few (n = 6), while for patients with grade 2 varicocele, the sperm count increased from 19.3  $\pm$  14.9 to 26.4  $\pm$  20.1  $\times 10^6$ /cc (n = 17,  $p < 0.04$ ). For patients with grade 3 disease (data available in 13 cases), the sperm count increased from 33.5  $\pm$  19.4 to 38.9  $\pm$  15.8  $\times 10^6$ /cc ( $p < 0.05$ ) (Table 1). In grade 3 patients, the improvement in sperm morphology was from 54.5  $\pm$  21.2% to 62.3  $\pm$  19.4% ( $p < 0.03$ ) and motility from 46.8  $\pm$  22.6% to 61.8  $\pm$  16.8% ( $p < 0.02$ ).

## DISCUSSION

Varicocelectomy has been reported to improve sperm quality in two-thirds of patients and result in a 20-40% increment in the pregnancy rates.<sup>10</sup> However, wide differences in the recurrence rates (from 0 to 45%) have been reported in the literature.<sup>11</sup> Traditionally, varicocelectomy was performed *via* a retroperitoneal or an inguinal approach by most of the urologists in Taiwan. Recently, the subinguinal varicocelectomy, first described by Marmar,<sup>9</sup> has become more popular due to the fact that subinguinal varicocelectomy has lower incidence of morbidity, complication, and residual lesions.<sup>10</sup> In addition, because the procedure is performed without putting tension upon the spermatic cord, it facilitates the work of identifying testicular arteries. However, the difficulty of this procedure is encountering many more tedious small veins. Therefore, the need for more sophisticated microsurgical techniques makes the learning curve steep. In the present cohort, we applied a modification on Marmar's technique by using mosquito's clamps in identifying the artery and lymphatics with or without a mi-

croscopic magnification. Our series, although with short follow-up, confirmed the feasibility of this technique in terms of low morbidity and good patient comfort. The recurrence rate and percentage of residual lesions were both low.

The incidence of hydrocele by the inguinal and retroperitoneal approaches was 7.2%.<sup>13</sup> The cause of hydrocele was due to lymphatic obstruction. However, there has been no hydrocele formation till now in our patients. The low rate of hydrocele formation may be because of our aggressive efforts in preserving the lymphatics. This result was also confirmed by other reports on subinguinal microsurgical varicocele repairs.<sup>12,14</sup>

For the infertility group, significant improvement in the sperm quality was found in patients with oligoasthenospermia or with a grade 3 varicocele. This finding is in accordance with a previous report.<sup>15</sup>

The pregnancy rates in our series (32%) was comparable to those in other reports in spite of a shorter follow-up.<sup>14</sup>

For our 8 patients with azoospermia, the results of operation were disappointing. The simultaneous testis biopsy for these patients revealed Sertoli-cell-only syndrome in 4, maturation arrest in 3, and tubular hyalinization in 1. Reports from Kim *et al.* showed an improvement of semen parameter in 43% in their azoospermic group,<sup>16</sup> however, the patients with improvement in their report were only those who had either hypospermatogenesis or late maturation arrest. No improvement in semen was found in their patients with Sertoli-cell-only syndrome or tubular hyalinization up to 24 months of follow-up.

In conclusion, the modified technique of subinguinal varicocelectomy provides an effective treatment and low morbidity for painful varicocele and varicocele-associated infertility in spite of a short follow-up period.

**REFERENCES**

1. Cockett AT, Takihara H, Cosentino MJ. The varicocele. *Fertil Steril* 1984;41:5-11.
2. Walsh PC, Retik AB, Vaughan ED Jr, Wein AJ, eds. *Campbell's Urology*. 8<sup>th</sup> ed., Philadelphia: W.B. Saunders, 2002; 1487.
3. Howards SS. Varicocele. *Infertil Reprod Med Clin N Am* 1992;3:429-33.
4. Peterson AC, Lance RS, Ruiz HE. Outcomes of varicocele ligation done for pain. *J Urol* 1998;159:1565-7.
5. Schlegel PN, Glodstein M. Anatomical approach to varicocelectomy. *Semin Urol* 1992;10:242-7.
6. Tulloch WS. Varicocele in subinfertility: results of treatment. *Br Med J* 1955;4935:356-8.
7. Palomo A. Radical cure of varicocele by a new technique: preliminary report. *J Urol* 1949;61:604-7.
8. Ivanissevich O. Left varicocele due to reflux: experience with 4,470 operative cases in 42 years. *J Int Coll Surg* 1960;34: 742-55.
9. Marmar JL, Debenedictis TJ, Prasis D. The management of varicoceles by microdissection of the spermatic cord at the external ring. *Fertil Steril* 1985;43:583-5.
10. Madgar I, Weiessenberg R, Lunenfeld B, Karasik A, Goldwasser B. Controlled trial of high spermatic vein ligation for varicocele infertile men. *Fertil Steril* 1995;63:120-4.
11. Yavetz H, Levy R, Papo J, Yogev L, Paz G, Jaffa AJ, *et al.* Efficacy of varicocele embolization versus ligation of the left internal spermatic vein for improvement of sperm quality. *Int J Androl* 1992;15:338-44.
12. Huang SS, Wu CF, Chen CS. Subinguinal microsurgical varicocelectomy under a diagnosis of color flow mapping: a delicate and effective procedure for varicocele. *J Urol ROC* 2001;12:91-5.
13. Szabo R, Kessler R. Hydrocele following internal spermatic vein ligation: a retrospective study and review of the literature. *J Urol* 1984;132:924-5.
14. Marmar JL, Kim Y. Subinguinal microsurgical varicocelectomy: a technical critique and statistical analysis of semen and pregnancy data. *J Urol* 1994;152:1127-32.
15. Steckel J, Dicker AP, Goldstein M. Relationship between varicocele size and response to varicocelectomy. *J Urol* 1993; 149:769-71.
16. Kim ED, Leiman BB, Grinblat DM, Lipshultz LI. Varicocele repair improves semen parameters in azoospermic men with spermatogenic failure. *J Urol* 1999;162:737-40.