

## Significance of Pulmonary Venous Obstruction in Total Anomalous Pulmonary Venous Return

Ping-Yao Wang<sup>1,4</sup>  
Be-Tau Hwang<sup>1,5</sup>  
Jen-Her Lu<sup>1</sup>  
Pi-Chung Lee<sup>1</sup>  
Chui-Mei Tiu<sup>2</sup>  
Zeng-Chung Weng<sup>3</sup>  
Luara C.C. Meng<sup>1</sup>

<sup>1</sup> Division of Pediatric Cardiology,

<sup>2</sup> Department of Radiology, and

<sup>3</sup> Division of Cardiovascular Surgery,  
Taipei Veterans General Hospital;

<sup>4</sup> I-Lan Hospital, Department of Health;

<sup>5</sup> National Yang-Ming University School of  
Medicine, Taipei, Taiwan, R.O.C.

### Key Words

angiography;  
echocardiography;  
magnetic resonance imaging;  
total anomalous pulmonary venous return

**Background.** Total anomalous pulmonary venous return (TAPVR) is an uncommon congenital cardiovascular anomaly with poor natural prognosis. It has been detected more frequently in recent year due to the advent of echocardiography and cardiovascular magnetic resonance imaging (MRI). The aim of this study was to evaluate the clinical manifestations and outcomes in TAPVR patients with or without pulmonary venous obstruction (PVO).

**Methods.** From January 1985 to December 2002, a total of 27 cases with TAPVR at our institution were reviewed. According to the presence or absence of PVO, patients were divided into PVO group and non-PVO group. Patients' sex, age at diagnosis, types of TAPVR, clinical manifestations, surgical treatment and outcomes were evaluated.

**Results.** All of them had received 2-dimensional (2-D) and color Doppler echocardiography examination. Cardiac catheterization was performed in all but 1 patient who died at the first day of birth. In addition, 10 of 27 cases had cardiovascular MRI for further study. The number of cases in PVO group and non-PVO group were 15 (56%) and 12 (44%), respectively. There was no significant difference in sex or pulmonary venous drainage sites between both groups. Cyanosis was more prevalent in the PVO group (80% vs. 30%,  $p = 0.038$ ). Four (27%) cases PVO group and 3 (25%) cases of the non-PVO group had of the non-isolated cardiac lesions. Pulmonary hypertension was present in 18 (69%) of 26 cases who had received cardiac catheterization. Among them, 10 had PVO and 5 had systemic level of pulmonary arterial pressure. Seven (30%) of 23 patients who had received operation died; in contrast, 3 of 4 patients without operation expired. The remaining 1 did not had surgery because of complex heart disease. There was no significant difference in surgical mortality between PVO and non-PVO groups (33% vs. 27%).

**Conclusions.** Cyanosis is an obvious clinical symptom of obstructed TAPVR. Surgical mortality made no significant difference between obstructed and non-obstructed groups. Early detection and surgical treatment for TAPVR are important. Although cardiac catheterization and angiography is the golden standard for the diagnosis, 2-D and color Doppler echocardiography can also provide quick and accurate diagnostic images of TAPVR.

Total anomalous pulmonary venous return (TAPVR) represents a rare form of congenital cardiac defects since introduced first by Wilson in 1798.<sup>1</sup> As the advent of 2-dimensional (2-D), color Doppler echocardiography,<sup>2</sup> angiography,<sup>3</sup> and magnetic resonance imaging (MRI),<sup>4</sup> TAPVR can be early detected. The clinical symptoms and signs in TAPVR are variable. TAPVR patients with

pulmonary venous obstruction (PVO) usually present with cyanosis and dyspnea even sudden death in the first 2 months,<sup>5</sup> and patients without PVO tend to present in heart failure later. Without proper surgery or treatment, the prognosis of these patients is grim in the first year of life.<sup>6</sup> Early detection and prompt management are very important. In this study, we presented the clinical mani-

Received: December 3, 2003.

Accepted: May 7, 2004.

Correspondence to: Be-Tau Hwang, MD, Department of Pediatrics, Taipei Veterans General Hospital, 201, Sec. 2, Shih-Pai Road, Taipei 112, Taiwan.

Tel: +886-2-2875-7576 ext. 102; Fax: +886-2-2873-9019

festations, the findings of echocardiography, cardiac catheterization and MRI, and the outcomes of our TAPVR patients with or without PVO.

## METHODS

From January 1985 through December 2002, a total of 27 TAPVR patients were diagnosed at Taipei Veterans General Hospital. We analysed these patients' sex, age at diagnosis, types of TAPVR, clinical manifestations, surgical treatment and outcomes. A comparison was also made between patients with PVO (PVO group) and without PVO (non-PVO group).

According to the different drainage sites of the anomalous pulmonary veins to the heart, TAPVR is classified into 4 types: supracardiac type (anomalous pulmonary vein draining into upper part of heart), intracardiac type (anomalous pulmonary vein draining into middle part of heart), infracardiac type (anomalous pulmonary vein draining below the heart), and mixed type (which has two or more drainage sites).

Patients with any 1 of the following criteria were considered having PVO: more than 50% reduction in the diameter of anomalous pulmonary vein in angiography or MRI films; (2) pressure gradient greater than 10 mmHg across the narrowing site; (3) high blood flow velocity detected within the pulmonary venous turbulent exceeding 1.5 m/sec by Doppler technique. Pulmonary hypertension is defined as a mean pulmonary artery pressure (PAP) greater than 25 mmHg at rest. Statistical analysis was performed by using the Chi-square test for the categorical variables. Difference was defined to be significant in all comparisons if  $p < 0.05$  at the significant level of 95 percent confidence interval and of power of 90 percents.

## RESULTS

There were 14 boys and 13 girls; the age at diagnosis ranged from 1 day to 10 years with the median age of 2.3 months. Among them, 15 (56%) patients had PVO and the other 12 (44%) did not have PVO.

Twenty-six patients received cardiac catheterization and the other 1 who died at the age of 1 day had only

echocardiographic diagnosis. Twenty-three of them had surgical treatment. Three of 4 patients who did not receive operation died and the other 1 had complex heart disease with single ventricle and pulmonary stenosis. Total correction was not attempted.

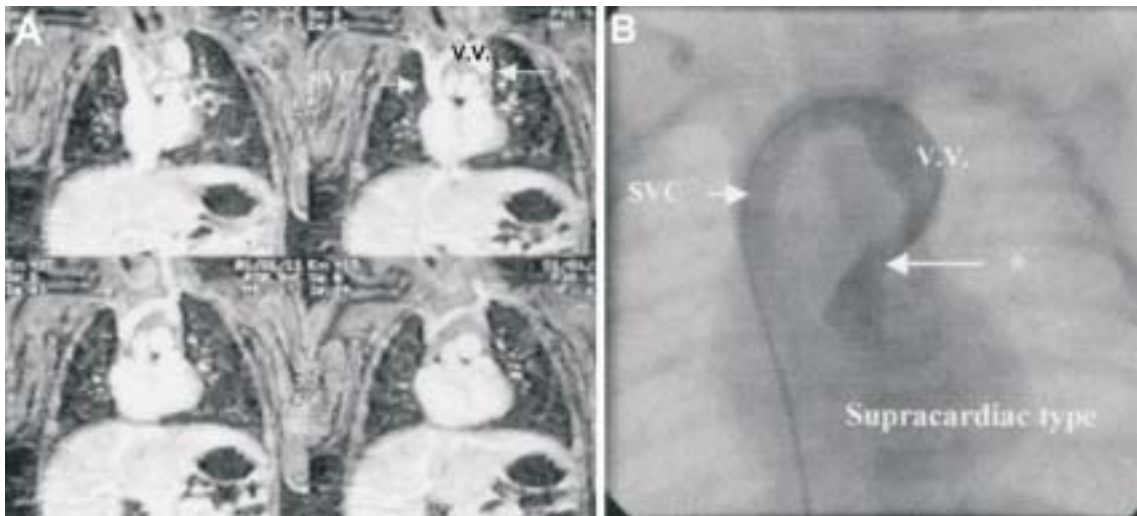
As shown in Table 1, the cyanotic features between the PVO and non-PVO groups were statistically different ( $p = 0.038$ ). TAPVR may be associated with various cardiac defects and heterotaxy. Seven (26%) cases had associated cardiovascular lesions, which included transposition great arteries with pulmonary atresia or pulmonary stenosis in 4, common atrioventricular canal type single ventricle in 2, and hypoplastic left heart syndrome with coarctation of the aorta in 1. In this study, 4 cases (27%) with PVO and 3 cases (25%) without PVO had non-isolated TAPVR had no statistical difference. Meanwhile, the heterotaxy syndrome presented equally in obstructed and non-obstructed groups ( $p = 0.747$ ).

All the patients of the infracardiac and mixed type

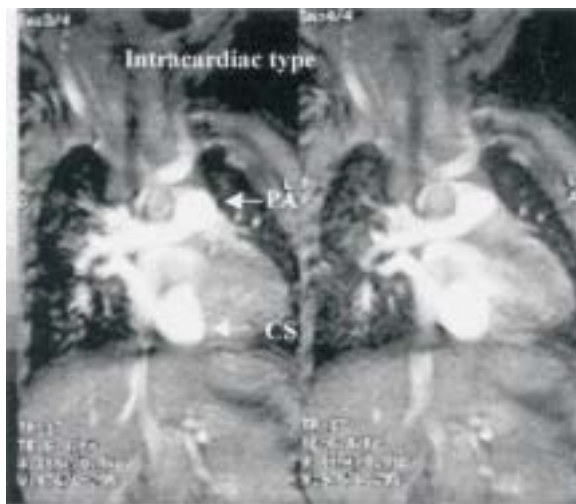
**Table 1. General characteristics and clinical manifestations in TAPVR patients with and without PVO**

Parameters	PVO group (n = 15)	Non-PVO group (n = 12)	p value
Age at diagnosis (month)	3.0 <sup>a</sup>	2.2	NS
Sex (M/F)	8/7	6/6	NS
Cyanosis	12 (80) <sup>b</sup>	4 (33)	0.038
Tachypnea	15 (100)	11 (92)	NS
Difficult to feeding	9 (60)	5 (42)	NS
Frequent respiratory infection	2 (13)	2 (17)	NS
Failure to thrive	4 (27)	5 (42)	NS
Non-isolated TAPVR	4 (27) <sup>c</sup>	3 (25) <sup>d</sup>	NS
Drainage sites			NS
Supracardiac	9 (60)	6 (50)	
Cardiac	3 (20)	6 (50)	
Infracardiac	2 (13)	0	
Mixed	1 (7)	0	
Pulmonary hypertension	10/14 (71) <sup>e</sup>	8 (67) <sup>f</sup>	NS
Surgical treatment	12 (80)	11 (92)	NS
Mortality	7 (47)	4 (33)	NS

<sup>a</sup>The median age of month; <sup>b</sup>number in the parentheses represents percentage; <sup>c</sup>2 had heterotaxy; <sup>d</sup>2 had heterotaxy; <sup>e</sup>1 patient with PVO did not receive cardiac catheterization, 3 of the 10 patients with pulmonary hypertension had PAP/SAP  $\geq 1$ ; <sup>f</sup>2 had PAP/SAP  $\geq 1$ . TAPVR = total anomalous pulmonary venous return; PVO = pulmonary veinous obstruction; PAP = pulmonary artery pressure; SAP = systemic artery pressure.



**Fig. 1.** (A) Sequential coronal sections of magnetic resonance imaging of a 1-month-old boy with supracardiac total anomalous pulmonary venous return. Confluence of pulmonary veins was noted to form a common vertical vein (V.V.) with segmental stenosis (\*), which ascended upward then turned to right side and drain to superior vena cava. (B) Compatible picture of cardioangiography.



**Fig. 2.** Two sequential coronal sections of magnetic resonance imaging in a 2-month-old girl with intracardiac total anomalous pulmonary venous return. The pulmonary veins drained into the coronary sinus (CS) and into the right atrium. Dilatation of the main pulmonary artery (PA) was also noted.

patients had PVO there was no significant difference in drainage sites between both groups ( $p = 0.583$  and  $p = 0.947$ , respectively).

Among 26 patients who received cardiac catheterization, 18 had pulmonary hypertension. Ten of 14 (71%) cases in PVO group and 8 (67%) in non-PVO group had mild to severe pulmonary hypertension, but

they showed no significant difference in pressure. Only 3 patients of the PVO group had systemic or suprasystemic level of pulmonary hypertension.

Of the 23 patients who had received operation, 7 cases (30%) expired (all  $\leq 1$  y/o). Three of the other 4 patients without surgical correction died. There was no significant difference in surgical mortality between PVO and non-PVO groups.

Ten of 27 cases had MRI examination due to some imaging limitations of echocardiography or angiography in assessing pulmonary vein and pulmonary venous confluence. Among them, 6 were of supracardiac type, 3 were of intracardiac type and the other 1 was of mixed type. We found that MRI is compatible with cardioangiography and echocardiography for diagnosis of TAPVR (Figs. 1 and 2).

## DISCUSSION

The symptoms and signs of TAPVR are variable, usually depending on the pathological anatomy and the changes of hemodynamics. Tachypnea, difficult feeding and cyanosis are usually the initial symptoms.<sup>7</sup> Repeated respiratory tract infection, and failure to thrive are also present. More than 92% of our TAPVR patients had tachypnea initially, but less than 17% of them had frequent respiratory tract infection. It may be due to the in-

creasing alertness of caregivers and early detection of this problem with the facility of echocardiography. Cyanosis is a significant clinical manifestation and is more common in PVO group.

TAPVR is either an isolated defect with small atrial septal defect or patent ductus arteriosus or is a non-isolated disorder which is associated with various complex cardiac abnormalities, such as common atrioventricular canal, pulmonary stenosis or atresia, mitral atresia, conotruncal anomalies, systemic venous anomalies or heterotaxy syndrome. In the report of Delisle *et al.*,<sup>8</sup> the non-isolated form accounts for about 38% of cases, and 37% in patients with PVO. In contrast, 7 (26%) of our cases had non-isolated TAPVR and 4 (57%) of them had PVO. But it seems not to be significantly different between heterotaxy syndrome combined with pulmonary venous obstruction,<sup>8</sup> which is compatible to our study results.

Although elevated PAP may be present in patients with PVO, and intracardiac shunt should be more right to left direction to induce more cyanosis, many reports failed to demonstrate that relationship. Gathman and Nadas<sup>7</sup> had reviewed 75 pediatric patients with TAPVR, and found that only three-fourth patients with markedly elevated pulmonary artery pressure had anatomic PVO. Their findings were also confirmed by Delisle *et al.*,<sup>8</sup> but given with no clear explanation.

In sense of the drainage sites, the PVO occurs most often with the infracardiac type and less often in the intracardiac type of TAPVR.<sup>6,8</sup> But our findings showed no significant difference between the PVO and non-PVO groups. The small number of cases might count.

As the advent of echocardiography, TAPVR can be readily diagnosed without much difficulty. The sensitivity and specificity for diagnosis by echocardiography including cross-sectional and color Doppler flow mapping have been reported to be up to 97% and 99%, respectively.<sup>9-12</sup> Diagnostic cardiac catheterization is currently not so desirable due to its invasive nature and time-spore technique as well as the unstable condition of patients in procedure. It has been reserved for the patients who have coexisting complex heart lesions or mixed connection of pulmonary veins. In order to have detailed hemodynamics and clear anatomy, all our cases had received cardiac catheterization except 1 died.

Otherwise, there were more and more performance of EKG-gated MRI for cardiovascular survey because of the advantages in obtaining non-invasive, detailed images and non-irradiation nature.<sup>13,14</sup> MRI may achieve a detection rate of 98% in identifying anomalous pulmonary venous channels,<sup>4</sup> but the costs of study and the risk of sedation must be taken into consideration. We had demonstrated 10 cases with non-contrast enhanced MRI examination with spin echo and fast gradient echo pulse sequences and contrast-enhanced 3D MRA for the great vessels and heart. The results were acceptable and comparable with the cardioangiography. It can help us to further evaluate the TAPVR with complex heart disease that the echocardiography is sometimes difficult to detect. In our study, angiocardiology is the golden standard for diagnosis of TAPVR. The 2-D and color Doppler echocardiography is noninvasive, safe and portable, and may be considered as the first choice for diagnosis. Additionally, cardiac MRI can be supplementary if echocardiography and angiography are inadequate.

The natural course of TAPVR is unfavorable because of progressing pulmonary artery hypertension and heart failure. Open heart repair is necessary in most of the cases to resolve lethal anomaly. The estimated first-year survival rate in patients with no treatment was only 25%; 50% death occurred before 3 months of age, and 80% death occurred before 1 year of age.<sup>15</sup> However, the operation mortality in patients under 1-year of age decreased significant from 50% in 1970s to 30% after 1970s.<sup>16,17</sup> In our study, mortality rate was high (75%) in patients without surgery, and was 30% in those with surgery before 1 year old. There was no statistical difference in surgical mortality between PVO, in spite that some reports indicated a higher operative mortality in TAPVR patients with PVO.<sup>18,19</sup>

## REFERENCES

1. Mitchell SC, Korones SB, Berendes HW. Congenital heart disease in 56,109 births: incidence and natural history. *Circulation* 1971;43:323-32.
2. Smallhorn JF, Sutherland GR, Tommasini G, Hunter S, Anderson RH, Macartney FJ. Assessment of total anomalous pulmonary venous connection by two-dimensional echocardiography. *Br Heart J* 1981;46:613.

3. Chen YC, Hsieh KS, Chi CS. Total anomalous pulmonary venous return: a clinical observation of 36 cases. *J Chin Med Assoc* 1994;54:44-50.
4. Chang YC, Li YW, Liu HM, Wang TC. Finding of anomalous pulmonary venous return using MRI. *J Formos Med Assoc* 1994;93:462-8.
5. Byard RW, Moore L. Total anomalous pulmonary venous drainage and sudden death in infancy. *Forensic Science International* 1991;51:197-202.
6. Lucas RV Jr, Adams P Jr, Anderson RC. Total anomalous pulmonary venous connection to the portal venous system: a case of pulmonary venous obstruction. *Am J Roentgenol* 1961;86:561-75.
7. Gathman GE, Nadas AS. Total anomalous pulmonary venous connection: clinical and physiologic observations of 75 pediatric patients. *Circulation* 1970;42:143-54.
8. Delisle G, Ando M, Calder AL, Zuberbuhler JR, Rothenmayer S, Alday LE, et al. Total anomalous pulmonary venous connection: report of 93 autopsied cases with emphasis on diagnostic and surgical consideration. *Am Heart J* 1976;91:99-122.
9. Huhta JC, Gutgesell HP, Nihill MR. Cross section echocardiographic diagnosis of total anomalous pulmonary venous connection. *Br Heart J* 1985;53:525-34.
10. Wang JK, Lue HC, Wu MH, Young ML, Wu FF, Wu JM. Obstructed total anomalous pulmonary venous connection. *Pediatr Cardiol* 1993;14:28-32.
11. Vitarelli A, Scapato A, Sangnigni V, Caminiti MC. Evaluation of total pulmonary drainage with cross sectional colour-flow Doppler echocardiography. *Eur Heart J* 1986;7:190-5.
12. Stark J, Smallhorn J, Huhta J, de Leval M, Macartney FJ, Rees PG, Taylor JF. Surgery for congenital heart defects diagnosed with cross-sectional echocardiography. *Circulation* 1983;68(suppl):129-38.
13. Masui T, Seelos KC, Kersting-Sommerhoff BA, Higgins CB. Abnormalities of pulmonary veins: evaluation with MR imaging and comparison with cardiac angiography and echocardiography. *Radiology* 1991;181:645-9.
14. Hsu YH, Chien CT, Hwang M, Chiu IS. Magnetic resonance imaging of total pulmonary venous drainage. *Am Heart J* 1991;121:1560-5.
15. Keith JD, Rowe RD, Vlad P. Complete anomalous pulmonary venous drainage. *Am J Med* 1954;16:23-38.
16. Bonchek LI, Anderson RP, Wood JA, Chapman RD, Starr A. Intracardiac surgery with extracorporeal circulation in infants. *Ann Thorac Surg* 1974;17:280-95.
17. Whight CM, Barratt-Boyes BG, Calder AL, Neutze JM, Brandt PW. Total anomalous pulmonary venous connection. Long-term results following repair in infancy. *J Thorac Cardiovasc Surg* 1978;75:52-63.
18. Galloway AC, Campbell DN, Clarke DR. The value of early repair for total pulmonary venous drainage. *Pediatr Cardiol* 1985;6:77-82.
19. Lincoln CR, Rigby ML, Mercani CM, Al-Fagih M, Joseph MC, Miller GA. Surgical risk factors in total anomalous pulmonary venous drainage. *Am J Cardiol* 1988;61:608-11.