

Intrapelvic Migration of a Kirschner Wire

Yi-Chin Fong, Wu-Chou Lin¹, Horng-Chaung Hsu*

Department of Orthopedics and ¹Department of Gynecology and Obstetrics, China Medical University Hospital, Taichung, Taiwan, R.O.C.

Intrapelvic migration of a Kirschner wire, used in the treatment of hip fracture, is rare. We report a case of intrapelvic migration of a Kirschner wire 10 years after its placement. Even though the patient was asymptomatic, we proceeded to remove the migrated wire using laparoscopic techniques. Given the increasing number of hip operations being performed, and given that intrapelvic foreign bodies can result in serious or fatal complications, it is important to keep this problem in mind in patients who have had previous hip surgery. [*J Chin Med Assoc* 2005;68(2):96–98]

Key Words: complication, hip fracture, intrapelvic migration, Kirschner wire, laparoscopy

Introduction

Intrapelvic migration of a Kirschner wire is rare. There are several reports of postoperative pin migration from the shoulder girdle region (proximal humerus, clavicle, acromioclavicular joint, shoulder joint, and sternoclavicular joint) to various intrathoracic sites including the heart, subclavian artery, ascending aorta, pulmonary artery, subarachnoid space, spinal cord, mediastinum, trachea, abdomen, orbit, and lung.^{1–3} These migrations can result in devastating complications and be associated with catastrophic cardiovascular events. Migration from the lower extremity and regions other than the shoulder has been rarely reported. We report a patient with intrapelvic migration of a Kirschner wire 10 years after fixation for a left hip fracture. Although the patient was asymptomatic, intrapelvic foreign bodies can potentially be serious or fatal.

Case Report

A 65-year-old woman was admitted because an intrapelvic foreign body was noted incidentally on a pelvic X-ray. The patient had undergone open reduction and internal fixation for a left hip fracture 10 years earlier. She was otherwise healthy, but had limited motion of her left hip joint after the surgery. A few weeks before

presentation, the patient had been treated for cellulitis of her left leg. During this evaluation, a pelvic X-ray was performed, which disclosed the foreign body. The patient was then referred to our hospital for further evaluation. She denied gastrointestinal or urinary symptoms. She had normal bowel sounds and no abdominal tenderness, guarding, or rebound pain. She did not have any lower extremity edema, rubor, cyanosis, or pulse deficits. Left hip range of motion was from 70 degrees of flexion to 10 degrees of extension. Further imaging techniques, including a plain hip X-ray, bowel contrast study, computed axial-tomographic scan of the pelvis (Figure 1), and cystoscopy, revealed a migrated Kirschner wire in the pelvic cavity, anterior to the rectum and inferior to the peritoneal reflection. Another Kirschner wire pin and screw remained in place in the acetabulum.

We decided to extract the migrated Kirschner wire. The patient underwent surgery using general anesthesia, and was placed in the semi-Trendelenburg position. For a primary portal entry site, we made a 10 mm midline infra-umbilical incision and maintained pneumoperitoneum with carbon dioxide insufflation via a spring-loaded Veress needle. Throughout the procedure, we maintained continuous flow control and pressure monitoring. Next, we placed an examining 10 mm trocar, through which we placed a 10 mm laparoscope. We also placed a 5 mm trocar in a midline

*Correspondence to: Dr. Horng-Chaung Hsu, Department of Orthopedics, China Medical University Hospital, 2, Yun-Der Road, Taichung 404, Taiwan, R.O.C.
E-mail: d4749@www.cmuh.org.tw • Received: August 11, 2003 • Accepted: August 30, 2004

suprapubic position, through which we introduced a blunt manipulator. We proceeded to systematically examine the pelvis and identified the Kirschner wire in the cul-de-sac. After this, we placed another 5 mm trocar in the right lower quadrant, through which we inserted laparoscopic grasping forceps. With the grasping forceps, we removed the Kirschner wire, but were unable to remove the other protruding Kirschner wire because it was fixed in the acetabulum. However, using mini-laparotomy, we cut the protruding end. The patient recovered uneventfully and was doing well on postoperative follow-up.

Discussion

Smooth Kirschner wires and pins are the simplest and most effective tools in the management of fractures and dislocations. Of significant concern is the potential for these devices to migrate to distant anatomical sites. Several recommendations have been made to prevent this potential complication.^{2,3} First, these devices should be used only as a temporary fixation. After fixation of the fracture fragment by plate, screw or staple, the smooth Kirschner wires must be removed. Second, if other fixation devices cannot fix the fracture fragment, the end of the Kirschner wire should be bent, or restraining devices used. Third, pre- and postoperatively, physicians must carefully instruct patients about the importance of returning for follow-up evaluation and the removal of Kirschner wires. Fourth, patients must be warned to restrict activity and joint motion postoperatively, and carefully confirm the position of implants with serial biplane radiographs. Fifth, if follow-up radiographs show any migration of Kirschner wire, the wire should be removed immediately.

Although our patient was asymptomatic, we regarded removal of the migrated Kirschner wire as a matter of urgency, because drastic and rapid positional change has been reported to occur within a few hours.^{4,5} Laparoscopic retrieval of an intrapelvic migrating Kirschner wire has seldom been described in the literature,⁶ and we offer it as a less invasive alternative to conventional laparotomy.

There are various reports in the literature of complications due to intra- or postoperative intrapelvic migration of devices used in the internal fixation of hip fractures. These reports include migration of the following: a Knowles pin through the external iliac vein;⁷ a broken pin into the urinary bladder;⁸ a threaded Steinmann pin, with vascular injury;^{5,9} and a protruding screw from a sliding screw-plate device.^{10,11} Other reports include perforation of the rectum by a Smith-

Peterson nail,¹² and intraoperative guide-wire protrusion and breakage.¹³ Proximal-to-distal migration in the thigh or around the knee joint has also been reported, including migration of a compression screw¹⁴ and Knowles pin.^{15,16}

The mechanism of postoperative implant migration remains obscure. Various theories have been proposed, including muscular activity, respiratory excursion,

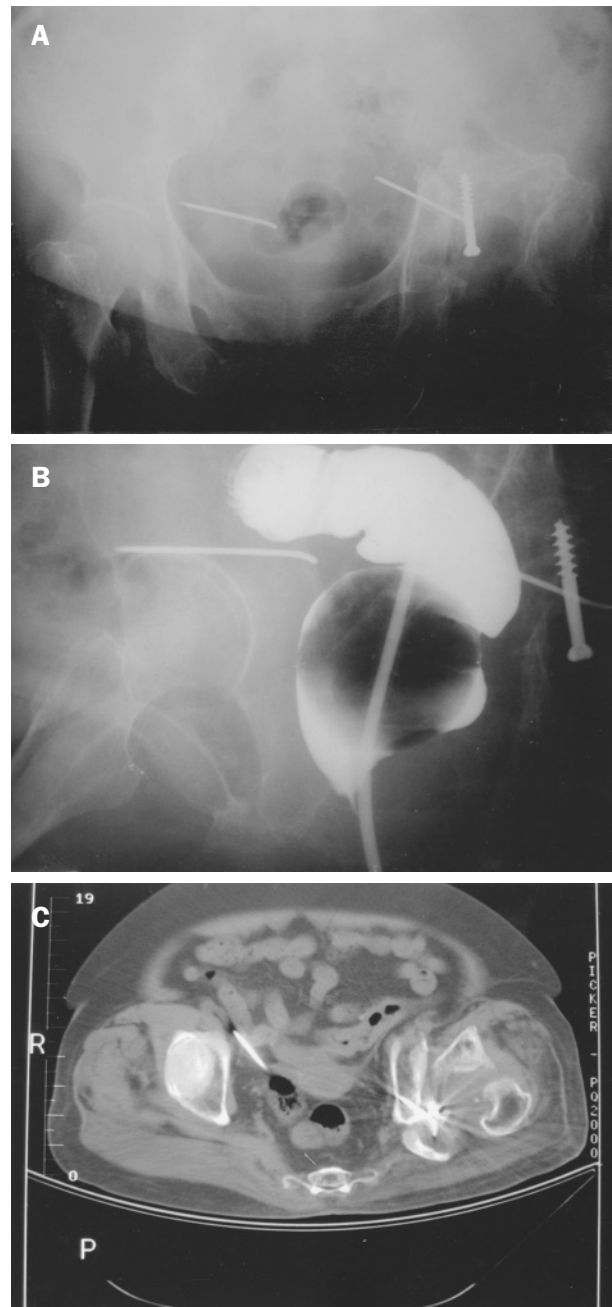


Figure 1. Anterior-posterior radiograph of the pelvis (A), bowel contrast studies (B), and a computed axial-tomographic scan (C), showing the location of the Kirschner wire without associated gastrointestinal or urinary injury.

capillary action, electrolysis, local bone resorption secondary to prolonged implantation, gravitational forces, the great freedom of motion of an extremity, chronic osteomyelitis, and fracture nonunion.^{2,7,17}

Migrated orthopedic fixation devices require urgent surgery, given their potential for disastrous consequences. As Mazet stated, "There are no rules governing the behavior of foreign bodies in the tissues".¹⁸ Longitudinal follow-up of patients with these devices, and documentation of experience in removing migrated devices, should continue. Given the increasing number of hip operations being performed, and given that intrapelvic migration of implants can result in serious or fatal complications, it is important to keep this problem in mind in patients who have had previous hip surgery.

References

1. Wirth MA, Rockwood CA Jr. Complications of treatment of injuries to the shoulder. In: Epps CH Jr (ed). *Complications in Orthopedic Surgery*, 3rd edition, Volume 1. Philadelphia: Lippincott, 1994:229–55.
2. Lyons FA, Rockwood CA Jr. Migration of pins used in operations on the shoulder. *J Bone Joint Surg Am* 1990;72:1262–7.
3. Lindsey RW, Gutowski WT. The migration of a broken pin following fixation of the acromioclavicular joint: a case report and review of the literature. *Orthopedics* 1986;9:413–6.
4. Retief PJ, Meintjes FA. Migration of a kirschner wire in the body: a case report. *S Afr Med J* 1978;53:557–8.
5. Posman CL, Morawa LG. Vascular injury from intrapelvic migration of a threaded pin: a case report. *J Bone Joint Surg Am* 1985;67:804–6.
6. Kottmeier S, Born CT, Saul H. Laparoscopic retrieval of a migrating intrapelvic pin: case report and review of the literature. *J Trauma* 1993;35:952–5.
7. Buch RG, Kernek CB, Madura JA, Province WD 2nd. Intrapelvic migration of Knowles pin through external iliac vein. *Orthopedics* 1985;8:1023–4.
8. Alpers DD. Migration of broken hip pin into urinary bladder. *JAMA* 1970;212:2123–4.
9. Mattson JT, Louis DS. Intrapelvic migration of a threaded Steinmann pin in Parkinson's disease. *Clin Orthop* 1976;121:166–8.
10. Brodell JD, Leve AR. Disengagement and intrapelvic protrusion of the screw from a sliding screw-plate device: a case report. *J Bone Joint Surg Am* 1983;65:697–701.
11. Rao SB, Pringle RG. Intrapelvic penetration of a sliding screw: a rare complication. *Injury* 1992;23:56–7.
12. Seitz WH Jr, Berardis JM, Giannaris T, Schreiber G. Perforation of the rectum by a Smith-Petersen nail. *J Trauma* 1982;22:339–40.
13. Mishra P, Jain P, Aggarwal A, Upadhyay A, Maini L, Gautam VK. Intrapelvic protrusion of guide wire during fixation of fracture neck of femur. *Injury* 2002;33:839–41.
14. Hudson I, Jones JR. Compression screw migration with the sliding hip screw. *J R Soc Med* 1992;85:422–3.
15. Stanford RE, Kohan L. Migration of a Knowle's pin from the neck of the femur to the knee joint. *Orthopedics* 2000;23:281–2.
16. Adolphson P. Intrapelvic penetration of Olmed cervical hip fracture screws: a report of 7 cases. *Acta Orthop Scand* 1995;66:249–51.
17. Glauser F, Kremens V. Unusual sequelae following pinning of medical clavicular fracture. *Am J Roentgenol Radium Ther Nucl Med* 1956;76:1066–9.
18. Mazet R. Migration of a Kirschner wire from the shoulder region into the lung: report of two cases. *J Bone Joint Surg* 1943;25:477.