

Orbital Metastatic Osteosarcoma

Pei-Yu Lin^{1,5}, Wei-Ming Chen^{2,5*}, Yuh-Lin Hsieh^{3,5}, Winby York-Kwan Chen^{4,5}, Tain-Hsiung Chen^{2,5}
 Departments of ¹Ophthalmology, ²Orthopedics and Traumatology, ³Pediatrics, and ⁴Pathology, Taipei Veterans General Hospital; and ⁵National Yang-Ming University School of Medicine, Taipei, Taiwan, R.O.C.

A 15-year-old girl with right tibial osteosarcoma, diagnosed 22 months previously, developed right orbital and skull base metastases, with symptoms including painful protrusion of the right eyeball and severe visual impairment. She underwent embolization of the metastatic tumor, local irradiation, and chemotherapy followed by intralesional resection of the mass because extensive involvement of the skull base precluded complete surgical resection. The best corrected visual acuity in her right eye initially decreased to 20/200, then dropped to no light perception after embolization, and then improved to counting fingers at 50 cm after radiotherapy. The symptoms of pain and proptosis subsided completely. After 24 months of follow-up from the presentation of orbital metastasis, the patient's right-eye vision remained unchanged. The surgical specimen revealed a necrotic tumor similar to osteosarcoma. In conclusion, orbital metastasis of osteosarcoma is rare, but may lead to severe visual impairment. Combined radiotherapy, chemotherapy and surgery can partially relieve symptoms, but cannot completely eradicate the tumors. [J Chin Med Assoc 2005;68(6):286–289]

Key Words: chemotherapy, metastasis, orbit, osteosarcoma, radiotherapy

Introduction

Osteosarcoma, the most common primary malignant tumor of bone in children and young adults, occurs primarily in the long bones and typically metastasizes to the lungs.¹ However, non-pulmonary metastases are being seen more often because of prolonged longevity in osteosarcoma patients given modern treatments.² Tumor metastases to the orbit are found mostly in adult carcinomas, and in children, in embryonal tumors or sarcomas (most frequently neuroblastoma, whereas Ewing's sarcoma and Wilms' tumor are less common).³ A MEDLINE review of the literature revealed only 2 cases of osteosarcoma with metastasis to the orbit.^{4,5} One patient with a primary tumor in his right tibia developed protrusion of the right eye 1 month after amputation of his leg. His vision was normal. Further treatment was refused, and the patient was discharged from hospital.⁴ The other patient, who had primary pelvic telangiectatic osteosarcoma and skull metastasis at diagnosis,

developed right and then left orbital metastases 3 years later; his vision was unaffected, but he had a constricted visual field, and he died from the disease despite radiotherapy.⁵ We report the third case of orbital metastatic osteosarcoma, in which the patient's vision deteriorated rapidly. The clinical course and response to treatment are described.

Case Report

A 15-year-old girl was referred to our hospital because of progressive protrusion of her right eyeball since October 2001. She had a history of osteosarcoma (osteoblastic type) of the right proximal tibia; the condition was first diagnosed in December 1999. A systematic work-up revealed no sign of distant metastasis (stage IIB, according to the Musculoskeletal Tumor Society staging system). Neoadjuvant chemotherapy with ifosfamide, epirubicin, methotrexate and cisplatin was administered, and surgery with wide excision, plus

*Correspondence to: Dr. Wei-Ming Chen, Department of Orthopedics and Traumatology, Taipei Veterans General Hospital, 201, Section 2, Shih-Pai Road, Taipei 112, Taiwan, R.O.C.
 E-mail: wmchen@vghtpe.gov.tw • Received: February 24, 2004 • Accepted: December 7, 2004

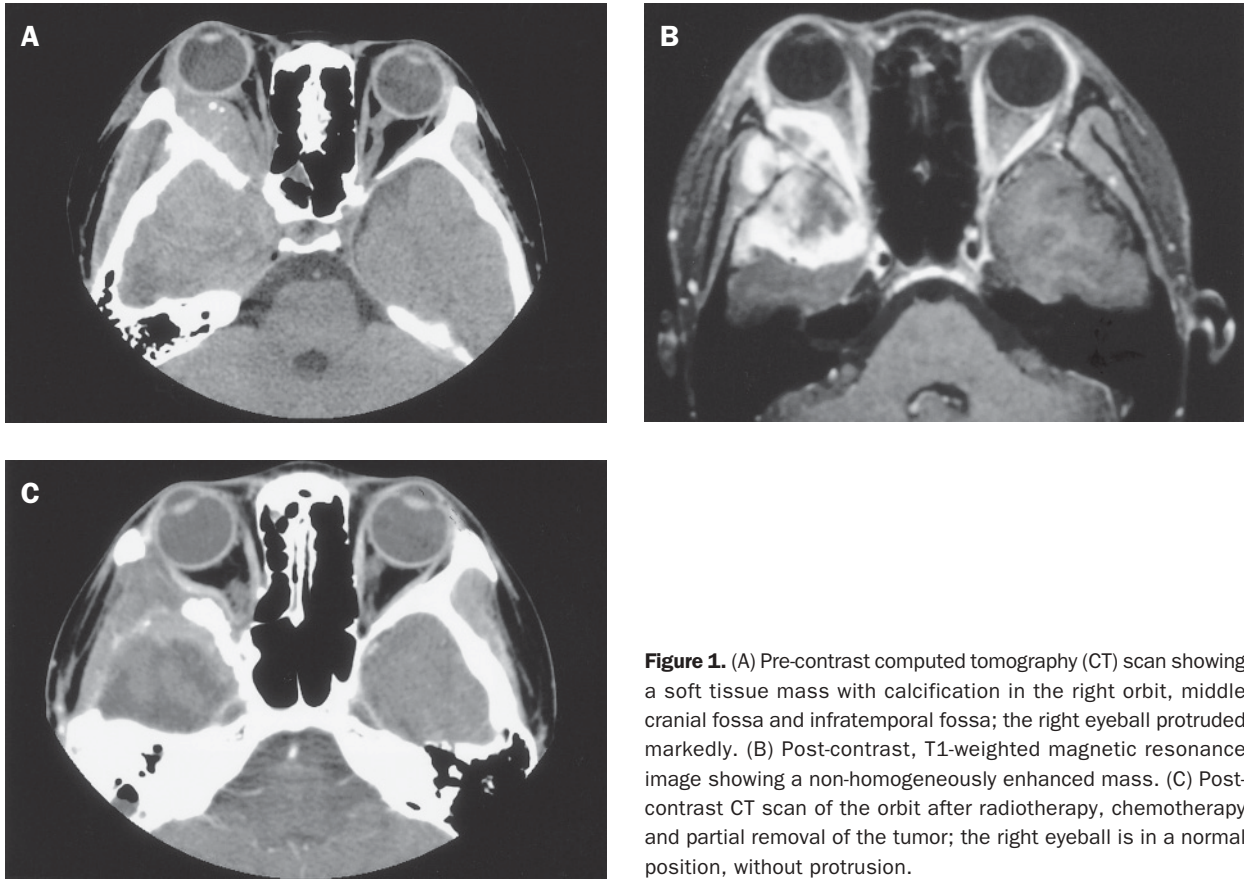


Figure 1. (A) Pre-contrast computed tomography (CT) scan showing a soft tissue mass with calcification in the right orbit, middle cranial fossa and infratemporal fossa; the right eyeball protruded markedly. (B) Post-contrast, T1-weighted magnetic resonance image showing a non-homogeneously enhanced mass. (C) Post-contrast CT scan of the orbit after radiotherapy, chemotherapy and partial removal of the tumor; the right eyeball is in a normal position, without protrusion.

reconstruction with strut allograft arthrodesis, was performed in April 2000.

The postoperative follow-up was uneventful until October 2001, when painful protrusion of the right eyeball appeared. A hypervascular mass in the right orbit, middle cranial fossa, and infratemporal fossa, was detected by imaging studies (Figure 1). Her best corrected visual acuity was 20/200 (right eye) and 20/20 (left eye) at the initial presentation. Embolization of the mass was performed 1 week later, with more than 90% obliteration of tumor stains. Nonetheless, her right-eye vision deteriorated to no light perception after 1 month. Proptosis of the right eyeball got worse, with movement limitation in all directions. The right pupil was dilated without response to light, but the right optic disc was still pinkish with a clear margin. The posterior chorioretina was elevated due to retrobulbar compression. The left eye was normal. No signs of pulmonary metastasis or local recurrence at the primary site were identified with chest computed tomography (CT) and magnetic resonance imaging (MRI) of the lower extremities.

Under the impression of osteosarcoma with orbital and skull base metastases, the patient underwent radio-

therapy (4,000 cGy in 20 fractions), chemotherapy with methotrexate, and then surgery for partial removal of the tumor mass only, because the extensive involvement of the skull base precluded complete resection. Pathologic examinations suggested metastatic osteosarcoma with extensive tumor necrosis (Figure 2). The patient's right-eye vision improved to counting fingers (CF) at 50 cm, 1 month after the completion of radiotherapy, but before chemotherapy and surgery. The optic disc, however, became waxy pale. The proptosis and limitation of eye movements improved progressively to normal. Unfortunately, lung metastases occurred in September 2002. The patient underwent metastatectomy and chemotherapy. Tumor metastasis to the right maxilla developed in April 2003. Local irradiation was administered. The patient's right-eye vision remained stable at around CF/50 cm at the last follow-up visit in October 2003.

Discussion

Osteosarcoma was once a highly fatal bone sarcoma, with more than 80% of patients dying from the disease

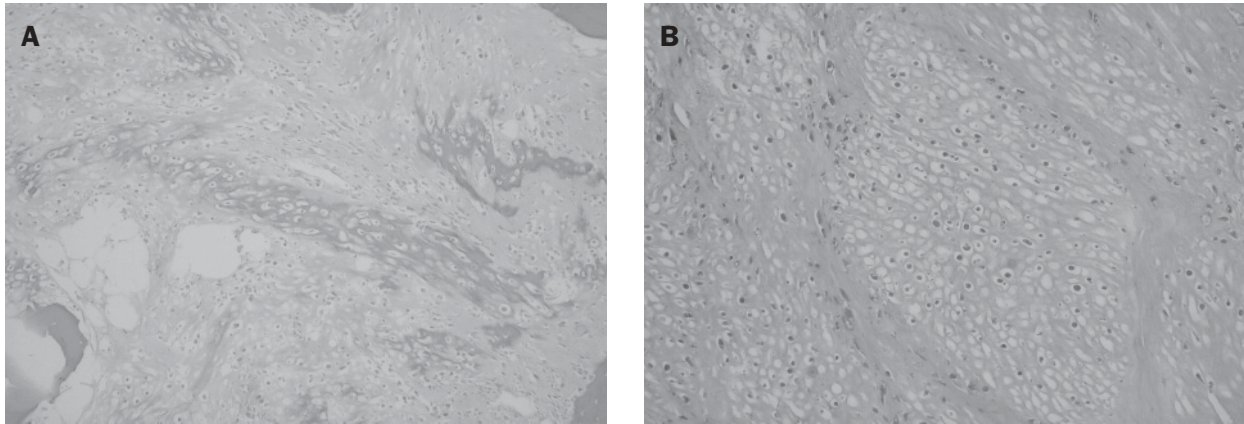


Figure 2. (A) Photomicrograph (after chemotherapy) of the primary tumor at the right proximal tibia; the chondroid component can still be seen (hematoxylin & eosin, $\times 150$). (B) The metastatic tumor (after radiotherapy and chemotherapy) at the skull base; the shadow of necrotic tissue similar to osteosarcoma is demonstrated (hematoxylin & eosin, $\times 150$).

within 5 years of diagnosis.⁶ However, as treatment regimens have progressed, the life expectancy for patients without metastases at presentation has improved greatly.¹ Such patients usually experience subsequent pulmonary relapses, although non-pulmonary metastases are increasing.² The management of relapsed patients includes aggressive metastatectomy and chemotherapy, and some metastatic osteosarcomas may be radiosensitive.^{7,8} Publications about the management of orbital metastatic osteosarcoma are rare. For primary orbital osteosarcoma, there has been no conclusion about which treatment modality is best. Further, patients with osteosarcoma of the head are generally older than those with osteosarcoma of the long bones, so responses to treatment might be different.⁹ The proptosis in our patient regressed and her vision improved after radiotherapy. The surgical specimen, after radiotherapy and chemotherapy, showed extensive tumor necrosis. Thus, combined radiotherapy, chemotherapy and surgery can be effective in the palliative treatment of orbital metastatic osteosarcoma, whereas further clinical experience is needed to define the potential role of embolization.

Metastatic rather than primary orbital tumors usually lead to faster progression of proptosis, often associated with pain, diplopia, and disturbances of ocular motility; other symptoms include vision loss, ptosis, conjunctival chemosis/injection, eyelid edema, and epiphora.³ Ocular symptoms and clinical data for the 3 reported cases of orbital metastatic osteosarcoma are listed in Table 1. Proptosis was observed in all 3 patients. Visual acuity ranged widely from normal to no light perception. Since there are no lymphatic channels in the retrobulbar area, metastatic tumors mainly reach the orbit via hematogenous routes, although in osteosarcoma, the most frequent site of metastasis is the lung. However, in our patient, and in the case reported by Misra et al,⁴ the lung was not involved at the presentation of orbital metastasis. There was no mention of whether the lung was involved in the case reported by Mohadjer et al.⁵ Spreading of tumor to the orbit, sparing the lung, has been suggested via Batson's paravertebral system.⁴ Further, multiple metastases to other facial bones and the skull base can occur together with orbital metastases, as observed in our patient and in the case reported by Mohadjer et al.⁵

Table 1. Characteristics of cases of orbital metastatic osteosarcoma

Case	Authors	Age (yr)/ Gender	Primary tumor	Histology	Duration* (mo)	Orbital metastasis	Symptoms
1	Misra et al ⁴	8/M	Right tibia	N/A	6	Right	Proptosis, normal vision
2	Mohadjer et al ⁵	26/M	Right pubis	Telangiectatic	36	Bilateral	Proptosis, visual field constriction, third nerve palsy, optic atrophy
3	Lin et al (this report)	15/F	Right tibia	Osteoblastic	22	Right	Proptosis, vision loss, optic atrophy

*From the presentation of the primary tumor to the occurrence of orbital metastasis.

In conclusion, orbital metastasis of osteosarcoma, although extremely rare in the past, should be considered when monitoring the condition of patients with osteosarcoma. Indeed, non-pulmonary metastases in osteosarcoma are increasing in prevalence because of prolonged longevity in patients receiving modern treatments. Proptosis is the most frequent sign of orbital metastasis. Aggressive treatment with chemotherapy, radiotherapy and surgical debulking can relieve symptoms and possibly improve vision if it is severely impaired. Further cases are needed to more clearly define the clinical characteristics of osteosarcoma with orbital metastases.

References

- Gebhardt MC, Hornicek FJ. Osteosarcoma. In: Menendez LR, ed. *Orthopedic Knowledge Update: Musculoskeletal Tumors*. Rosemont: American Academy of Orthopedic Surgeons, 2002: 175-86.
- Giuliano AE, Feig S, Eilber FR. Changing metastatic patterns of osteosarcoma. *Cancer* 1984;54:2160-4.
- Shields JA. Metastatic cancer to the orbit. In: McAllister L, ed. *Diagnosis and Management of Orbital Tumors*. Philadelphia: WB Saunders, 1989:291-313.
- Misra A, Misra S, Chaturvedi A, Srivastava PK. Osteosarcoma with metastasis to the orbit. *Br J Ophthalmol* 2001;85: 1387-8.
- Mohadjer Y, Wilson MW, Fuller CE, Haik BG. Primary pelvic telangiectatic osteosarcoma metastatic to both orbits. *Ophthalm Plast Reconstr Surg* 2004;20:77-9.
- Dahlin DC, Coventry MB. Osteogenic sarcoma: a study of six hundred cases. *J Bone Joint Surg Am* 1967;49:101-10.
- Shibamoto Y, Horii N, Takahashi M. Long-term control of multiple lung metastases from osteosarcoma obtained by conventional radiotherapy: a case report. *Oncol Rep* 1999;6: 1085-7.
- Mogulkoc N, Goker E, Atasever A, Veral A, Ozkok S, Bishop PW. Endobronchial metastasis from osteosarcoma of bone: treatment with intraluminal radiotherapy. *Chest* 1999;116: 1811-4.
- Ha PK, Eisele DW, Frassica FJ, Zahurk ML, McCarthy EF. Osteosarcoma of the head and neck: a review of the Johns Hopkins experience. *Laryngoscope* 1999;109:964-9.