

Shepherd's Crook Deformity of Polyostotic Fibrous Dysplasia Treated with Corrective Osteotomy and Dynamic Hip Screw

Wei-Jen Chen, Wei-Ming Chen*, Chao-Ching Chiang, Ching-Kuei Huang, Tain-Hsiung Chen, Wai-Hee Lo
Department of Orthopedics and Traumatology, Taipei Veterans General Hospital, and Department of Surgery, National Yang-Ming University School of Medicine, Taipei, Taiwan, R.O.C.

Fibrous dysplasia, a condition in which the skeleton fails to develop normally, is characterized by fibroblastic stroma and immature bone. Bowing of the long bones occurs frequently in the polyostotic form, and stress fractures often result. Shepherd's crook deformity is a characteristic feature of fibrous dysplasia. The goal of its treatment is to obtain normal walking ability and relieve pain due to pathologic fracture secondary to the deformity; however, correction of the deformity is a surgical challenge. We present 2 cases of shepherd's crook deformity treated with corrective osteotomy and a dynamic hip screw. Both cases showed good bone healing and no recurrent deformity. The gross deformities were corrected, and both patients were pain-free after operation. [*J Chin Med Assoc* 2005;68(7):343–346]

Key Words: corrective osteotomy, dynamic hip screw, fibrous dysplasia, shepherd's crook deformity

Introduction

Fibrous dysplasia is a benign bone lesion resulting from congenital dysplasia of bone. It is characterized by fibro-osseous tissue replacing normal bone tissue. According to its clinical pattern, fibrous dysplasia can be divided into 3 types: monostotic, polyostotic, and Albright's syndrome. Patients with the monostotic type have a single or multiple areas of involvement (which may or may not be confluent) in a single bone. Monostotic fibrous dysplasia accounts for about 70% of all cases of fibrous dysplasia. Patients with the polyostotic type have involvement of multiple bones. Albright's syndrome is a polyostotic type of dysplasia associated with abnormal skin pigmentation and pathologic endocrine dysfunction. When the weight of the body acts through the mechanically weakened bone, deformity gradually develops.¹⁻⁴ One well-recognized deformity in polyostotic fibrous dysplasia is shepherd's crook deformity, which causes severe varus in the proximal femur. Untreated shepherd's

crook deformity results in limb shortening, limping and, occasionally, chronic fatigue fracture accompanied by disabling pain. However, the treatment of shepherd's crook deformity is challenging because of the severely deformed and weakened bone. We present 2 cases of shepherd's crook deformity successfully treated with corrective osteotomy and internal fixation with a dynamic hip screw.

Case Reports

Case 1

A 30-year-old woman, who had experienced intermittent right hip pain since childhood, had fractures in her right hip twice: at age 6 and 8 years. In each case, a hip spica was applied, and the fracture healed uneventfully. Subsequently, however, the patient was bothered by limping and deformity of her right lower leg. At the age of 19, because of impending fracture of the right proximal femur, bone grafting was

*Correspondence to: Dr. Wei-Ming Chen, Department of Orthopedics and Traumatology, Taipei Veterans General Hospital, 201, Section 2, Shih-Pai Road, Taipei 112, Taiwan, R.O.C.
 E-mail: wmchen@vghtpe.gov.tw • Received: March 17, 2004 • Accepted: November 4, 2004

performed at a local hospital. Biopsy confirmed a diagnosis of fibrous dysplasia.

Due to worsening symptoms, the patient was referred to our hospital for further treatment. Examinations at the first visit revealed a severe limping gait, with 9-cm shortening of the right lower extremity, as measured on a standing, full-length, lower-limb radiograph. Radiography also revealed a typical ground-glass appearance with shepherd's crook deformity, and the femoral neck-shaft angle measured 45° (Figure 1). Closed-wedge osteotomy was performed and then fixed with a 135° , 8-hole, dynamic hip screw (Figures 2 and 3). No additional bone graft was used. Postoperatively, non-weight-bearing was advised for 2 months, and partial weight bearing for another 2 months. Follow-up radiography 3 months after the operation revealed union at the osteotomy site. The degree of limb shortening was corrected from 9 cm preoperatively to 4 cm postoperatively. The femoral

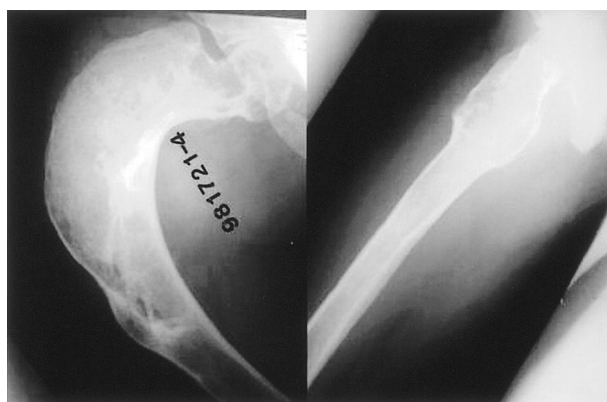


Figure 1. Radiograph of a 30-year-old female with severe shepherd's crook deformity of the right proximal femur.

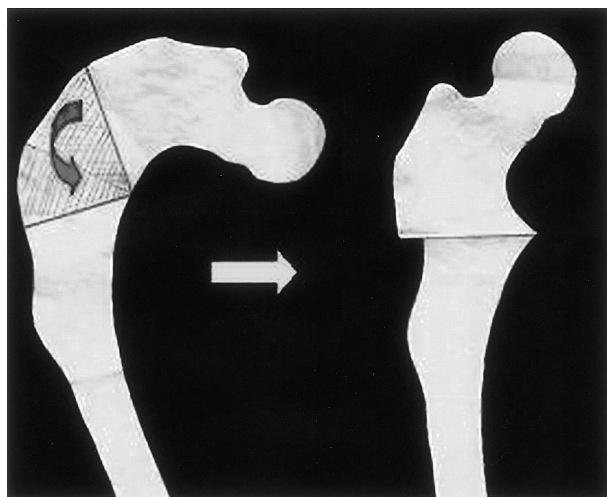


Figure 2. Planning the wedge osteotomy site preoperatively with a paper template.

neck-shaft angle was corrected from 45° preoperatively to 130° postoperatively. The last follow-up radiographs, 11 years after the operation, revealed no recurrent deformity of the neck-shaft angle and no implant failure (Figure 4). The patient is free of hip pain, but has mild limping, and requires 1 shoe pad elevated because of her 4-cm leg-length shortening.

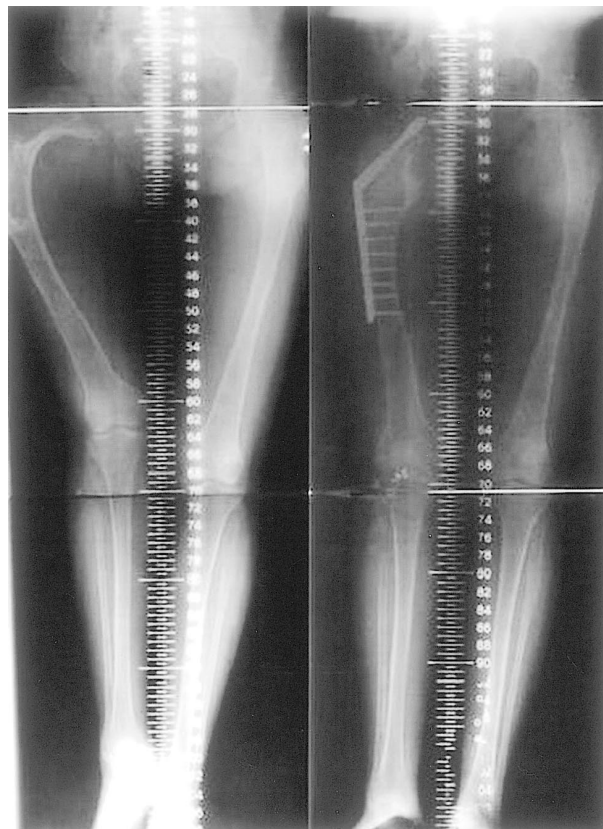


Figure 3. Preoperative (left) and postoperative (right) long-cassette radiographs; the neck-shaft angle was corrected from 45° to 135° , and lower-leg shortening was corrected from 9 cm to 4 cm.

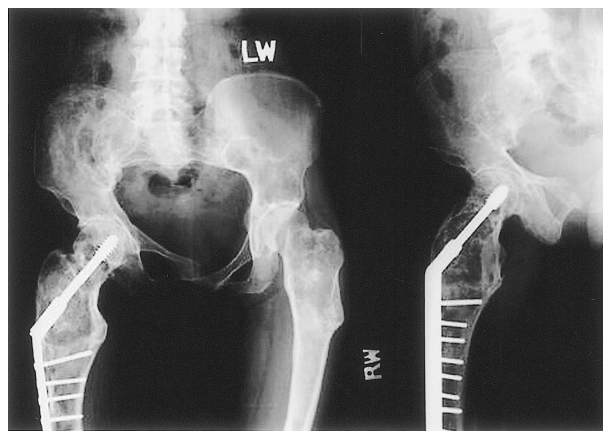


Figure 4. Radiographs 11 years after operation show solid union at the osteotomy site, with no evidence of recurrent deformity or implant failure.

Case 2

A woman who first presented at age 13 years with left hip fracture had remaining mild deformity after spontaneous fracture healing; pain over the left hip started to be felt at age 26 years. The patient came to our hospital at age 31 years, after several years of problems. Radiographs revealed polyostotic fibrous

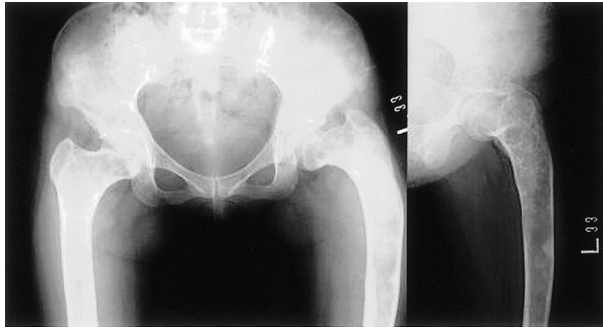


Figure 5. Radiograph of a 31-year-old female with severe shepherd's crook deformity of the left proximal femur (115° neck-shaft angle).

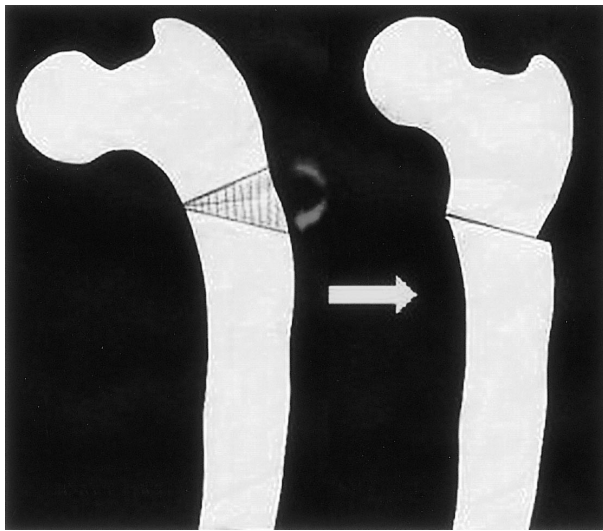


Figure 6. Planning the wedge osteotomy site preoperatively with a paper template.

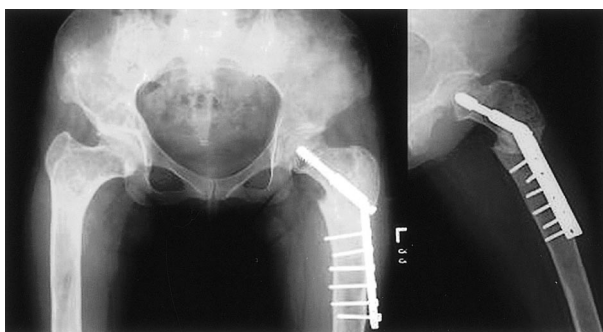


Figure 7. Radiographs 6 months after operation showing solid union of the osteotomy site.

dysplasia with a typical shepherd's crook deformity of the left femur. The neck-shaft angle of the left femur was 115° (Figure 5). The patient underwent closed-wedge osteotomy for correction of the left proximal femur deformity (Figure 6). Fixation of the osteotomy site with a gamma nail was planned initially; however, adequate fixation could not be obtained intraoperatively because of a widened intramedullary canal. Finally, proximal and distal bone fragments were stabilized using a 6-hole, dynamic hip screw (Figure 7). No additional bone graft was placed. The leg-length discrepancy was corrected from 1-cm shortening preoperatively to 1 cm longer postoperatively (this over-correction was unintended). The femoral neck-shaft angle was corrected to 130° . Postoperatively, non-weight-bearing was advised for 2 months, and partial weight bearing for another 2 months. The patient returned to normal activity without symptoms 6 months after surgery. After 25 months of post-operative follow-up, the femur showed good union and alignment radiographically.

Discussion

Fibrous dysplasia is a benign bony lesion that usually becomes quiescent after adolescence.^{2,5} Despite its benign character, however, it may cause problems, because normal bone is replaced with fibrous tissue. When the weight of the body and the strong gluteal muscles act on the weakened proximal femur, plastic deformity gradually develops and stress fracture may occur.^{1-4,6} There are various procedures for treating proximal femoral lesions in fibrous dysplasia, including curettage and bone grafting, valgus osteotomy, plating and hip nailing, intramedullary nailing, and cortical bone grafting. Russell and Chandler⁷ reported 11 cases of fibrous dysplasia treated surgically in 1950. They concluded that the indications for surgery in fibrous dysplasia were continued pain in the region of a localized bone lesion, fracture through a lesion, or severe deformity.⁷

Since mechanical stress is the most important cause of deformity after puberty, proper internal fixation can provide a type of mechanical support, although disease progression cannot be altered.^{5,8,9} There are various options for treating shepherd's crook deformity, but no single type of internal fixation appears to provide a major advantage over the others. Breck¹ reported a case of fibrous dysplasia treated with total femoral plating and hip nailing, without further fracture or subsequent implant failure. Connolly³ and Freeman et al⁴ reported the use of osteotomies with Zickel nail

fixation to correct and control deformity. As the femoral head is often spared from the disease, firm purchase of the implant in the femoral head provides sufficient mechanical support and reduces the recurrence rate of the deformity.^{5,9,10}

In the present report, osteotomy with internal fixation of a dynamic hip screw had good results. We used a paper template to evaluate the osteotomy level preoperatively. By folding the template to the normal neck-shaft angle, it was possible to estimate the osteotomy level and length of the closed-wedge, as shown in Figures 2 and 6. It was not difficult to apply the fixation device after the single-level corrective osteotomy had been finished. The side plate should be long enough to provide adequate fixation of the mechanically deficient femur and to prevent the recurrence of deformity and implant failure. In our cases, fixation was achieved with an 8-hole side plate in 1, and a 6-hole side plate in the other. A gamma nail may be another option, because it can also provide good mechanical support over the femoral neck. In addition, it possesses a shorter level arm than a dynamic hip screw, and has a lower bending moment on the femoral neck. Initially, we tried to use a gamma nail to fix the osteotomy site in the second case. However, we found that the 12-mm diameter intramedullary nail and 2 distal screws were unable to provide adequate stability to the thinning and widened dysplastic bone. Moreover, a gamma nail is difficult to introduce, and may easily protrude from the canal because of the difficulty in locating a good entrance point and the deformed proximal femur.¹¹

As previous studies have shown that fibrous dysplasia possesses normal bone-healing potential,^{2,10,12,13} we did not make additional autologous bone grafts from the iliac crest or other sites over the osteotomy site. The uneven lateral cortex after the single-level osteotomy was filled with the bone chips from the excised bone wedge. The osteotomy site in both cases healed within 6 months. Dysplastic bone may have the capability to heal at a rate comparable to that of normal bone.

From our limited experience, we believe that

corrective osteotomy and internal fixation with a dynamic hip screw is a good and effective method for treating severe symptomatic shepherd's crook deformity. This procedure can provide full contact with the osteotomy surface and is relatively easy, and the healing capability of dysplastic bone does not seem to be a cause for concern.

References

1. Breck LW. Treatment of fibrous dysplasia of bone by total femoral plating and hip nailing. *Clin Orthop* 1972;82:82-3.
2. Funk FJ Jr, Wells RE. Hip problems in fibrous dysplasia. *Clin Orthop* 1973;90:77-82.
3. Connolly JF. Shepherd's crook deformity of polyostotic fibrous dysplasia treated by osteotomy and Zickel nail fixation. *Clin Orthop* 1977;23:22-4.
4. Freeman BH, Bray EW 3rd, Meyer LC. Multiple osteotomies with Zickel nail fixation for polyostotic fibrous dysplasia involving the proximal part of the femur. *J Bone Joint Surg [Am]* 1987;69:691-8.
5. Ozaki T, Sugihara M, Nakatsuka Y, Kawai A, Inoue H. Polyostotic fibrous dysplasia: a long term follow up of 8 patients. *Int Orthop* 1996;20:227-32.
6. Enneking WF, Gearen PF. Fibrous dysplasia of the femoral neck: treatment by cortical bone-grafting. *J Bone Joint Surg [Am]* 1986;68:1415-22.
7. Russell LW, Chandler FA. Fibrous dysplasia of bone. *J Bone Joint Surg [Am]* 1950;32:323-37.
8. Stephenson RB, London MD, Hankin FM, Kaufer H. Fibrous dysplasia: an analysis of options for treatment. *J Bone Joint Surg [Am]* 1987;69:400-9.
9. Guille JT, Kumar SJ, MacEwen GD. Fibrous dysplasia of the proximal part of the femur: long-term results of curettage and bone-grafting and mechanical realignment. *J Bone Joint Surg [Am]* 1998;80:648-58.
10. Harris WH, Dudley HR Jr, Barry RJ. The natural history of fibrous dysplasia: an orthopaedic, pathological, and roentgenographic study. *J Bone Joint Surg [Am]* 1962;44:207-33.
11. Yamamoto T, Hashimoto Y, Mizuno K. Oblique wedge osteotomy for femoral diaphyseal deformity in fibrous dysplasia. *Clin Orthop* 2001;384:245-9.
12. Enneking WF. Fibrous lesion originating in bone. In: *Musculoskeletal Tumor Surgery*. New York: Churchill-Livingstone, 1983:855-67.
13. Campanacci M. Fibrous dysplasia. In: *Bone and Soft Tissue Tumors, 2nd edition*. New York: Springer-Verlag Wien, 1999: 435-61.