

Spinal Cord Implantation with Acidic Fibroblast Growth Factor as a Treatment for Root Avulsion in Obstetric Brachial Plexus Palsy

Pei-Hsin Lin^{1,3}, Henrich Cheng^{1,3}, Wen-Cheng Huang^{1,3}, Tien-Yow Chuang^{2,3*}

¹*Division of Nerve Repair, Department of Neurosurgery, Neurological Institute,*

²*Department of Physical Medicine and Rehabilitation, Taipei Veterans General Hospital,*
and ³*National Yang-Ming University School of Medicine, Taipei, Taiwan, R.O.C.*

Nerve root avulsion carries the worst prognosis among brachial plexus injuries and remains a great challenge for surgeons to repair. In this case, a boy with complete avulsion of the left-side C6 root presented with flaccid paralysis of the left arm after birth. As there was no significant spontaneous recovery, the patient underwent operation when he was 6 months old. One end of the nerve graft from the sural nerve was anastomosed with the avulsed C6 root, and the other end was implanted into the ventrolateral aspect of the spinal cord with fibrin glue containing acidic fibroblast growth factor. After 2 years of follow-up, there has been significant improvement in motor function and in electrophysiologic studies over the left upper limb. [*J Chin Med Assoc* 2005;68(8):392–396]

Key Words: acidic fibroblast growth factor, obstetric brachial plexus palsy, root avulsion, spinal cord implantation

Introduction

Obstetric brachial plexus palsy (OBPP) represents a special subgroup of brachial plexus injury and is one of the most devastating complications resulting from birth trauma. Complete root avulsion is a particularly serious condition with a bleak prognosis, as it is generally regarded as a type of spinal cord lesion.¹ Current surgical repair of acute injury may be accomplished by reconstruction involving nerve grafts or nerve transfer, using the surrounding nerves as donors.² The outcome, however, is far from satisfactory. As such, strategies to enhance axon and oligodendrocyte regeneration and peripheral neural growth are being targeted.

In our previous rat model studies, we found that several transected cervical roots could regenerate through intercostal nerve grafts using fibrin glue;

adding acidic fibroblast growth factor (aFGF) could increase the efficacy of sprouting.^{3,4} We also showed that functional recovery and most regenerating axons within the dorsal horn disappeared with re-cutting of the grafted sensory roots.⁵ We therefore believe that aFGF stimulates neural proliferation and growth and may also be neuroprotective.^{6–8} However, the efficacy of growth factors in realistic models has not yet been supported by formal clinical studies.

Although a few studies suggested a modest benefit in return of function after avulsed roots were implanted into the ventral cord,^{9,10} there have been no publications to show the efficacy of neurotrophic factors in repairing avulsed spinal nerve roots. We present a unique case of OBPP involving nerve grafting and implantation of the completely avulsed C6 root into the ventrolateral aspect of the spinal cord using a fibrin gel containing aFGF.

*Correspondence to: Dr. Tien-Yow Chuang, Department of Physical Medicine and Rehabilitation, Taipei Veterans General Hospital, 201, Section 2, Shih-Pai Road, Taipei, 112, Taiwan, R.O.C.

E-mail: tychuang@vghtpe.gov.tw • Received: September 1, 2004 • Accepted: February 23, 2005

Case Report

A 4-month-old patient with a birth weight of 3,170 g presented with persistent flaccid paralysis of the left upper limb after an uneventful vaginal delivery and birth history. The newborn underwent a comprehensive multidisciplinary rehabilitation program from birth, but no significant functional improvement was achieved.

A physical examination revealed mild atrophy of the left biceps, triceps and deltoid. Muscle power scored by the Medical Research Council system was graded 0/5 for over-shoulder abduction and elbow flexion, and 2/5 for elbow extension. There were no abnormalities in wrist or finger movements. Rating using the Toronto grading system by Clarke and Curtis¹¹ was 0/7 (no contraction) for over-shoulder abduction and elbow flexion, 3/7 (motion > 1/2 range with gravity eliminated) for over-elbow extension with gravity eliminated, and full antigravity movement for over flexion and extension of the wrist, fingers and thumb. Grasping function was normal. Shoulder

function according to Gilbert's classification (modified Mallet scale)¹² was stage 0 (no abduction) (Figure 1A). Electrodiagnostic study of the left upper limb demonstrated markedly decreased motor unit recruitment for the deltoid and biceps, and moderately decreased motor unit recruitment for the triceps. Occasional fibrillation potentials were also noted over the deltoid and biceps. Magnetic resonance imaging of the cervical spine revealed a pseudomeningocele on the left side at level C5–6, consistent with nerve root avulsion. No immediate surgical intervention was initiated due to parental hesitation. However, since there was no further motor improvement, the boy underwent surgery when he was 6 months old.

Under general anesthesia, the patient was placed in a prone position. An incision was made longitudinally in the midline of the posterior neck region, and was deepened to spinous processes and lamina. A C3–T1 total laminectomy revealed total avulsion of the left C6 spinal nerve root, with the distal end found extradurally (Figures 2 and 3). Intraoperative electrophysiologic

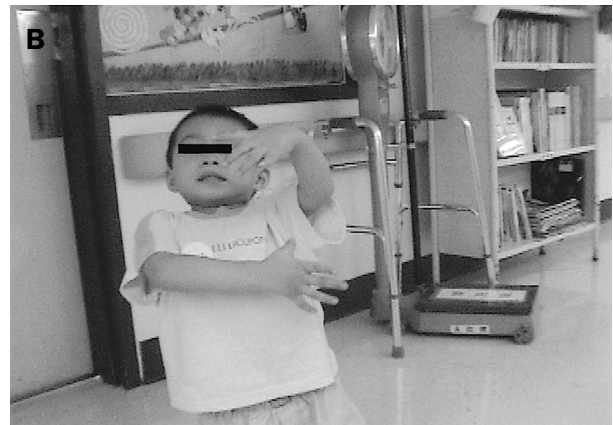
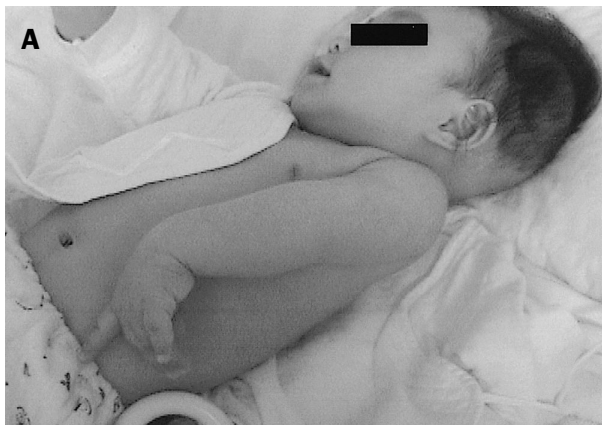
Figure 1. (A) A 6-month-old boy with obstetric brachial plexus palsy presented with no shoulder abduction and elbow flexion; there was only grade 3/5 of anterior flexion to 30° against gravity; (B) 2 years after the operation, antigravity shoulder abduction and anterior flexion to 120° was achieved.

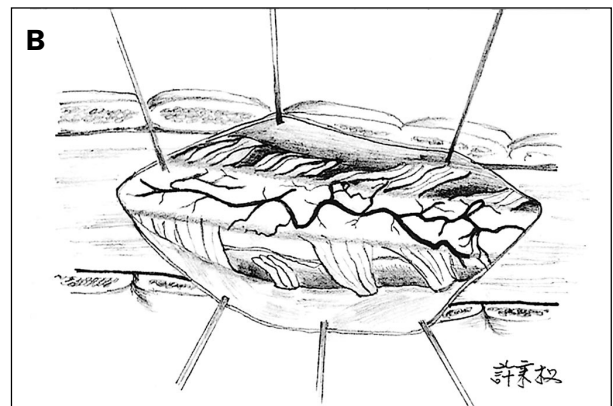
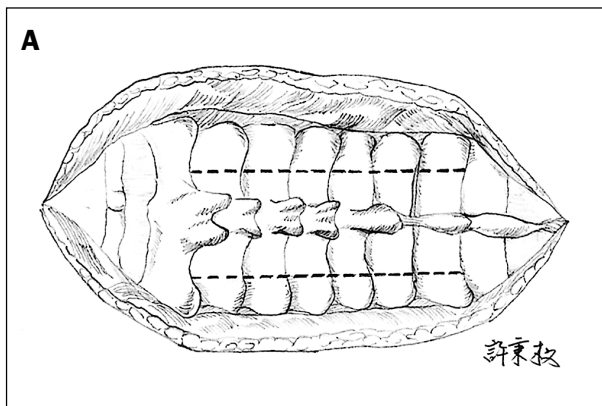


Figure 2. (A) The dotted line shows total laminectomy from C3–T1; (B) the schematic drawing shows the operative finding of the avulsed C6 root.

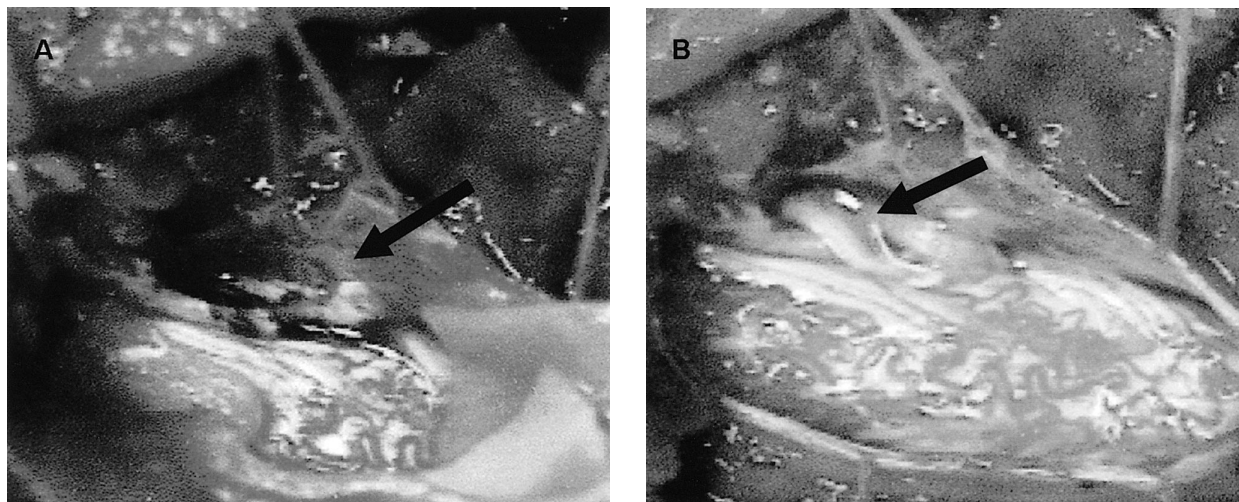


Figure 3. (A) Root avulsion at C6; the arrow indicates the avulsed left-side C6 root, which was retracted to the dura; (B) the arrow indicates the nerve root, which was reconnected with fibrin glue containing acidic fibroblast growth factor.

examination was performed to determine the continuity of other cervical roots.

A peripheral nerve graft, 25 mm in length, was harvested from the left sural nerve and kept in Hanks' balanced salt solution. One end of the graft was anastomosed microscopically to the C6 nerve root with 10-O microsutures in an end-to-end fashion. The other end of the graft was then approximated into the ventrolateral aspect of the spinal cord through a tiny pia incision. Fibrin glue (Beriplast® P; Aventis Behring, Marburg, Germany) was prepared by mixing the fibrinogen (10 mg/mL) with aprotinin solution (2,000 kIU/mL) plus calcium chloride (8 mM) and aFGF (20 µg); it was applied to the surgical area to form a glue cast. After the nerve root was reconnected, fibrin glue was applied to the grafted area. To support the nerve root regenerating process and achieve significant concentrations of aFGF at the target side, we performed nerve root injections of aFGF (20 µg) through a monopolar needle at 1 and 1.5 years after the operation. This study was approved by the Medical Ethics Committee of our hospital and the local institutional review board. Informed consent was obtained from the child's parents.

Six months after the operation, traces of shoulder abduction and elbow flexion motor activity developed. Nine months postoperatively, the boy achieved a Toronto grading of 2/7 (motion < 1/2 range with gravity eliminated) for over-shoulder abduction and elbow flexion, and 4/7 (full motion with gravity eliminated) for elbow extension. After 1 year of follow-up, the Toronto grading turned 4/7 for over-shoulder abduction and elbow flexion, and 5/7 (motion < 1/2 range against gravity) for over-elbow extension.

Electrodiagnostic study revealed increased recruitment of motor units in the deltoid, biceps and triceps, compared with previous electromyographic examination. The amplitude of the compound motor action potential in the left deltoid and biceps approximated 45% and 83%, respectively, as compared with the right-side muscles (Table 1). Two years postoperatively, over-elbow flexion was 5/7 and over-shoulder abduction and elbow extension was 6/7 (motion > 1/2 range against gravity). Shoulder function assessed by Gilbert's classification was improved to stage IV, with shoulder abduction to 120–160° (Figure 1B). Electrodiagnostic study after 2 years of follow-up was not completed because of pain on needle examination, and the parents refused further examination.

Discussion

Although surgical intervention to regain function of avulsed roots in humans is uncommon, axons seem capable of regenerating in a favorable environment.¹³ Some earlier studies provide experimental data that point to the possibility of restoring the spinal cord and avulsed root connection. Numerous laboratory investigations in different animal species, including primates, have focused on strategies for implantation of avulsed roots into the spinal cord.^{14–17} Such investigations showed that reconnection between the spinal cord and injured roots can be achieved with regeneration across the peripheral and central nervous system (CNS) interface. Although activation of nerve regrowth is vital, it is only the initial element in the

Table 1. Electrophysiologic studies of the left side upper limb in a 6-month-old boy with obstetric brachial plexus palsy

	Preoperative	6 months postoperatively	1 year postoperatively
CMAP amplitude, %*			
Deltoid	ND	23	45
Biceps	ND	48	83
Motor unit recruitment/Fib, PSW†			
Infraspinatus	Normal/–	Normal/–	Normal/–
Deltoid	Markedly decreased/2+	Markedly decreased/1+	Moderately decreased/0
Biceps	Markedly decreased/2+	Moderately decreased/0	Moderately decreased/0
Triceps	Moderately decreased/0	Moderately decreased/0	Mildly decreased/0
ADQ	Normal/0	ND	ND

*Percent relative to normal side, with stimulation site at Erb's point; †grading of Fib, PSW is as follows: 0, no Fib; 1+, single trains in ≥ 2 muscle regions; 2+, moderate numbers in ≥ 3 muscle areas; 3+, many in muscle regions; 4+, in all areas of sampled muscles.²⁵ ADQ = adductor digiti quintus; CMAP = compound motor action potentials; Fib = fibrillation potentials; ND = not done; PSW = positive sharp waves.

complex process of regeneration. Additional components such as facilitation of axonal growth and precision of axonal regeneration must also be addressed. Whether or not neurotrophic factors are a required component of modern surgical root repair remains to be seen.

The minimal motor regain noted in this patient 6 months after surgical repair with aFGF is greater than the average rate of axonal growth observed in human nerves, suggesting that reformed functional synapses are a possible contributor to early recovery; however, collateral sprouting from neighboring nerves cannot be excluded. For ethical reasons, nerve root blocking¹⁰ was not performed in this boy to elucidate the speculation. Thus, at present, the origin, mechanism, or pathway underlying the recovery remains unknown. Previous research found that nerve grafts used along with exogenous aFGF improved somatosensory evoked potentials (SEPs) of cut dorsal roots. After re-transection of the repaired roots, SEPs were completely eliminated. This verified that the SEPs' origin was from regenerated axons rather than from reinnervation of adjacent intact roots.⁵

Sufficient new and functional synapses and regenerating axons were required for this boy to recover some motor function. Antigravity movement developed in shoulder abduction and elbow flexion 1 year postoperatively. Two years after the operation, significant functional recovery with overhead shoulder abduction was achieved (from Gilbert's classification stage 0 to stage IV). The fact that a full year after surgery was needed for locomotor function to return may demonstrate that the synthesis rate for new synapses, graft lengths and axoplasmic transport determine the central/peripheral nervous system synapse growth rate and the duration of motor recovery.^{18,19}

Our patient had satisfactory, rather than full, motor recovery after 2 years; perinatal root avulsion may have led to loss of some of the axotomized motor neurons, thus limiting the possibility of full recovery. Indeed, early research indicated that the motor neuron pool depleted about 7–10% per week after spinal avulsion.^{20–22} Another explanation for our finding could be the short half-life of aFGF added to fibrin glue. Neurotrophic factors in general have poor pharmacokinetic profiles and short *in vivo* half-lives.²³ Mixing aFGF with fibrin glue does allow for slow release of the growth factor; however, the access of growth factors to the CNS is largely impeded by multiple clearance processes.²⁴ Therefore, aside from the initial local injection at the repair site, the authors performed 2 sequential C6 nerve root injections, guided by electromyographic recordings, 1 and 1.5 years after surgery. In future, advances in targeted drug delivery methods for neurotrophic factors will most likely determine the clinical usefulness of such factors for CNS conditions.

In this case, recovery may have been related to something other than reconstruction of the C6 nerve root. As we were unable to clearly demonstrate a cause and effect relationship between treatment and recovery, our case study has limitations. Animal studies provide the opportunity to use various modalities for investigations; however, experimental investigations were not possible in our patient.

In conclusion, this report indicates that nerve graft and spinal cord implantation using aFGF in fibrin glue may improve upper limb muscle activity in cervical root avulsion of OBPP, and reduce the level of disability and consequences in this patient population. However, a definitive positive effect for this novel technique requires verification in further studies involving greater numbers of patients.

References

1. Seddon HJ. *Surgical Disorders of the Peripheral Nerves*. Baltimore: Williams and Wilkins Company, 1971.
2. Spinner RJ, Kline DG. Surgery for peripheral nerve and brachial plexus injuries or other nerve lesions. *Muscle Nerve* 2000;23:680-95.
3. Chuang TY, Huang MC, Chen KC, Chang YC, Yen YS, Lee LS, Cheng H. Forelimb muscle activity following nerve graft repair of ventral roots in the rat cervical spinal cord. *Life Sci* 2002;71:487-96.
4. Huang MC, Chen KC, Chuang TY, Chang WC, Lee LS, Huang WC, Cheng H. Cervical root repair in adult rats after transection: recovery of forelimb motor function. *Exp Neurol* 2003;180:101-9.
5. Lee LM, Huang MC, Chuang TY, Lee LS, Cheng H, Lee IH. Acidic FGF enhances functional regeneration of adult dorsal roots. *Life Sci* 2004;74:1937-43.
6. Baffour R, Achanta K, Kaufman J, Berman J, Garb JL, Rhee S, Friedmann P. Synergistic effect of basic fibroblast growth factor and methylprednisolone on neurological function after experimental spinal cord injury. *J Neurosurg* 1995;83:105-10.
7. Gospodarowicz D, Neufeld G, Schweigerer L. Molecular and biological characterization of fibroblast growth factor, an angiogenic factor which also controls the proliferation and differentiation of mesoderm and neuroectoderm derived cells. *Cell Differ* 1986;19:1-17.
8. Walter MA, Kurouglu R, Caulfield JB, Vasconez LO, Thompson JA. Enhanced peripheral nerve regeneration by acidic fibroblast growth factor. *Lymphokine Cytokine Res* 1993;12:135-41.
9. Carlstedt T, Anand P, Hallin R, Misra PV, Noren G, Seferlis T. Spinal nerve root repair and reimplantation of avulsed ventral roots into the spinal cord after brachial plexus injury. *J Neurosurg* 2000;93:237-47.
10. Carlstedt T, Grane P, Hallin RG, Noren G. Return of function after spinal cord implantation of avulsed spinal nerve roots. *Lancet* 1995;346:1323-5.
11. Clarke HM, Curtis CG. An approach to obstetrical brachial plexus injuries. *Hand Clin* 1995;11:563-80.
12. Smith KJ, Kodama RT. Reinnervation of denervated skeletal muscle by central neurons regenerating via ventral roots implanted into the spinal cord. *Brain Res* 1991;551:221-9.
13. Fawcett JW. Spinal cord repair: from experimental models to human application. *Spinal Cord* 1998;36:811-7.
14. Bertelli JA, Mira JC. Brachial plexus repair by peripheral nerve grafts directly into the spinal cord in rats. Behavioral and anatomical evidence of functional recovery. *J Neurosurg* 1994;81:107-14.
15. Carlstedt T, Aldskogius H, Hallin RG, Nilsson-Remahl I. Novel surgical strategies to correct neural deficits following experimental spinal nerve root lesions. *Brain Res Bull* 1993;30:447-51.
16. Hallin RG, Carlstedt T, Nilsson-Remahl I, Risling M. Spinal cord implantation of avulsed ventral roots in primates: correlation between restored motor function and morphology. *Exp Brain Res* 1999;124:304-10.
17. Hoffmann CF, Marani E, van Dijk JG, vd Kamp W, Thomeer RT. Reinnervation of avulsed and reimplanted ventral rootlets in the cervical spinal cord of the cat. *J Neurosurg* 1996;84:234-43.
18. Little JW, Ditunno JF Jr, Stiens SA. Incomplete spinal cord injury: neuronal mechanisms of motor recovery and hyper-reflexia. *Arch Phys Med Rehabil* 1999;80:587-99.
19. Calancie B, Lutton S, Broton JG. Central nervous system plasticity after spinal cord injury in man: interlimb reflexes and the influence of cutaneous stimulation. *Electroencephalogr Clin Neurophysiol* 1996;101:304-15.
20. Brannstrom T, Kellerth JO. Changes in synaptology of adult cat spinal alpha-motoneurons after axotomy. *Exp Brain Res* 1998;118:1-13.
21. Brannstrom T, Kellerth JO. Recovery of synapses in axotomized adult cat spinal motoneurons after reinnervation into muscle. *Exp Brain Res* 1999;125:19-27.
22. Novikov L, Novikova L, Kellerth JO. Brain-derived neurotrophic factor promotes axonal regeneration and long-term survival of adult rat spinal motoneurons *in vivo*. *Neuroscience* 1997;79:764-74.
23. Thorne RG, Frey WH 2nd. Delivery of neurotrophic factors to the central nervous system: pharmacokinetic considerations. *Clin Pharmacokinet* 2001;40:907-46.
24. Cheng H, Cao Y, Olson L. Spinal cord repair in adult paraplegic rats: partial restoration of hind limb function. *Science* 1996;273:510-3.
25. Wilbourn AJ. Electrodiagnosis of plexopathies. *Neurol Clin* 1985;3:511-29.