

# Radiofrequency Catheter Ablation of Coexistent Idiopathic Left Ventricular Tachycardia and Atrioventricular Nodal Reentrant Tachycardia

Ken-Pen Weng<sup>1,3,4\*</sup>, Chuen-Wang Chiou<sup>2</sup>, Ming-Ho Kung<sup>2</sup>, Chu-Chuan Lin<sup>1,3</sup>, Kai-Sheng Hsieh<sup>1,3</sup>

<sup>1</sup>Department of Pediatrics and <sup>2</sup>Division of Cardiology, Department of Internal Medicine, Kaohsiung Veterans General Hospital, Kaohsiung, <sup>3</sup>National Yang-Ming University School of Medicine, Taipei, and <sup>4</sup>Zuoying Armed Forces Hospital, Kaohsiung, Taiwan, R.O.C.

A healthy 15-year-old male patient presented with a 6-month history of recurrent attacks of palpitations. On multiple emergency room visits, a sustained wide QRS complex tachycardia with a right bundle branch block and northwest axis deviation was documented. The tachycardia was not terminated by intravenous adenosine, but was suppressed with intravenous verapamil. There was no evidence of structural heart disease, myocarditis, long QT syndrome, or electrolyte imbalance after a series of standard examinations. Idiopathic left ventricular tachycardia (ILVT) was suspected. Electrophysiologic studies revealed 2 inducible tachycardias, which were shown to represent atrioventricular nodal reentrant tachycardia (AVNRT) and ILVT. Transformation from AVNRT to ILVT occurred spontaneously following atrial pacing. Successful ablation of ILVT and the slow atrioventricular nodal pathway resulted in cure of the double tachycardia. [*J Chin Med Assoc* 2005;68(10):479–483]

**Key Words:** atrioventricular nodal reentrant tachycardia, double tachycardia, idiopathic left ventricular tachycardia, radiofrequency catheter ablation

## Introduction

Idiopathic left ventricular tachycardia (ILVT) is a distinct clinical entity with a right bundle branch block and left axis deviation; it is often responsive to verapamil and usually associated with a good prognosis.<sup>1–4</sup> The coexistence of ILVT and atrioventricular nodal reentrant tachycardia (AVNRT) has rarely been reported.<sup>5,6</sup> We describe a 15-year-old male patient who demonstrated both ILVT and AVNRT. The result of electrophysiologic study suggested that the AVNRT played a role in triggering the ILVT.

## Case Report

A 15-year-old male patient was well until 6 months prior to presentation, when he suffered from his first

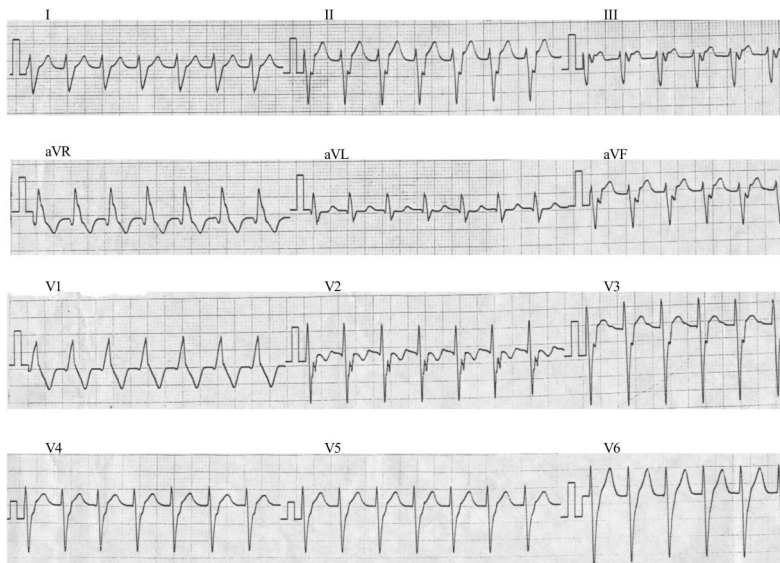
episode of palpitation and dizziness. During 1 episode of palpitation, electrocardiogram (ECG) documented wide QRS tachycardia with a right bundle branch block and northwest axis QRS morphology at a heart rate of 136 bpm (Figure 1). Intravenous adenosine did not terminate the tachycardia, but intravenous verapamil terminated it on several occasions. Despite prophylactic oral verapamil (120 mg/day), symptomatic episodes occurred in the following months. He was referred to our hospital for further investigation. A series of standard examinations showed no evidence of structural heart disease, myocarditis, long QT syndrome, or electrolyte imbalance. Idiopathic ventricular tachycardia was suspected.

After obtaining informed consent from his parents, electrophysiologic study was performed in the fasting and sedated state after discontinuation of verapamil for 5 days. Under intravenous sedation and local

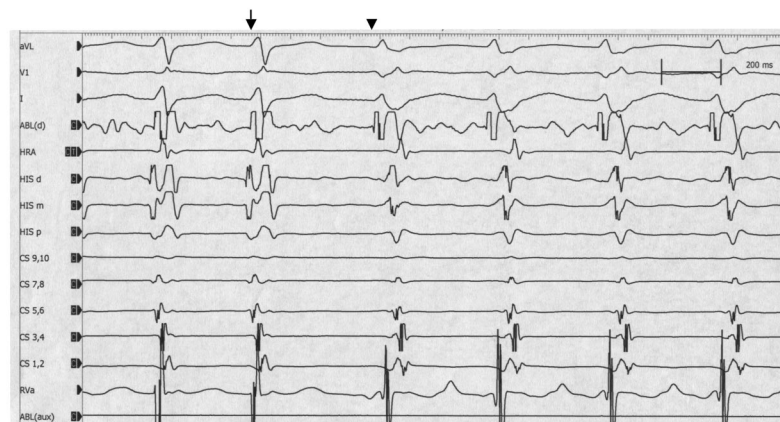
\*Correspondence to: Dr. Ken-Pen Weng, Department of Pediatrics, Kaohsiung Veterans General Hospital, 386, Ta-Chung 1<sup>st</sup> Road, Kaohsiung 813, Taiwan, R.O.C.  
E-mail: kingpw@yam.com • Received: October 12, 2004 • Accepted: February 17, 2005

anesthesia, 3 quadripolar electrode catheters were introduced through the femoral veins and placed in the high right atrium, the His bundle, and the right ventricular apex. An additional decapolar electrode catheter was introduced through the internal jugular vein and placed in the coronary sinus. During sinus rhythm at a cycle length of 593 ms, the atrio-His (AH) and His-ventricular (HV) intervals were normal (71 and 40 ms, respectively). During high right atrium extrastimulation at a basic cycle length of 550 ms, a discontinuous A1A2/A2H2 curve was demonstrated and the effective refractory period of the fast atrio-ventricular nodal (AVN) pathway and slow AVN pathway were 330 and 260 ms, respectively. At baseline, double atrial extrastimuli (S1S2S3 550/330/280) induced the non-sustained slow-fast form of AVNRT (cycle length, 330 ms), which lasted 2 seconds and terminated spontaneously, followed by initiation of sustained ventricular tachycardia (VT) with a QRS morphology identical to the clinically documented

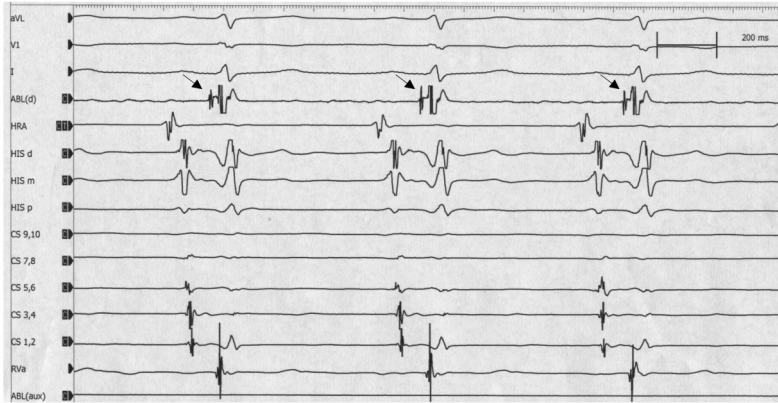
tachycardia at a cycle length of 374 ms (Figure 2). Based on the morphology, the VT was thought to originate from the left posterior fascicle. Pace mapping in this region revealed a relatively large area (3 cm<sup>2</sup>) with similar QRS to the VT. In addition, the earliest Purkinje potential during sinus rhythm was observed in the basal septal area of the left ventricle (Figure 3). Three pulses of radiofrequency energy were delivered to the site exhibiting the earliest Purkinje potential (Figure 4). The VT was terminated within 5 seconds, and no inducible VT was observed at baseline. After ablation of VT, double atrial extrastimuli (S1S2S3 550/340/280) induced the slow-fast form of AVNRT again. Two pulses of radiofrequency energy were delivered to modify the slow pathway successfully (Figure 5). After these ablation procedures, neither VT nor AVNRT was induced with or without isoproterenol infusion. Anti-arrhythmic drugs were then discontinued and he did not experience any further palpitation episodes.



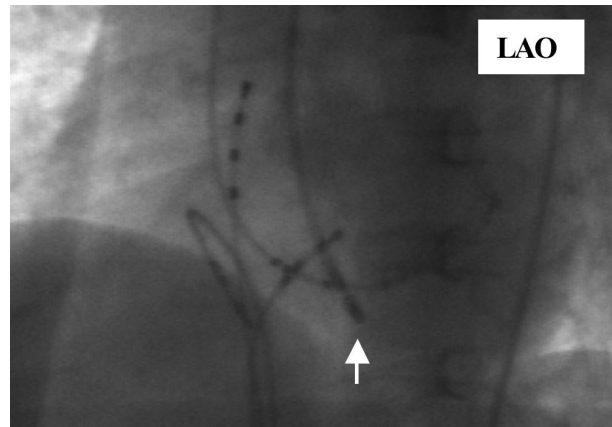
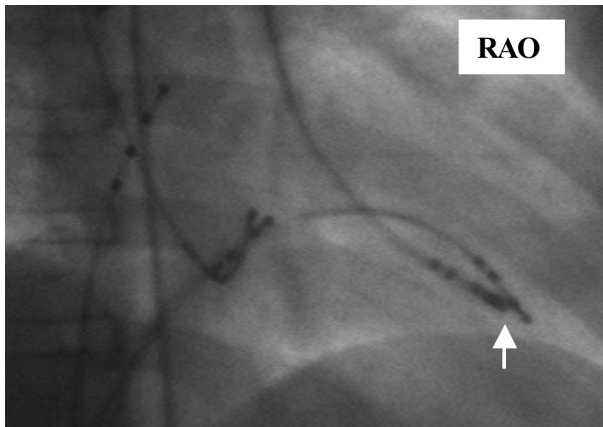
**Figure 1.** A 12-lead electrocardiogram during ventricular tachycardia showing a wide QRS tachycardia with a right bundle branch block and northwest axis QRS morphology at a heart rate of 136 bpm. Paper speed: 25 mm/sec.



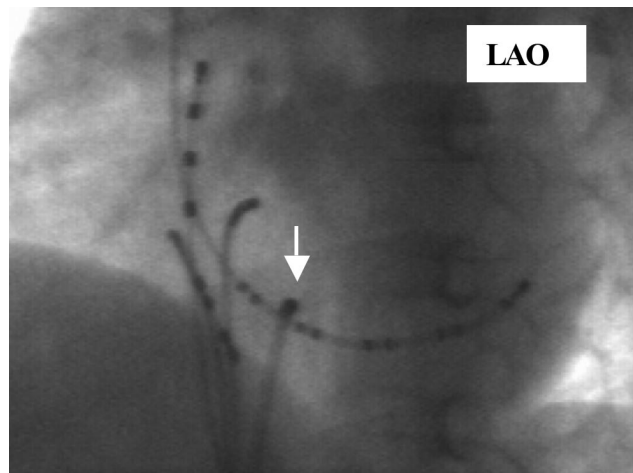
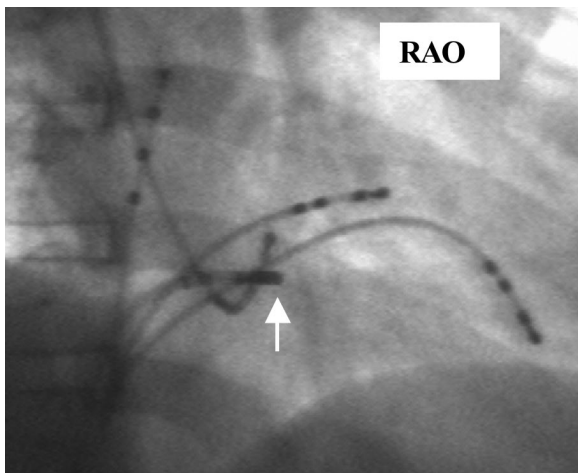
**Figure 2.** Intracardiac recordings showing spontaneous transformation from atrioventricular nodal reentrant tachycardia (AVNRT) to ventricular tachycardia (VT). AVNRT lasted 2 seconds and terminated, followed by initiation of sustained VT from the left ventricle (LV) at a cycle length of 374 ms. Note the interval of the first complex of the VT (arrowhead) and the last QRS complex of the AVNRT (arrow), exceeding by 70 ms the interval present between the same complex during VT. ABL = ablation catheter; HRA = high right atrium; HIS = His bundle; CS = coronary sinus; RVa = right ventricle apex; aux = auxiliary; p = proximal; m = middle; d = distal. Paper speed: 100 mm/sec.



**Figure 3.** Intracardiac recordings at the site of successful ablation. High frequency potentials that represent Purkinje potentials (arrows) are seen from the ablation catheter at the ablation site. During sinus rhythm, this potential precedes surface activation by 30 ms. ABL = ablation catheter; HRA = high right atrium; HIS = His bundle; CS = coronary sinus; RVa = right ventricle apex; aux = auxiliary; p = proximal; m = middle; d = distal. Paper speed: 100 mm/sec.



**Figure 4.** Radiographs in the right anterior oblique (RAO) and left anterior oblique (LAO) views demonstrating the location of the ablation catheter at the successful ablation site, which is in the basal septal area of the left ventricle.



**Figure 5.** Radiographs in the right anterior oblique (RAO) and left anterior oblique (LAO) views demonstrating the location of the ablation catheter at the site of successful slow pathway ablation, which is along the tricuspid annulus at the level of the superior aspect of the coronary sinus ostium.

## Discussion

Double tachycardia is classically defined as the simultaneous occurrence of supraventricular tachycardia and VT (or atrial and junctional tachycardia).<sup>7</sup> This type of arrhythmia has been reported in patients with left ventricular dysfunction or digitalis intoxication.<sup>7-10</sup> Exercise- or catecholamine-induced double tachycardia has also been reported.<sup>11,12</sup> Electrophysiologic studies have permitted an objective assessment of another type of double tachycardia in patients with idiopathic VT.<sup>5,6,13-18</sup> In our case, 2 types of tachycardia were demonstrated during the course of electrophysiologic studies: AVNRT induced at baseline and VT, the same as the clinically documented arrhythmia.

One unique feature of our case is the demonstration of the interrelationships of 2 different types of tachycardia. VT was initiated by termination of AVNRT, which was induced by double atrial stimulation. This could be explained by 2 mechanisms: VT was initiated at the termination of AVNRT in a fashion similar to the induction of VT by atrial stimulation,<sup>19-22</sup> or the double atrial extrastimulation induced both AVNRT and VT, but the latter became manifest only after the former had terminated. In our case, the interval between the first QRS complexes of VT and the last complex of AVNRT exceeded the interval presented between QRS complex during VT by 70 ms. This may support the former explanation. AVNRT also triggered VT shortly after its origin, so that ECG tracings at symptomatic episodes showed only VT.

Experience with radiofrequency catheter ablation of idiopathic VT in pediatric patients is limited, but radiofrequency catheter ablation may be the treatment of choice for symptomatic VT.<sup>23,24</sup> The patient's VT is characteristic of typical ILVT because it occurred in a young patient without cardiac structural abnormality, manifest right bundle branch block and northwest axis deviation, and responded to verapamil.<sup>1-4</sup> In our patient, the use of the earliest Purkinje potential was a useful specific guide to the appropriate ablation site.<sup>25</sup> VT was successfully eliminated by radiofrequency catheter ablation after 3 pulses. Subsequent modification of the slow AVN pathway was also successful. There were no significant complications. During follow-up, the patient has been in normal sinus rhythm.

Data on radiofrequency catheter ablation in patients with double tachycardia are few and inconclusive.<sup>6,13-18</sup> The case most similar to ours was that of Wagshal et al,<sup>6</sup> which involved a 37-year-old man with coexistent AVNRT and ILVT, who only underwent radiofrequency ablation of the slow pathway and

remained asymptomatic without anti-arrhythmic therapy for 8 months. Watanabe et al<sup>14</sup> reported a case with coexistent atrioventricular reciprocating tachycardia (AVRT) and ILVT, in whom clinical VT recurred after initial ablation of AVRT and was successfully ablated 10 months later. Khairy et al<sup>17</sup> described a 27-year-old woman with both AVNRT and VT, in whom VT remained inducible after successful slow-pathway ablation. The other previous reports on this topic were that ablation of both arrhythmic substrates was performed during 1 session, as the other arrhythmia was still inducible after ablation of 1 arrhythmic substrate and it was difficult to exclude the possibility of clinical occurrence of the other arrhythmia.<sup>13,15,16,18</sup> In our patient, AVNRT was easily induced after successful ablation of ILVT. Our data support the strategy of performing ablation of both arrhythmic substrates during 1 session to prevent recurrence of the tachycardia.

In conclusion, we report a rare pediatric patient in whom AVNRT led to the induction of VT. AVNRT was still inducible following successful ablation of ILVT, but was then modified by ablation of the slow pathway. The coexistence of supraventricular tachycardia and VT is diagnostically challenging, especially if a transformation between 2 tachycardias is observed. Accurate diagnosis requires detailed electrophysiologic studies and is the major determinant of successful ablation.

## Acknowledgments

This study was supported by a grant (VGHKS 94-076) from Kaohsiung Veterans General Hospital, Taiwan, R.O.C.

## References

1. Belhassen B, Shapira I, Pelleg A, Copperman I, Kauli N, Laniado S. Idiopathic recurrent sustained ventricular tachycardia responsive to verapamil: an ECG-electrophysiologic entity. *Am Heart J* 1984;108:1034-7.
2. Ohe T, Shimomura K, Aihara N, Kamakura S, Matsuhisa M, Sato I, Nakagawa H, et al. Idiopathic sustained left ventricular tachycardia: clinical and electrophysiologic characteristics. *Circulation* 1988;77:560-8.
3. Wen MS, Yeh SJ, Wang CC, Lin FC, Chen IC, Wu D. Radiofrequency ablation therapy in idiopathic left ventricular tachycardia with no obvious structural heart disease. *Circulation* 1994;89:1690-6.
4. Gaita F, Giustetto C, Leclercq JF, Haissaguerre M, Riccardi R, Libero L, Baralis G, et al. Idiopathic verapamil-responsive left ventricular tachycardia: clinical characteristics and long-term follow-up of 33 patients. *Eur Heart J* 1994;15:1252-60.

5. Belhassen B, Pelleg A, Paredes A, Laniado S. Simultaneous AV nodal reentrant and ventricular tachycardias. *Pacing Clin Electrophysiol* 1984;7:325-31.
6. Wagshal AB, Mittleman RS, Schuger CD, Huang SK. Coincident idiopathic left ventricular tachycardia and atrioventricular nodal reentrant tachycardia: control by radiofrequency catheter ablation of the slow atrioventricular nodal pathway. *Pacing Clin Electrophysiol* 1994;17:386-96.
7. Castellanos A Jr, Azan L, Calvino JM. Simultaneous tachycardias. *Am Heart J* 1960;59:358-73.
8. Halkin H, Kaplinsky E. Simultaneous tachycardias associated with acute myocardial infarction. *Chest* 1971;60:394-6.
9. Jordan RM, McAnulty JH, Ritzmann L. Alternating atrial and ventricular tachycardia. *Br Heart J* 1979;41:734-7.
10. Chowdhry IH, Hariman RJ, Gomes JA, El-Sherif N. Transient digitoxic double tachycardia. *Chest* 1983;83:686-7.
11. Benson DW Jr, Gallagher JJ, Sterba R, Klein GJ, Armstrong BE. Catecholamine induced double tachycardia: case report in a child. *Pacing Clin Electrophysiol* 1980;3:96-103.
12. Eldar M, Belhassen B, Hod H, Schuger CD, Scheinman MM. Exercise-induced double (atrial and ventricular) tachycardia: a report of three cases. *J Am Coll Cardiol* 1989;14:1376-81.
13. Zardini M, Boyle NG, Josephson ME. Coexistent narrow and wide QRS complex tachycardia: an interesting duo. *Pacing Clin Electrophysiol* 1996;19:363-6.
14. Watanabe I, Kunimoto S, Kondo K, Kojima T, Nakai T, Shindo A, Oshikawa N, et al. Radiofrequency catheter ablation of coexistent atrioventricular reciprocating tachycardia and left ventricular tachycardia originating in the left anterior fascicle. *Jpn Circ J* 1999;63:223-7.
15. Cooklin M, McComb JM. Tachycardia induced tachycardia: case report of right ventricular outflow tract tachycardia and AV nodal reentrant tachycardia. *Heart* 1999;81:321-2.
16. Washizuka T, Niwano S, Tsuchida K, Aizawa Y. AV reentrant and idiopathic ventricular double tachycardias: complicated interactions between two tachycardias. *Heart* 1999;81:318-20.
17. Khairy P, Guerra PG, Thibault B, Dubuc M, Roy D, Talajic M. Alternating narrow and wide complex tachycardia. *Pacing Clin Electrophysiol* 2002;25:103-4.
18. Kautzner J, Cihak R, Vancura V, Bytesnik J. Coincidence of idiopathic ventricular outflow tract tachycardia and atrioventricular nodal reentrant tachycardia. *Europace* 2003;5: 215-20.
19. Zipes DP, Foster PR, Troup PJ, Pedersen DH. Atrial induction of ventricular tachycardia: reentry versus triggered automaticity. *Am J Cardiol* 1979;44:1-8.
20. Wellens HJ, Bar FW, Farre J, Ross DL, Wiener I, Vanagt EJ. Initiation and termination of ventricular tachycardia by supraventricular stimuli. Incidence and electrophysiologic determinants as observed during programmed stimulation of the heart. *Am J Cardiol* 1980;46:576-82.
21. Belhassen B, Shapira I, Kauli N, Keren A, Laniado S. Initiation of ventricular tachycardia by supraventricular beats. *Cardiology* 1982;69:203-13.
22. German LD, Packer DL, Bardy GH, Gallagher JJ. Ventricular tachycardia induced by atrial stimulation in patients without symptomatic cardiac disease. *Am J Cardiol* 1983;52: 1202-7.
23. Smeets JL, Rodriguez LM, Timmermans C, Wellens HJ. Radiofrequency catheter ablation of idiopathic ventricular tachycardias in children. *Pacing Clin Electrophysiol* 1997;20: 2068-71.
24. Laohakunakorn P, Paul T, Knick B, Blaufox AD, Long B, Saul JP. Ventricular tachycardia in nonpostoperative pediatric patients: role of radiofrequency catheter ablation. *Pediatr Cardiol* 2003;24:154-60.
25. Nakagawa H, Beckman KJ, McClelland JH, Wang X, Arruda M, Santoro I, Hazlitt HA, et al. Radiofrequency catheter ablation of idiopathic left ventricular tachycardia guided by a Purkinje potential. *Circulation* 1993;88:2607-17.