

Very Large Yolk Sac and Bicornuate Uterus in a Live Birth

Fu-Nan Cho*, Yuen-Yee Kan, San-Nung Chen, Tsung-Lung Yang¹, Pei-Hua Hsu

Department of Obstetrics and Gynecology, and ¹Department of Radiology, Kaohsiung Veterans General Hospital, Kaohsiung, Taiwan, R.O.C.

Pregnancies with a very large yolk sac are generally always associated with poor outcomes. Herein, we present a case in which a very large yolk sac (mean diameter, 8.1 mm) and a bicornuate uterus were shown on transvaginal sonography in the first trimester, but which resulted in a live birth. To our knowledge, this is the largest yolk sac among all cases accompanying live births which have been published in the literature. The unusual enlargement of the yolk sac may be secondary to the compensation effect for the poor blood supply in the medial wall of the bicornuate uterus for the conceptus. To predict the outcome of pregnancy, based on this case report, the quality of the yolk sac might be more important than its size. [*J Chin Med Assoc* 2005;68(11):535–537]

Key Words: bicornuate uterus, live birth, pregnancy outcome, yolk sac

Introduction

Pregnant women who have congenital uterine abnormalities, such as a septate uterus or bicornuate uterus, are inclined to suffer from abortion and preterm delivery. Transvaginal sonography can be used to survey for a yolk sac of abnormal shape or size, which generally results in a poor outcome.^{1–8} The sonographic findings of a relatively large yolk sac in a pregnancy with a bicornuate uterus have not been clearly shown. Here, we present the case of a pregnant woman with a bicornuate uterus in which a very large yolk sac was incidentally noted in the first trimester. Eventually, this case proceeded to term delivery. To our knowledge, the yolk sac in this patient is the largest yolk sac among all cases with good pregnancy outcomes which have been published in the literature.^{1–4,6}

Case Report

A 23-year-old, gravida 3, para 0, woman visited our hospital for prenatal care at 5⁺⁶ weeks of gestation. Her

past history included 2 spontaneous abortions during the first trimester. There was no other history of disease. Transvaginal sonography (Acuson Aspen, Mountain View, CA, USA) showed a gestational sac in the left cavity of a bicornuate uterus (Figure 1), accompanied by a living embryo with a crown–rump length (CRL) of 2.4 mm. Five days later, sonography showed a relatively large yolk sac (mean diameter, 4.4 mm) and a living embryo (CRL, 7 mm) (Figure 2). Over the next 7 days, sonography revealed a normal amniotic cavity, a relatively large yolk sac (mean diameter, 4.8 mm), and a 7⁺¹-week-old embryo (CRL, 10.6 mm). Over the subsequent 2 weeks, sonography showed a very large yolk sac (mean diameter, 8.1 mm) with a living embryo (CRL, 28.7 mm) (Figure 3). The results of the remaining follow-up prenatal care examinations were unremarkable. Rest and limitation of exercise were advised. At 37⁺⁵ weeks of gestation, a grossly normal female baby, weighing 2,480 g, was delivered by cesarean section due to malpresentation. The placenta was located at the medial wall of the left cavity. The bicornuate uterus was confirmed during the operation (Figure 4).

*Correspondence to: Dr. Fu-Nan Cho, Department of Obstetrics and Gynecology, Kaohsiung Veterans General Hospital, 386 Ta-Chung 1st Road, Kaohsiung 813, Taiwan, R.O.C.
E-mail: fncho@isca.vghks.gov.tw • Received: January 14, 2005 • Accepted: June 16, 2005

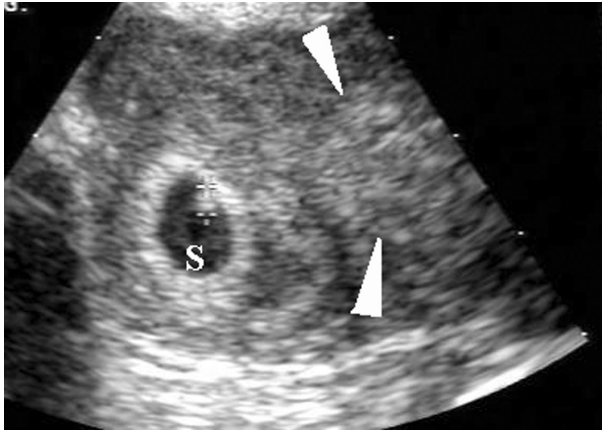


Figure 1. A gestational sac (S) with a living embryo (+) was found in the left cavity of a bicornuate uterus. The decidual change of the endometrium in the right cavity is shown (arrowheads).

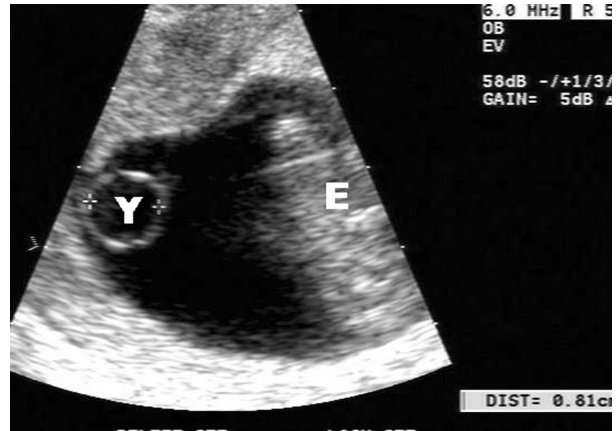


Figure 3. A very large yolk sac (Y) (mean diameter, 8.1 mm) and a living embryo (E) (crown-rump length, 28.7 mm; 167 heartbeats/min) are shown on transvaginal sonography.

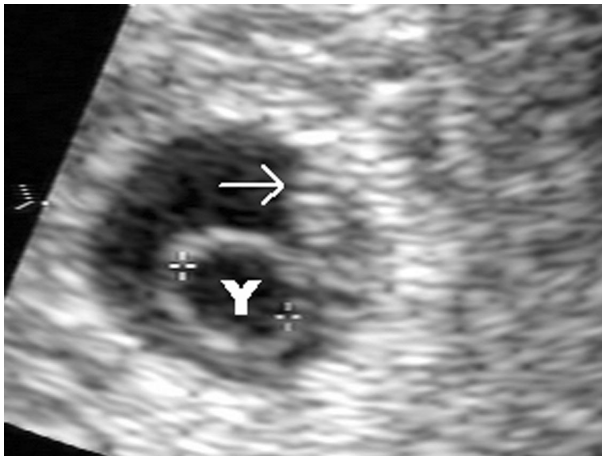


Figure 2. Transvaginal sonography shows a relatively large yolk sac (Y) (mean diameter, 4.4 mm) and a living embryo (arrow) (crown-rump length, 7 mm) in a gestational sac (mean diameter, 10.9 mm).

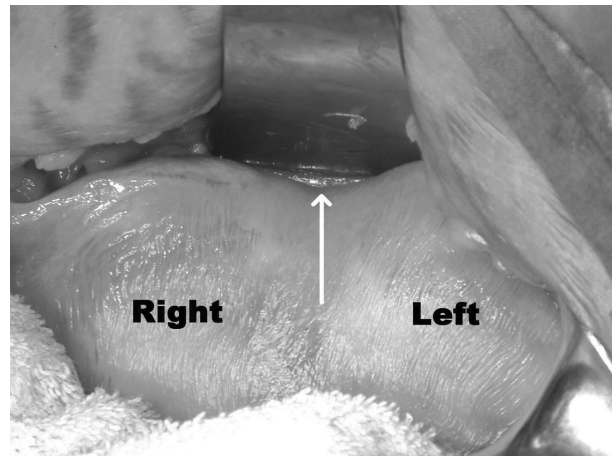


Figure 4. A bicornuate uterus is confirmed (arrow) after the newborn was delivered by cesarean section.

Discussion

In normal pregnancies, the yolk sac progressively increases in size until the 11th week of gestation and then shrinks.^{1-3,6} The shape of the yolk sac is usually nearly spherical. The yolk sac always appears before embryonic heartbeats under transvaginal ultrasound examination. There have been no reports among live-birth pregnancies that a yolk sac could reach 8 mm in mean diameter.^{1-4,6} Yolk sacs with a variety of deformed shapes have been associated with poor pregnancy outcomes.^{1-3,6,8} One previous report tried to predict the possibilities of poor outcomes in cases with relatively large yolk sacs, compared with normal cases.⁶ The important concept derived from the findings in this

case report is that a very large yolk sac, but with a normal shape and normal embryonic heartbeats, should not be hastily identified as an abnormal pregnancy. To predict the outcome in a pregnancy with normal embryonic heartbeats, the quality of the yolk sac might be more important than its size, especially in determining which embryos should be selected during embryo reduction for multiple pregnancies. For cases without positive embryonic heartbeats, the appearance of a relatively large yolk sac is an ominous sign of poor prognosis (anembryonic gestation).

Both genetic and environmental factors may affect the growth patterns of yolk sacs. One study has shown that the anticardiolipin antibodies from patients with systemic lupus erythematosus were able to inhibit the

growth of yolk sacs in rat embryos.⁹ In our case, the genetic effect was excluded on the basis of the normal newborn. We presume that the unusual growth pattern of the yolk sac in our case might be secondary to the compensation effect for the poor blood supply in the medial wall of the bicornuate uterus for the conceptus. Further prospective studies are warranted to determine the growth patterns of yolk sacs in relation to abnormal uterine conditions. Early diagnosis of a bicornuate uterus and meticulous prenatal care will ensure the best results for the pregnancy.

In conclusion, if normal embryonic heartbeats exist, a very large yolk sac should not be mistaken as an ominous sign for poor prognosis, even when it is associated with a bicornuate uterus.

References

1. Kurtz AB, Needleman L, Pennell RG, Baltarowich O, Vilaro M, Goldberg BB. Can detection of the yolk sac in the first trimester be used to predict the outcome of pregnancy? *AJR* 1992;158:843-7.
2. Lindsay DJ, Lovett IS, Lyons EA, Levi CS, Zheng XH, Holt SC, Dashefsky SM. Yolk sac diameter and shape at endovaginal US: predictors of pregnancy outcome in the first trimester. *Radiology* 1992;183:115-8.
3. Stampone C, Nicotra M, Muttinelli C, Cosmi EV. Transvaginal sonography of the yolk sac in normal and abnormal pregnancy. *J Clin Ultrasound* 1996;24:3-9.
4. Rowling SE, Coleman BG, Langer JE, Arger PH, Nisenbaum HL, Horii SC. First-trimester US parameters of failed pregnancy. *Radiology* 1997;203:211-7.
5. Mara E, Foster GS. Spontaneous regression of a yolk sac associated with embryonic death. *J Ultrasound Med* 2000;19:655-6.
6. Kucuk T, Duru NK, Yenen MC, Dede M, Ergun A, Baser I. Yolk sac size and shape as predictors of poor pregnancy outcome. *J Perinat Med* 1999;27:316-20.
7. Schouwink MH, Fong BF, Mol BW, van der Veen F. Ultrasonographic criteria for non-viability of first trimester intra-uterine pregnancy. *Early Pregnancy [Electronic Resource]* 2000;4:203-13.
8. Nyberg DA, Filly RA. Predicting pregnancy failure in 'empty' gestational sacs. *Ultrasound Obstet Gynecol* 2003;21:9-12.
9. Matalon ST, Shoenfeld Y, Blank M, Yacobi S, Blumenfeld Z, Ornoy A. The effects of IgG purified from women with SLE and associated pregnancy loss on rat embryo in culture. *Am J Reprod Immunol* 2002;48:296-304.