

# Endovascular Treatment of Ruptured Vertebral Dissecting Aneurysms with Electrodetachable Coils

Chao-Bao Luo, Cheng-Yen Chang\*, Michael Mu-Huo Teng, Feng-Chi Chang

*Department of Radiology, Taipei Veterans General Hospital and  
National Yang-Ming University School of Medicine, Taipei, Taiwan, R.O.C.*

**Background:** Ruptured intradural vertebral dissecting aneurysm (VDA) is associated with a high risk of rebleeding and a high incidence of mortality if left untreated because of its natural history. We report our experience of endovascular treatment of ruptured VDAs using electrodetachable coils.

**Methods:** Over 7 years, 10 patients with spontaneously ruptured intradural VDAs were managed by endovascular embolization in our institute. All patients received endovascular trapping of the dissecting aneurysm and proximal occlusion by electrodetachable coils.

**Results:** There were 5 men and 5 women, with a mean age of 48 years. Of the 10 VDAs, 8 were located in the supra-posterior inferior cerebellar artery (PICA) area, and 2 were in the infra-PICA area. Six affected vertebral arteries were dominant ( $n = 3$ ) or co-dominant ( $n = 3$ ) in the vertebrobasilar system. Nine ruptured VDAs and their parent arteries were successfully occluded by a single session of endovascular embolization by electrodetachable coils. In the tenth patient, the dissecting aneurysm showed subtotal occlusion because of involvement of the vertebrobasilar junction. The mean number and coil length were 7 and 58 cm, respectively. There were no significant periprocedural complications or recurrent bleeding. All patients demonstrated good clinical recovery ( $n = 9$ ) or improvement ( $n = 1$ ) after embolization over a mean follow-up of 15 months (range, 6–24 months).

**Conclusion:** Endovascular embolization is a useful and safe method in the treatment of ruptured VDAs even when the affected vertebral arteries are dominant or co-dominant in vertebrobasilar flow. Trapping procedures and direct occlusion of the dissecting segment with preservation of the PICA by detachable coils should be performed as early as possible in the management of VDAs. [*J Chin Med Assoc* 2005;68(12):578–584]

**Key Words:** dissecting aneurysm, embolization, vertebral artery

## Introduction

Dissecting aneurysms of the vertebrobasilar system are an uncommon but important cause of nontraumatic subarachnoid hemorrhage (SAH), representing 3% of all intracranial aneurysms,<sup>1,2</sup> and accounting for 28% of vertebral artery aneurysms.<sup>3</sup> These aneurysms are difficult to treat because of their location and morphology. The lack of a defined neck limits the therapeutic options available for endovascular or

surgical occlusion. The deconstructive procedure sacrificing the parent artery from which the aneurysm arises has become a widely accepted approach for treating vertebral dissecting aneurysms (VDAs), but carries a potential risk of ischemic events in the posterior circulation when the vertebral artery is suddenly closed, particularly in patients who have a hypoplastic contralateral vertebral artery. As the majority of VDAs arise distal to the origin of the posterior inferior cerebellar artery (PICA) and are located near the

\*Correspondence to: Dr. Cheng-Yen Chang, Department of Radiology, Taipei Veterans General Hospital, 201, Section 2, Shih-Pai Road, Taipei 112, Taiwan, R.O.C.

E-mail: cmychang@vghtpe.gov.tw • Received: July 20, 2005 • Accepted: October 19, 2005

midline, surgical treatment occasionally becomes difficult and may be associated with serious morbidity.<sup>4,5</sup> The introduction of electrodetachable coils has made it possible to treat aneurysms safely by endovascular means, especially for aneurysms that are less suitable for surgical clipping and in patients with poor clinical condition.<sup>6</sup>

We present our experience of endovascular embolization of spontaneously ruptured VDAs with the trapping technique using electrodetachable coils, and evaluate the periprocedural and follow-up outcome of patients.

## Methods

From August 1998 to February 2005, 216 intradural aneurysms were treated in our institute using electrodetachable coils via an endovascular approach. Of these, 10 patients had spontaneously ruptured VDAs. They were treated within 15 days of the SAH (mean, 6 days). At the time of treatment, 9 patients manifested Hunt and Hess grades 1–3, while 1 patient presented with grade 4.

Since craniotomy with clipping of the VDA is technically challenging due to difficult access, and may be associated with a high rate of lower cranial palsy and respiratory problems, an endovascular approach was selected for treating the ruptured VDAs.<sup>4,5,7</sup> All endovascular procedures were performed under local ( $n = 3$ ) or general ( $n = 7$ ) anesthesia using a femoral approach. Diagnostic, high-magnification and rotational cerebral angiograms were obtained to determine the aneurysm size, shape and location as well as the relationship of the VDA to the PICA. Test occlusion was performed in 3 patients because the affected vertebral artery significantly dominated the blood flow of the vertebrobasilar system (Figure 1A). Endovascular embolization was initiated by introducing a 6F guiding catheter into the affected vertebral artery, followed by navigating a microcatheter to a position just distal to the VDA. Care was taken not to enter the pseudolumen of the aneurysm and rupture the VDA. Occlusion of the aneurysms distal to proximal dissecting sites and small segments of proximal vertebral arteries was performed by selecting the proper soft electrodetachable coils. It is important to adequately embolize the proximal site and keep the nearby PICA patent. When trapping was complete, the microcatheter was carefully pulled out. Trapping was considered to be complete when angiography of the ipsilateral vertebral artery confirmed complete obstruction of the afferent vertebral arterial flow, and angiography

of the contralateral vertebral artery demonstrated cessation of retrograde filling of the VDA (Figures 1 and 2).

At the end of the procedure, systemic anticoagulation was achieved by administering an intravenous continuous injection of an anticoagulative agent to prevent embolic events, and the active coagulation time was maintained at 2 times baseline for 24 hours. All patients were placed under close neurologic evaluation in the intensive care unit for at least 2 days.

## Results

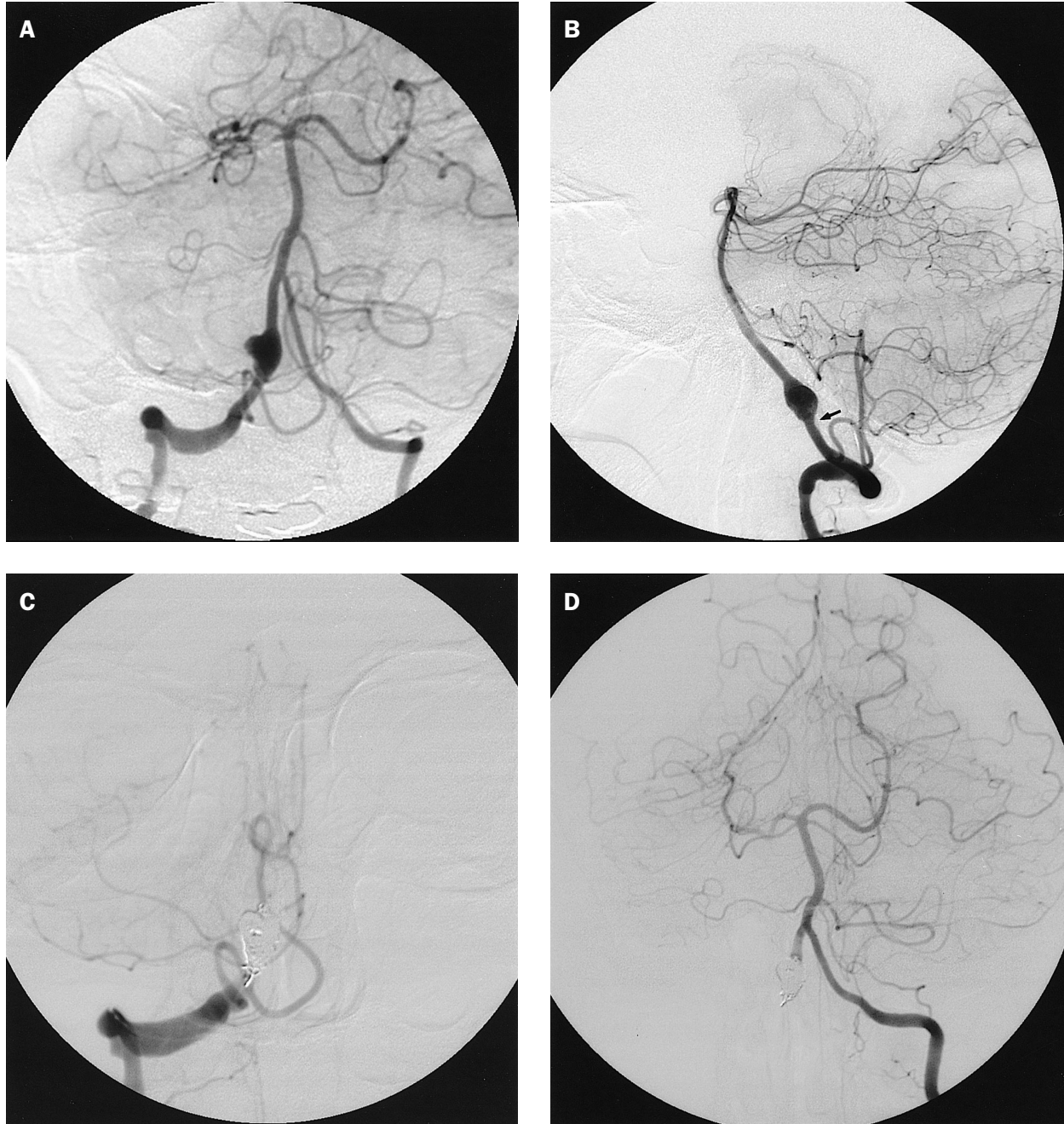
The clinical data of the 10 patients are summarized in Table 1. There were 5 men and 5 women, with a mean age of 48 years (range, 33–61 years). Of the 10 VDAs, 6 were on the right and 4 on the left side; 8 were distal to the PICA (Figure 1) and 2 were proximal to the PICA (Figure 2). One dissecting segment extended upwards to involve the vertebrobasilar junction. In 3 patients, the affected vertebral artery was the dominant flow for the vertebrobasilar system (Figure 1A), while in 3, it was co-dominant with the contralateral vertebral artery (Figure 2A). In the remaining 4 patients, the vertebral artery contralateral to the affected one was dominant. In 9 cases, the endovascular technique consisted of trapping of the dissecting site and a small proximal vertebral artery (Figures 1C and 2C); complete obliteration of the dissecting aneurysm was angiographically confirmed. In 1 patient, the VDA was subtotally occluded because of the potential risk of occluding the basilar artery while coiling the dissecting segment of the vertebrobasilar junction.

No patients showed distal embolism or coil migration. The number of coils used for embolization varied from 4 to 11 (mean, 7), while coil length varied from 20 to 130 cm (mean, 58 cm). One patient experienced temporary impairment of the ipsilateral facial nerve, possibly because of coil mass compression of the facial nerve or compromise of the arterial branch supplying the facial nerve, which resolved completely within 6 months. No significant procedure-related neurologic complication or rebleeding was observed. Nine patients had good clinical recovery, ensuring an independent lifestyle. One patient showed improvement but had residual neurologic deficit after embolization necessitating a dependent lifestyle. All patients were followed-up clinically for a mean of 15 months (range, 6–24 months), while 7 had follow-up angiographies from 7 days to 6 months after embolization.

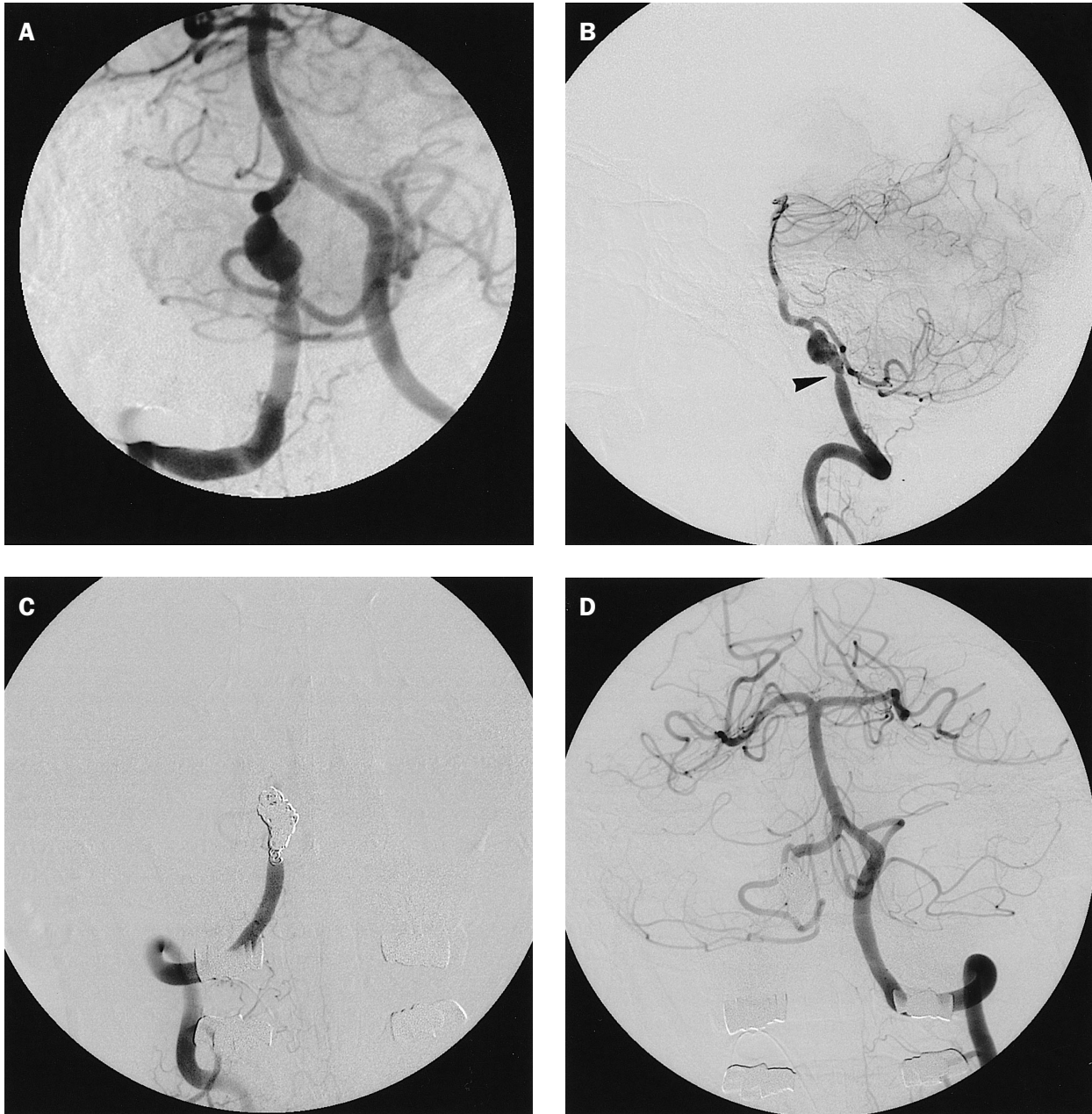
## Discussion

Most VDAs are idiopathic in origin, but a variety of causes have been reported in the literature, including trauma, hypertension, syphilis, fibromuscular dysplasia,

and polyarteritis nodosa.<sup>8</sup> In our series, only 2 patients had a history of hypertension; precise predisposing or precipitating factors were not identified in the other 8 patients. The exact rate of ruptured VDA remains unknown, but it is higher than we expected.



**Figure 1.** A 36-year-old woman presented with grade 1 subarachnoid hemorrhage because of spontaneously ruptured vertebral dissecting aneurysm (VDA). (A, B) Right vertebral angiogram shows a fusiform dilatation of the vertebral artery superior to the origin of the posterior inferior cerebellar artery (PICA), with mild proximal vascular narrowing (arrow). The affected vertebral artery is approximately 2 times the diameter of the contralateral vertebral artery. The patient underwent a balloon occlusion test and could tolerate the test. (C) A total of 6 detachable coils, 46 cm in length, were placed into the dissecting segment and proximal parent artery, resulting in total occlusion of the VDA with preservation of PICA flow. (D) Angiogram of the contralateral vertebral artery showed good opacification of the vertebrobasilar system without retrograde filling of the ruptured VDA.



**Figure 2.** A 36-year-old man presented with grade 3 subarachnoid hemorrhage because of ruptured right vertebral dissecting aneurysm (VDA). (A, B) Right vertebral angiogram shows an infra-posterior inferior cerebellar artery (PICA) VDA with proximal vascular narrowing (arrowhead), with co-dominant bilateral vertebral arteries in the vertebrobasilar system. (C, D) Total occlusion of the dissecting segment and proximal parent artery was achieved with 7 electrodetachable coils, 98 cm in length, and PICA blood flow was well preserved after embolization, with no evidence of retrograde filling of the ruptured VDA on contralateral vertebral artery angiogram.

Histologically, the intradural segment of the vertebral artery has a thin media and adventitia with few elastic fibers, so dissections of the intradural vertebral artery are more likely to result in SAH with pseudoaneurysm compared with dissections of the extradural segment. Reported rates of recurrent hemorrhage for VDAs range from 30% to 70%, with a high estimated mortality rate of 47%.<sup>8,9</sup> Due to high rates of rebleeding, most

reported cases have undergone surgical or endovascular therapy.

In our series, the majority of cases presented with fusiform dilatation with pseudoaneurysm formation in the involved vertebral artery, with varying degrees of proximal vascular narrowing (Figures 1B and 2B). Treatment can be chosen after assessing location, extension and configuration of the dissecting aneurysm,

**Table 1.** Demographics and outcome of endovascular embolization in 10 patients with ruptured vertebral dissecting aneurysms

Patient	Gender	Age (yr)	HH grade	Location/side	Involving dominant VA	BOT	Time to treat (d)	Coil no./length (cm)	Outcome	Follow-up (mo)
1	M	33	4	Supra-PICA/left	No	No	3	10/83	TO with improvement	6
2	M	61	2	Supra-PICA/right	No	No	5	4/28	TO with GR	18
3	F	37	1	Supra-PICA/right	Yes	Yes	15	6/46	TO with GR	7
4	M	49	3	Infra-PICA/left	Yes	Yes	4	11/130	TO with GR	13
5	M	36	3	Infra-PICA/right	No	No	3	7/98	TO with GR	24
6	F	51	2	Supra-PICA/left	No	No	7	7/33	Subtotal occlusion with GR	15
7	M	50	1	Supra-PICA/right	No	No	5	5/20	TO with GR	23
8	F	60	3	Supra-PICA/right	No	No	8	4/30	TO with GR	19
9	F	42	3	Supra-PICA/right	Yes	Yes	3	6/63	TO with GR	12
10	F	61	2	Supra-PICA/left	No	No	10	7/48	TO with GR	17

BOT = balloon occlusion test; GR = good recovery with independent lifestyle; HH = Hunt and Hess; PICA = posterior inferior cerebellar artery; TO = total occlusion; VA = vertebral artery.

adjacent branches, collateral circulation, and time of presentation. Proximal surgical clipping of VDAs has been a widely accepted treatment with effective control of rebleeding, but it may be associated with a high rate of low cranial nerve palsy and long tract signs (25%).<sup>7</sup> With the introduction of the electrodetachable coil, endovascular treatment became safer and more effective because the coil is soft and more easily controlled. Sugiue et al<sup>10</sup> reported 20 VDAs treated by the endovascular approach, with no rebleeding or significant technique-related complications. However, this less invasive modality is not always successful or risk-free. Potential technique-related complications of endovascular embolization include ruptured VDA, occlusion of the side branch of the vertebral artery, and hemodynamic compromise of the vertebrobasilar system due to vertebral artery occlusion.

Several endovascular treatment strategies have been developed for VDAs. Proximal occlusion of the affected vertebral artery, using coils or balloons, is commonly used. The advantage of this technique is that it limits catheter and wire manipulation across a narrow or irregular segment and may allow for better collateral circulation, especially when lesions involve the origin of the PICA or anterior spinal artery. This technique also uses fewer coils, with a lower cost as a result. It should also be considered for lesions with configurations unlikely to hold coils in a stable position. Nevertheless, proximal parent artery occlusion is not believed to completely eliminate the risk of rebleeding. Instances of postoperative rebleeding or enlargement of the aneurysm have been reported.<sup>11-13</sup>

In patients with ruptured VDAs, embolization of the dissecting site by proximal occlusion using detachable coils and preservation of PICA blood flow

are more effective than proximal occlusion alone because the former results in immediate cessation of blood flow to the affected site. This technique needs many coils and therefore has a higher cost. Coil mass may compress the nearby cranial nerve or compromise nearby small branches of the affected vertebral artery, as occurred in 1 patient in our series who had transient ipsilateral facial nerve palsy. In our study, the mean number of coils used and coil length were 7 and 58 cm, respectively, for occlusion of the dissecting segment and proximal vertebral artery. If the lesion extends to the vertebrobasilar junction and/or basilar artery, only a segment may be coiled. This occurred in 1 of our patients (Case 6). If the dissecting segment is directly embolized at the acute stage, there may be a risk of rebleeding caused by the microcatheter or coils because of the fragility of the dissecting site, emboli being dislodged, or occlusion of the side branches. An alternative method in these cases is the trapping procedure using proximal occlusion of the vertebral artery combined with distal occlusion across the vertebrobasilar junction to avoid the affected segments, if the anatomy allows. Kai et al<sup>14</sup> reported 11 patients in whom endovascular coil trapping was performed on both sides of the ruptured VDAs by using double microcatheters in the acute stage without coil impaction to the dissecting segment. These complex techniques require puncture of both femoral arteries or use of a larger guiding catheter to allow the passage of 2 microcatheters to access the target lesion. In our series, all 10 VDAs were treated by traditional and simple methods to occlude the VDAs by navigation of a single guiding catheter and microcatheter. Occlusion of the VDA from the distal to proximal dissecting sites and a small segment of the proximal vertebral artery

was performed by selecting the proper soft electrodetachable coils. Care was taken not to enter the pseudolumen of the VDA and rupture it. It is also important to adequately embolize the proximal site and keep the nearby PICA patent. When trapping was complete, the microcatheter was carefully pulled out. No thromboembolic event or VDA rupture occurred in our series.

In some instances, VDAs may involve the dominant vertebral artery. In such cases, a balloon occlusion test (BOT) is essential to determine the adequacy of collateral circulation from the contralateral vertebral artery or posterior communicating arteries. In our series, BOT was not considered as a standard procedure before embolization. It was only performed in 3 patients with VDAs involving the dominant vertebral artery. The involved vertebral artery was approximately 2 times the diameter of the contralateral vertebral artery (Figure 1A). Although BOT in the vertebrobasilar system is less effective in predicting future ischemia, it can indicate the extent of collateral circulation in the vertebrobasilar system. If patients fail the occlusion test, surgical procedures such as saphenous or radial artery bypass or PICA side-to-side anastomosis are mandatory. Stent-assisted embolization can be an alternative for this surgical procedure to treat wide-neck or dissecting aneurysms.<sup>15,16</sup> The stent is placed across the aneurysmal neck. Detachable coils are then placed in the aneurysm by using a microcatheter positioned within the aneurysmal sac through the stent mesh. The stent keeps the arterial lumen patent while allowing strategic coil placement in the aneurysm to create an artificial aneurysmal neck. The stent not only acts as a barrier, preventing coil herniation, but also keeps the true arterial lumen open. Risks and limitations of this technique have been noted, including the occlusion of perforating arteries, the difficulty of navigating the microcatheter through the stent mesh and visualizing the stent under fluoroscopy, the risk of the coils unraveling, and stent migration. With specific reference to VDAs, this technique may not be the ideal option for aneurysms involving the PICA origin because of the possibility of occlusion of the ostium of the PICA.

In conclusion, the results of our study indicate that endovascular embolization with complete thrombosis for dissecting segment is a good therapeutic option. It is safe and effective even in the acute stage and when the VDA involves the dominant vertebral artery. Trapping procedures with direct occlusion of the dissecting segment using detachable coils with preservation of PICA blood flow should be performed as early as possible in the management of VDA.

The advantages of endovascular treatment include the ability to monitor the neurologic status of an awake patient, particularly in cases where the VDA affects the dominant vertebral arteries, to angiographically assess the adequacy of collateral flow, and to evaluate any residual flow after permanent occlusion.

## Acknowledgments

This article was supported, in part, by the Taipei Veterans General Hospital grant number VGH94-398.

## References

1. Lylyk P, Ceratto R, Hurvitz D, Basso A. Treatment of a vertebral dissecting aneurysm with stents and coils: technique and case report. *Neurosurgery* 1998;43:385–8.
2. Yamaura A, Watanabe Y, Saeki N. Dissecting aneurysms of the intracranial vertebral artery. *J Neurosurg* 1990;72:183–8.
3. Yamaura A. Diagnosis and treatment of vertebral aneurysm. *J Neurosurg* 1988;69:345–9.
4. Andoh T, Shirakami S, Nakashima T, Nishimura Y, Sakai N, Yamada H, Ohkuma A, et al. Clinical analysis of a series of vertebral aneurysm cases. *Neurosurgery* 1992;31:987–93.
5. Yamaura A. Diagnosis and treatment of vertebral aneurysms. *J Neurosurg* 1988;69:345–9.
6. Luo CB, Teng MMH, Chang FC, Lirng JF, Chang CY. Endovascular management of the traumatic cerebral aneurysms associated with traumatic carotid cavernous fistulas. *Am J Neuroradiol* 2004;501–5.
7. Kitanaka C, Sasaki T, Eguchi T, Teraoka A, Nakane M, Hoya K. Intracranial vertebral artery dissections: clinical, radiological features, and surgical considerations. *Neurosurgery* 1994;34:620–7.
8. Rabinov JD, Hellinger FR, Morris PP, Ogilvy CS, Putman CM. Endovascular management of vertebrobasilar dissecting aneurysms. *Am J Neuroradiol* 2003;24:1421–8.
9. Mizutani T, Aruga T, Kirino T, Miki Y, Saito I, Tsuchida T. Recurrent subarachnoid hemorrhage from untreated ruptured vertebrobasilar dissecting aneurysms. *Neurosurgery* 1995;36:905–11.
10. Sugi K, Tokunaga K, Watanabe K, Sasahara W, Ono S, Tamiya T, Date I. Emergent endovascular treatment of ruptured vertebral artery dissecting aneurysms. *Neuroradiology* 2005;47:158–64.
11. Kawamata T, Tanikawa T, Takeshita M, Onda H, Takakura K, Toyoda C. Rebleeding of intracranial dissecting aneurysm in the vertebral artery following proximal clipping. *Neurol Res* 1994;16:141–4.
12. Takai N, Ezuka I, Sorimachi T, Kumagai T, Sano K. Vertebral artery dissecting aneurysm rebleeding after proximal occlusion—case report. *Neurol Med Chir (Tokyo)* 1993;33:765–8.
13. Yasui T, Kishi H, Komiyama M, Iwai Y, Yamanaka K, Nishikawa M, Nakajima H, et al. Rupture mechanism of ruptured intracranial dissecting aneurysm in the vertebral artery following proximal occlusion. *No Shinkei Geka* 2000;28:345–9. [In Japanese]
14. Kai Y, Hamada JI, Morioka M, Todaka T, Mizuno T, Ushio Y. Endovascular coil trapping for ruptured vertebral artery dissecting aneurysms by using double microcatheters technique in the acute stage. *Acta Neurochir (Wien)* 2003;145:447–51.

15. Luo CB, Wei CJ, Chang FC, Teng MMH, Chang CY. Stent-assisted embolization of internal carotid aneurysm. *J Chin Med Assoc* 2003;66:460-6.
16. Mehta B, Burke T, Kole M, Bydon A, Seyfried D, Malik G. Stent-within-a-stent technique for the treatment of dissecting vertebral artery aneurysms. *Am J Neuroradiol* 2003;24:1814-8.