

Klinefelter's Syndrome with Seizure, Pseudohypoparathyroidism Type Ib and Multiple Endocrine Dysfunctions

Chwen-Yi Yang*, Kao-Chang Lin¹, Chien-Wen Chou, Ming-Bin Lin², Su-Yu Chen, Hon-Mei Cheng
Division of Endocrinology and Metabolism, Department of Medicine, and Departments of ¹Neurology and ²Radiology, Chi-Mei Hospital, Tainan, Taiwan, R.O.C.

Klinefelter's syndrome is rarely associated with hypocalcemia, especially pseudohypoparathyroidism (PHP) type Ib. We describe a case of Klinefelter's syndrome associated with seizure, PHP type Ib and multiple endocrine dysfunctions. A 19-year-old Taiwanese male was admitted due to seizures with loss of consciousness. He had been diagnosed with Klinefelter's syndrome with seizure disorder and hypocalcemia 3 months previously. Physical examination revealed eunuchoidism but no osteodystrophy, while laboratory data revealed severe hypocalcemia, hyperphosphatemia, and elevated parathyroid hormone. Chromosomal study showed 47,XXY. Osteoporosis was found on chest and abdominal radiography. Dense calcification in the cerebrum and cerebellum was shown on brain computed tomography and magnetic resonance imaging. Elevation of the patient's serum calcium level was noted after vitamin D and calcium carbonate supplements were given. Klinefelter's syndrome is rarely associated with PHP type Ib; our patient's hypocalcemia improved after long-term aggressive treatment. [*J Chin Med Assoc* 2005;68(12):585–590]

Key Words: endocrine dysfunction, Klinefelter's syndrome, pseudohypoparathyroidism type Ib

Introduction

Klinefelter's syndrome is one of the most common causes of hypogonadism, affecting 1 in 500 males. Two-thirds of affected individuals have a chromosomal karyotype of 47,XXY, while the remainder have variant and mosaic karyotypes. These men have androgen deficiency and impaired spermatogenesis due to testicular abnormalities.^{1–3} Biopsy of the testes would show progressive hyalinization and fibrosis of the seminiferous tubules. The pituitary–gonadal system appears to function well until puberty, and then begins to show signs of change; gonadotropins are overproduced. In some patients with Klinefelter's syndrome, the levels of follicle-stimulating hormone (FSH) and luteinizing hormone (LH) are up to 5 times higher than normal. Testicular failure occurs before puberty; testosterone levels are low and normal pubertal changes do not occur. The characteristic

features of eunuchoidism develop, including abnormally long limbs, absent facial, body and pubic hair, decreased muscle mass, gynecomastia, feminine distribution of adipose tissue, diminished libido, and small testes and penis.^{1–3} Most of these changes occur during mid-to-late puberty.

Clinical presentation is varied. Elevated gonadotropin levels, small testes, and impaired spermatogenesis are constant features. Gynecomastia, decreased facial and pubic hair, and low testosterone levels occur with less frequency.^{1–3} Klinefelter's syndrome is associated with osteoporosis, autoimmune syndrome, endocrine disorders (diabetes mellitus, thyroid disease, hypogonadism), cancer, mental retardation, and psychiatric disturbances.² Klinefelter's syndrome is rarely associated with hypocalcemia, especially pseudohypoparathyroidism (PHP) type Ib. We describe a case of Klinefelter's syndrome associated with seizure, PHP type Ib and multiple endocrine dysfunctions.

*Correspondence to: Dr. Chwen-Yi Yang, Division of Endocrinology and Metabolism, Department of Medicine, Chi-Mei Hospital, 901, Chung-Hwa Road, Yung-Kang City, Tainan 710, Taiwan, R.O.C.
E-mail: fu9109@ms42.hinet.net • Received: December 20, 2004 • Accepted: July 7, 2005

Case Report

A 19-year-old Taiwanese male with a 5-year history of syncope was admitted in August 2004 due to seizures with loss of consciousness. He was a senior high school student who performed poorly in school. The episodes of syncope generally persisted for 5 seconds to several minutes, with mild chest tightness, palpitations, nausea, headache, and eyes turned upward. They occurred at a frequency of several times a day to once in several months. He had previously visited a medical center for help without obtaining a definitive diagnosis. Electrocardiography (ECG) and 24-hour Holter ECG monitoring showed nonspecific findings.

The patient was first admitted to our neurologic section in May 2004 due to seizures. Laboratory data showed severe hypocalcemia (5.8 mg/dL; normal, 8.4–10.2 mg/dL), high serum phosphorus (6.7 mg/dL; normal, 2.3–4.7 mg/dL), normal serum albumin (4.9 g/dL; normal, 3.8–5.3 g/dL), and high intact parathyroid hormone (PTH) (250 pg/mL; normal, 10–60 pg/mL). Neck sonography showed a normal thyroid gland (Figure 1). Brain computed tomography (CT) and magnetic resonance imaging (MRI) revealed dense calcification in the cerebrum and cerebellum (Figures 2 and 3). An endocrinologist was consulted.

Chromosomal study revealed that the patient had a karyotype of 47,XXY (Figure 4). Vitamin D (Rocaltrol[®], Roche, Basel, Switzerland) 0.25 µg/day and calcium carbonate 1,000 mg twice daily were given to raise the calcium level, and phenytoin 100 mg 3 times daily was given to control seizures. After 2 weeks of hospitalization, the patient was discharged in good condition. Despite aggressive treatment to correct the calcium deficit, hypocalcemia and hyperphosphatemia persisted. The patient continued to have occasional seizure episodes.

In August 2004, he was again admitted due to seizures, with loss of consciousness. Physical examination revealed a tall and thin male (height, 178 cm; weight, 60 kg; body mass index, 18.9), with the characteristic features of eunuchoidism, including abnormally long limbs (width of open arms from finger tip to finger tip, 185 cm; lower/upper body ratio, 102/76 cm), absent facial, body and pubic hair, decreased muscle mass, mild gynecomastia, feminine distribution of adipose tissue, and small testes and penis. No osteodystrophy was found in his extremities.

Hematologic investigation showed mild anemia with a hemoglobin level of 13.1 g/dL (normal, 13.5–17.5 g/dL) and hypereosinophilia, with a total eosinophil count of 759/µL (normal, < 350/µL).

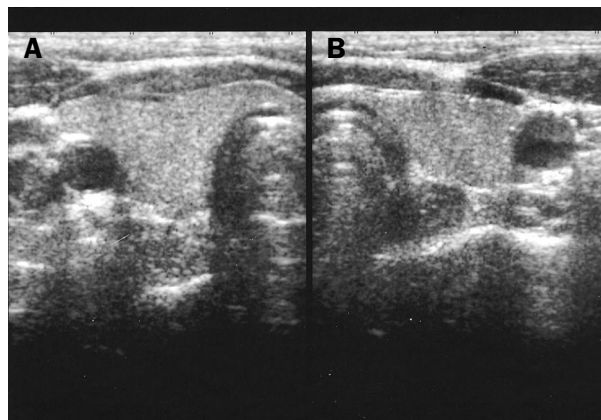


Figure 1. (A, B) Thyroid gland with normal size and echopattern is shown on neck sonography; there are no focal nodules. No obvious hypoechoic nodules are seen posterior to the thyroid gland.

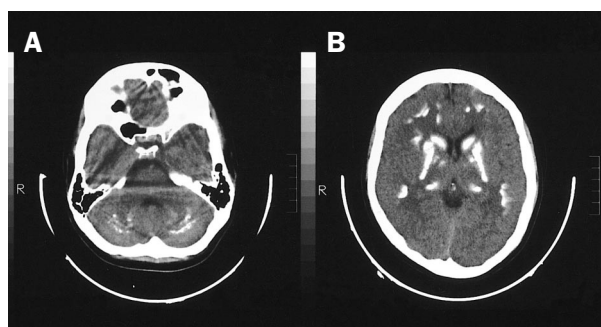


Figure 2. Computed tomography of the brain shows dense calcification in the bilateral putamen, caudate head, thalamus, cerebellar dentate nucleus and along bilateral frontoparietal gray white matter junctions without midline shift. (A) Without contrast enhancement; (B) with contrast enhancement.

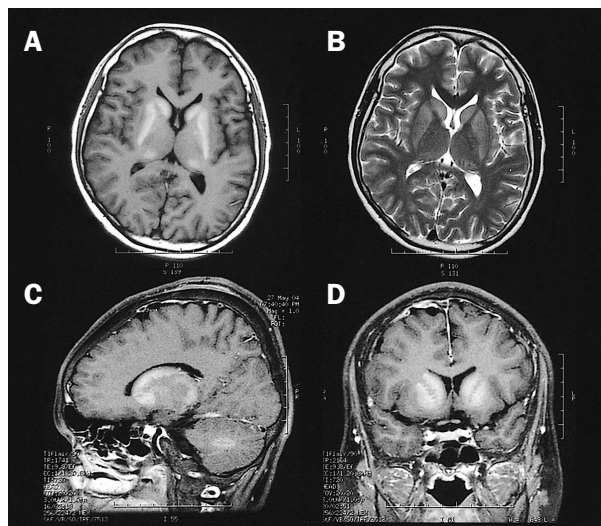


Figure 3. Magnetic resonance imaging of the brain shows exaggerated intracranial calcification in the bilateral putamen, caudate head, and thalamus. (A) Axial view without intravenous Gd-DTPA enhancement; (B) axial view with intravenous Gd-DTPA enhancement; (C) sagittal view; (D) coronal view.

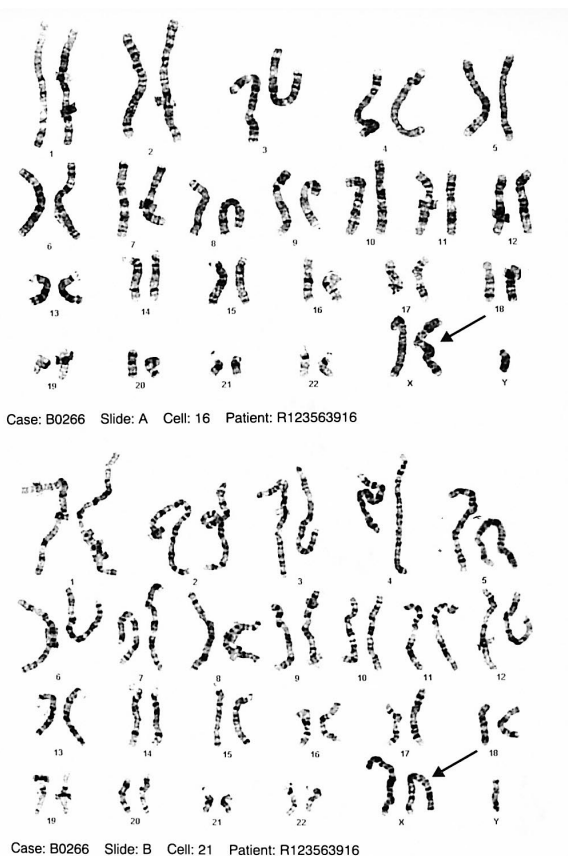


Figure 4. The patient had a 47,XXY karyotype.

Biochemical studies revealed normal fasting blood glucose (95 mg/dL; normal, 70–110 mg/dL), low serum potassium (2.9 mmol/L; normal, 3.5–5.0 mmol/L), low serum calcium (5.4 mg/dL; normal, 8.4–10.2 mg/dL), and high serum phosphorus (7.2 mg/dL; normal, 2.3–4.7 mg/dL).

Endocrinologic data showed mild subclinical hypothyroidism with normal antimicrosomal antibody (AMiA, TPO Ab) titer (< 100; normal titer, < 100), normal antithyroglobulin (ATA) titer (< 100; normal titer, < 100), normal triiodothyronine (112 ng/dL; normal, 80–170 ng/dL), normal thyroxine (7.1 µg/dL; normal, 4.5–12.5 µg/dL), high thyroid-stimulating hormone (TSH) (5.9 µIU/mL; normal, 0.2–4.0 µIU/mL), subclinical adrenal insufficiency with low 8 AM cortisol (5.3 µg/dL; normal, 6–23 µg/dL), normal 4 PM cortisol (8.2 µg/dL; normal, 3–14 µg/dL), elevated adrenocorticotropic hormone (ACTH) (55.8 pg/mL; normal, 9–52 pg/mL), hypergonadotropic hypogonadism with high FSH (23 mIU/mL; normal, 1.4–1.8 mIU/mL), high LH (12.7 mIU/mL; normal for male < 70 years of age, 1.5–9.3 mIU/mL), low testosterone (129 ng/dL;

normal, 241–827 ng/dL), elevated PTH with PTH-C (C-terminal) (1.43 ng/mL; normal, 0.4–1.4 ng/mL), and very high intact PTH (191.9 pg/mL; normal, 14–72 pg/mL) and PTH-MM (mid-portion) (126 pmol/L; normal, 40–100 pmol/L).

Chest and abdominal radiography (Figure 5) and dual-energy X-ray absorptiometry (Figure 6) revealed osteoporotic changes in the bones. Skull sella views were negative. Follow-up brain CT and MRI revealed exaggerated intracranial calcification. The Mini-Mental State Examination (MMSE) and electroencephalography indicated mild cortical dysfunction.

The patient was diagnosed with Klinefelter's syndrome (47,XXY) with seizures, PHP type Ib (hypocalcemia, hyperphosphatemia, elevated parathyroid hormone) and multiple endocrine dysfunctions (hypergonadotropic hypogonadism, subclinical hypothyroidism, subclinical adrenal insufficiency). We increased the dosage of vitamin D from 0.25 µg to 0.5 µg daily, and the calcium carbonate dose from 1,000 mg twice daily to 1,000 mg 4 times daily. Testosterone replacement therapy was initiated with testosterone enanthate (Testenan depot, Sinton Ltd, Sin-Chu City, Taiwan) 250 mg twice monthly.

Follow-up outpatient data showed improved hypocalcemia and hyperphosphatemia. After 10 months of treatment from May 1, 2004 to March 3, 2005, the patient's serum calcium level had increased from 5.8 mg/dL to 7.5 mg/dL, and the serum phosphorus level had decreased from 6.7 mg/dL to 6.4 mg/dL. However, mild subclinical hypothyroidism and mild adrenal insufficiency persisted (triiodothyronine, 129.7 ng/dL; thyroxine, 6.2 µg/dL; TSH, 4.2 µIU/mL; random cortisol, 2.9 µg/dL).

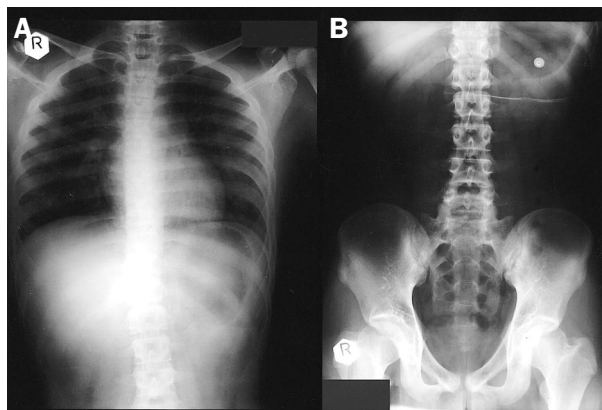


Figure 5. (A) Chest film obtained in the standing position shows no definite bony fracture, normal heart size, and no active lung lesions, but osteoporotic change is seen. (B) Abdominal film obtained in the supine position revealed no pathologic calcification, normal intestinal gas pattern, and normal pelvic fat lines, but osteoporotic change is seen.

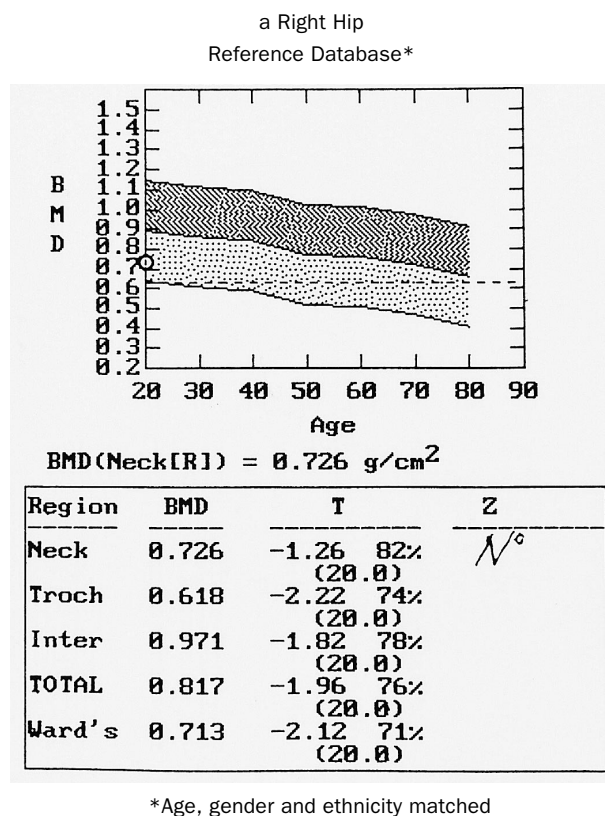


Figure 6. Proximal femoral bone mineral density (BMD) as measured by dual-energy X-ray absorptiometry revealed that the BMD of the proximal femoral at the neck, trochanter, inter, total and ward's regions were 0.726, 0.618, 0.971, 0.818, and 0.713 g/cm², respectively. The overall BMD of the neck was 0.726 g/cm², which is about -1.26 T-score compared with normal young peak bone mass and no z-score in comparison with similar age-, gender-, and ethnicity-matched controls. Grade I osteoporosis was diagnosed.

Discussion

Both PTH and 1,25(OH)₂D function to maintain normal serum calcium levels and are central to preventing hypocalcemia. The causes of hypocalcemia can be classified into: (1) hypoparathyroidism; (2) resistance to PTH action; (3) failure to produce 1,25(OH)₂D normally; (4) resistance to 1,25(OH)₂D; and (5) acute complexation or deposition of calcium.⁴ Most of the signs and symptoms of hypocalcemia occur because of increased neuromuscular excitability (tetany, paresthesia, seizure, organic brain syndrome) or because of calcium deposition in soft tissues (cataract, calcification of basal ganglia).^{4,5} Our patient's laboratory data revealed intractable hypocalcemia and hyperphosphatemia, while brain CT and MRI showed

exaggerated intracranial calcification (including basal ganglia); he had seizures and loss of consciousness, which were compatible with the signs and symptoms of hypocalcemia.

PHP is a heritable disorder of target-organ unresponsiveness to PTH. Biochemically, it mimics hormone-deficient forms of hypoparathyroidism with hypocalcemia and hyperphosphatemia, but the PTH level is elevated and there is a markedly blunted response to the administration of PTH in PHP. To confirm that resistance to PTH is present, the patient is challenged with PTH (the Ellsworth-Howard test).^{4,5}

Several distinct forms of PHP are recognized, including PHP types Ia, Ib, Ic, II, and pseudo-PHP.⁵ PHP type Ia is caused by the loss of 1 functional allele of the gene encoding the G protein subunit G_sα, which leads to a 50% deficiency in the heterotrimer G_s, which couples the PTH receptor to adenylyl cyclase. The mutation results in generalized disorder of hormonal unresponsiveness. PHP type Ia is inherited as an autosomal dominant trait. Primary hypothyroidism and abnormalities of reproductive function commonly occur, indicating that resistance to TSH, glucagon and gonadotropins are commonly present, but the response to ACTH is fairly normal. The G_s mutation invariably produces Albright's hereditary osteodystrophy (AHO), which consists of short stature, round face, short neck, brachydactyly, shortening of the fourth and fifth metacarpals, and subcutaneous ossifications.

PHP type Ib is a disorder of isolated resistance to PTH but with no somatic phenotype (AHO), which presents with the biochemical features of hypocalcemia, hyperphosphatemia and secondary hyperparathyroidism. G_s is normal in PHP type Ib. The locus responsible for PHP Ib resides on chromosome 20q13.3, the same region that contains the *GNAS1* gene, encoding G_sα.⁵ The pattern of disease inheritance appears to be characteristic of PHP Ia, but mapping studies suggest that the mutations are close to but distinct from the G_sα-encoding region.^{4,5} Our patient had biochemical features of hypocalcemia, hyperphosphatemia, and high PTH, but with no AHO, which is compatible with PHP type Ib. He also had multiple endocrine dysfunctions with hypergonadotropic hypogonadism, subclinical hypothyroidism, and subclinical adrenal insufficiency, which are not compatible with PHP type Ib but are associated with Klinefelter's syndrome.

Klinefelter's syndrome is associated with many conditions. These include osteoporosis, because androgen deficiency is a major risk factor for osteoporosis (androgen stimulates osteoid formation

and bone mineralization). Up to 50% of patients with Klinefelter's syndrome have bone mineral densities that are 12–15% lower than normal.² Autoimmune diseases, especially systemic lupus erythematosus and rheumatoid arthritis, are also associated with Klinefelter's syndrome.⁶ Their pathogenic mechanism is unclear but may be related to testosterone and estrogen levels. Androgens are generally believed to protect against estrogen-facilitated autoimmunity. It seems more likely that autoimmunity is directly related to the extra X chromosome. Additionally, other endocrine disorders are associated with Klinefelter's syndrome.^{7,8} The incidence of diabetes mellitus is higher than normal among patients with Klinefelter's syndrome: 8% of patients are symptomatic, while 29% have impaired glucose tolerance. The underlying mechanism for this is unknown; severely reduced insulin sensitivity and insulin resistance have been proposed.⁷ There are diminished thyroid hormone reserves, but a definite connection between Klinefelter's syndrome and hypothyroidism is lacking.² Graves' disease has also been reported to be associated with Klinefelter's syndrome, and an autoimmune mechanism was considered.⁹ Usually, the patient's adrenal gland function is normal. Our patient had normal blood glucose, normal thyroid antibody titer, and normal thyroid sonography picture, but he had mild subclinical hypothyroidism and subclinical adrenal insufficiency. The causes of the hypothyroidism and adrenal insufficiency remain unknown. We did not give our patient any levothyroxine or steroid supplement. Long-term follow-up is mandatory.

Breast cancer is 20 times more frequent among men with Klinefelter's syndrome (it typically represents only 0.5% of all cancers in men).² Patients have gynecomastia, which may predispose to malignancy. Extragonadal germ cell tumors are also more frequent. Malignant transformation of germ cells is presumably related to the persistent elevation of gonadotropin levels.^{10,11} Mental retardation is common among men and boys with Klinefelter's syndrome.² The prevalence of Klinefelter's syndrome in mental and penal institutions is 1%.² Patients with Klinefelter's syndrome are predisposed to criminal behavior. Boys with an extra X chromosome tend to perform poorly in school, have low verbal scores, poor short-term auditory memory, poor data retrieval skills, delayed or diminished speech and language skills, or dyslexia.

Patients with Klinefelter's syndrome are prone to psychiatric disturbances ranging from anxiety, neurosis, depression, and lack of self-esteem to feelings of insecurity.² Patients with 48,XXXY or 49,XXXXY

karyotypes have greater difficulties than those with 47,XXY karyotypes, suggesting a correlation with the supernumerary X chromosomes rather than with androgen levels. Our patient had poor performance in school, low-to-moderate intelligence, osteoporosis, and multiple endocrine disorders compatible with some conditions of Klinefelter's syndrome. He is at risk of developing autoimmune disease or cancer, so long-term follow-up is, thus, required.

Klinefelter's syndrome is also associated with mixed connective tissue disease,¹² Rathke's cleft cyst,¹³ mediastinal polyembryoma,¹⁴ hematologic malignancies,¹⁵ seizures,¹⁶ and striatocapsular infarct.¹⁷ Klinefelter's syndrome is rarely associated with hypocalcemia. Sulimani¹⁸ described a case of Klinefelter's syndrome with PHP in a Saudi patient, while Pongvarin and Viriyavejakul¹⁹ described a case of myotonia congenita, Klinefelter's syndrome and primary hypoparathyroidism. The relationship between Klinefelter's syndrome and PHP remains unknown.

The treatment of Klinefelter's syndrome begins with testosterone replacement therapy at 11–12 years of age. The most widely used form of therapy is an intramuscular preparation of testosterone enanthate or testosterone cypionate; the typical dose is 200 mg twice monthly. When initiated during puberty, the dose is lower: 50–100 mg every 4 weeks, then, every 2 weeks until adulthood. A transdermal testosterone patch can be applied to other areas of the body and the scrotal surface, but is more expensive and has not been evaluated in patients younger than 18 years of age.²⁰ Intracytoplasmic sperm injection of testicular spermatozoa obtained from men with Klinefelter's syndrome has resulted in several deliveries.²¹

The benefits of testosterone replacement therapy include increased facial and pubic hair, a more masculine deposition of body fat, increased strength, and increased libido. Testicular size, gynecomastia, and sterility are not affected.²⁰ Our patient received testosterone enanthate 250 mg twice a week (although he began therapy late); he requires long-term follow-up to assess the benefits of therapy.

Oral calcium and 1 α -hydroxylated vitamin D metabolites remain the mainstay of treatment of PHP.^{4,5} PTH has been used experimentally for the treatment of hypoparathyroidism but is not proven for therapy. Monitoring of serum and urinary calcium levels should be performed as in the treatment of vitamin D deficiency. Therapy in these patients is lifelong. The objective of chronic therapy is to maintain serum calcium in the low-normal range (approximately 8.5–9.2 mg/dL) without causing frank hypercalciuria,⁴

but difficulties in attaining these therapeutic goals are often encountered. Oral calcium can be given as a dose of 1.5–3 g of elemental calcium per day. Short-acting vitamin D (calcitriol) and very long-acting vitamin D₂ (ergocalciferol) are available.⁴ Our patient received synthetic calcitriol 0.5 µg/day and calcium carbonate 4,000 mg (1.6 g elemental calcium) per day; after 10 months of treatment, his serum calcium level had elevated to 7.5 mg/dL (from 5.8 mg/dL). Long-term treatment is needed to correct the patient's serum calcium level.

In conclusion, Klinefelter's syndrome is rarely associated with PHP type Ib. Our patient had improved hypocalcemia after long-term aggressive treatment with vitamin D and calcium supplementation.

References

- Amory JK, Anawalt BD, Paulsen CA, Bremner WJ. Klinefelter's syndrome. *Lancet* 2000;356:333–5.
- Smyth CM, Bremner WJ. Klinefelter syndrome. *Arch Intern Med* 1998;158:1309–14.
- Paulsen CA, Gordan DL, Carpenter RW, Gandy HM, Drucker WD. Klinefelter's syndrome and its variant: a hormonal and chromosomal study. *Recent Prog Horm Res* 1968;24:321–63.
- Shoback D, Marcus R, Bikle D, Strewler G. Mineral metabolism and metabolic bone disease. In: Greenspan FS, Gardner DG, eds. *Basic and Clinical Endocrinology*, 6th edition. New York: McGraw-Hill, 2001:273–333.
- Bringhurst FR, Demay MB, Kronenberg HM. Hormones and disorders of mineral metabolism. In: Larsen PR, Kronenberg HM, Melmed S, Polonsky KS, eds, *Williams Textbook of Endocrinology*, 10th edition. Philadelphia: WB Saunders, 2003: 1303–71.
- Kobayashi S, Yamamoto S, Tanaka M, Hashimoto H, Hirose S. Klinefelter's syndrome and rheumatoid arthritis: report of a case and review of literature. *Clin Rheumatol* 1994;13:500–3.
- Ota K, Suehiro T, Ikeda Y, Arai K, Kumon Y, Hashimoto K. Diabetes mellitus associated with Klinefelter's syndrome: a case report and review in Japan. *Intern Med* 2002;41:842–7.
- Tojo K, Kaguchi Y, Tokudome G, Kawamura T, Abe A, Sakai O. 47,XXY/46,XY mosaic Klinefelter's syndrome presenting with multiple endocrine abnormalities. *Intern Med* 1996;35: 396–402.
- Park JS, Kim CS, Nam JY, Kim DM, Yoon SJ, Ahn CW, Cha BS, et al. Graves' disease associated with Klinefelter's syndrome. *Yonsei Med J* 2004;45:341–4.
- Prall JA, McGavran L, Greffe BS, Partington MD. Intracranial malignant germ cell tumor with Klinefelter's syndrome: case report and review of the literature. *Pediatr Neurosurg* 1995; 23:219–24.
- Kaido T, Sasaoka Y, Hashimoto H, Taira K. *De novo* germinoma in the brain in association with Klinefelter's syndrome: a case report. *Surg Neurol* 2003;60:553–8.
- Takeuchi Y, Murata Y, Sintani J, Masukawa H, Nakamura R, Oi K, Kato Y, et al. Klinefelter's syndrome accompanied by mixed connective tissue disease and diabetes mellitus. *Intern Med* 1999;38:875–81.
- Gotoh M, Nakano J, Midorikawa S, Niimura S, Ono Y, Mizuno K. Multiple endocrine disorders and Rathke's cleft cyst with Klinefelter's syndrome: a case report. *Endocr J* 2002; 49:523–9.
- Beresford L, Fernandez CV, Cummings E, Sanderson S, Ming-Yu W, Giacomantonio M. Mediastinal polyembryoma associated with Klinefelter syndrome. *J Pediatr Hematol Oncol* 2003;25: 321–3.
- Keung YK, Buss D, Chauvenet A, Pettenati M. Hematologic malignancies and Klinefelter syndrome: a chance association? *Cancer Genet Cytogenet* 2002;139:9–13.
- Tatum WO 4th, Passaro EA, Elia M, Guerrini R, Gieron M, Genton P. Seizures in Klinefelter's syndrome. *Pediatr Neurol* 1998;19:275–8.
- Perla C, Sanchez R, Alfaro A, Gilsanz A, Dominguez F. Striatocapsular infarct in a young patient with heterozygous familial hypercholesterolemia and Klinefelter's syndrome. *Medicina Clinica* 1993;101:746–9.
- Sulimani RA. Pseudohypoparathyroidism in a Saudi patient with Klinefelter's syndrome: case report. *East Afr Med J* 1998; 75:252–3.
- Poungvarin N, Viriyavejakul A. Myotonia congenita, Klinefelter syndrome and primary hypoparathyroidism: the first report of the unusual combination of three rare diseases in the literature. *J Med Assoc Thai* 1991;74:172–5.
- Bagatell CJ, Bremner WJ. Androgen in men—uses and abuses. *N Engl J Med* 1996;334:707–14.
- Palermo GD, Schlegel PN, Sills ES, Veeck LL, Zaninovic N, Menendez S, Rosenwaks Z. Births after intracytoplasmic injection of sperm obtained by testicular extraction from men with nonmosaic Klinefelter's syndrome. *N Engl J Med* 1998; 338:588–90.