

Endovascular Treatment of Intracranial High-flow Arteriovenous Fistulas by Guglielmi Detachable Coils

Chao-Bao Luo*, Michael Mu-Huo Teng, Feng-Chi Chang, Cheng-Yen Chang

Department of Radiology, Taipei Veterans General Hospital and National Yang-Ming University School of Medicine, Taipei, Taiwan, R.O.C.

Background: This study reports our experience in performing transarterial Guglielmi detachable coil (GDC) embolization for intracranial high-flow arteriovenous fistulas (AVFs) and evaluates its efficacy and safety.

Methods: Over 3 years, 13 patients with 14 intracranial high-flow AVFs had been managed by transarterial GDC embolization in our institution. There were 6 men and 7 women, with a mean age of 27 years. Of these 14 AVFs, 8 were traumatic carotid-cavernous fistulas (TCCFs); 5 were AVFs at the frontal, temporal, parieto-occipital lobes, or associated with arteriovenous malformation ($n = 3$); 1 was a tentorium AVF.

Results: All of these high-flow AVFs were successfully occluded by a single session of transarterial GDC embolization. In 8 patients with TCCFs, the nearby parent arteries were preserved. The average number of coils was 8 and the average length was 126 cm. All AVF-related symptoms resolved immediately or gradually on clinical follow-up. No significant procedure-related neurologic complication or recurrent AVF was seen. All 13 patients were followed up clinically for an average of 16 months (range, 6–25 months).

Conclusion: Transarterial GDC embolization is a useful method in the treatment of intracranial high-flow AVFs. GDC affords more control in the placement of coils and proved both efficient and safe in the management of intracranial high-flow AVFs. [*J Chin Med Assoc* 2006;69(2):80–85]

Key Words: embolization, Guglielmi detachable coil, intracranial arteriovenous fistula

Introduction

Intracranial arteriovenous fistulas (AVFs) are relatively rare, occurring at different sites of the intracranium, with variable shunt volume. The fistula is classified as low or high flow depending on the size of the shunt and the steal phenomenon.^{1–4} In most cases, it is a single fistula with a large shunt having a short and direct route, and the blood flow is high and rapid with a moderate to severe steal phenomenon because of the large pressure gradient between the arterial and venous systems. A fistula may occur spontaneously or as the result of trauma. Sequelae of intracranial AVFs include an arterial steal phenomenon with cerebral hypoperfusion, and increased flow in cerebral veins resulting in intracranial venous congestion or

hemorrhage, headache, bruit, tinnitus, or vertigo. AVF involving the cavernous sinus may cause bruit, proptosis, chemosis, and symptoms referable to cranial nerves. Treatment of AVF is selective occlusion of the fistula proper. Endovascular treatment has become the therapy of choice for most cases. Various endovascular approaches and embolic materials can be used. High-flow fistulas have commonly been treated with a detachable balloon via the transarterial route.^{1,2,5} Since the introduction of the Guglielmi detachable coil (GDC) (Boston Scientific Corporation, Fremont, CA, USA), there has been great interest in its use as a tool for the treatment of intracranial aneurysm.^{6,7} Little has been written about the application of this device to other cerebrovascular pathologies and only case reports or small series have been reported.^{4,8–10}

*Correspondence to: Dr. Chao-Bao Luo, Department of Radiology, Taipei Veterans General Hospital, 201, Section 2, Shih-Pai Road, Taipei 112, Taiwan, R.O.C.

E-mail: cbluo@vghtpe.gov.tw • Received: June 20, 2005 • Accepted: December 22, 2005

The purpose of this study is to present our experiences in performing transarterial GDC embolization for intracranial high-flow AVFs and to evaluate its efficacy and safety.

Methods

From August 2001 to August 2004, 42 patients with intracranial high-flow AVFs were referred to our institute for endovascular management. Of these, 13 patients with 14 AVFs were treated by transarterial GDC embolization. The clinical data of the 13 patients with 14 AVFs are summarized in Table 1. There were 6 men and 7 women aged from 4 to 56 years (mean, 27 years). Their clinical manifestations were chemosis ($n = 7$), proptosis ($n = 4$), bruit ($n = 4$), headache ($n = 3$), intracranial hemorrhage ($n = 2$) after surgical treatment, and seizure ($n = 1$). Among the 14 AVFs, 8 were traumatic carotid-cavernous fistulas (TCCFs, Figure 1); 2 were AVFs at the temporal (Figure 2) or parieto-occipital lobe; 1 was a tentorium AVF (Figure 3); and 3 were associated with cerebral arteriovenous malformation (AVM) at the parieto-occipital, frontal or temporal lobes, respectively. One patient had received radiosurgery 3 years before embolization with partial remission of the AVM, and the other 2 underwent embolization of the AVFs followed by radiosurgery for the treatment of the AVMs. In the 8 TCCFs, transarterial detachable balloon embolization was selected as first-line embolization. However, residual high-flow fistulas remained in 3 after balloon

detachment at the cavernous sinus because of failure to negotiate the detachable balloon into the cavernous sinus due to a tortuous or stenotic carotid artery ($n = 3$) and/or small fistula tract ($n = 2$).

Endovascular procedures for all AVFs were performed under local ($n = 1$) or general ($n = 12$) anesthesia via a femoral approach. Activated clotting time was maintained at a value twice the baseline value. A 6F or 5F guiding catheter was positioned in the parent artery, followed by a microcatheter, which was navigated to the AVF. Occlusion of the AVF was initiated by selection of the proper GDC. Because the AVF was mechanically occluded by the coil mass, we preferred to use the large-caliber GDC (e.g. GDC-18) rather than the drug-coated GDC (e.g. Matrix) to shorten the procedure time and reduce the cost. In our series, the GDCs were densely packed into the cavernous sinus in 8 patients with TCCFs; in 5 AVFs, GDCs were placed into the fistula proper, including the distal artery and proximal venous sac or pouch, until the fistula flow was disconnected.

A postembolization angiogram was done immediately after completion of the procedure to check for occlusion of the fistula. Of the 14 AVFs, 8 had follow-up angiography from 1 week to 6 months after embolization.

Results

Results and follow-up findings are shown in Table 1. Complete fistula closures were documented on

Table 1. Demography and outcome of transarterial GDC embolization in 13 patients with 14 high-flow intracranial AVFs

Patient	Sex/age (yr)	Symptoms	Location and type of AVF	Associated vascular lesions	Coil number/length (cm)	Outcome of AVFs	Follow-up (mo)
1	M/35	Chemosis	TCCF	Nil	2/16	Cure	10
2	F/24	Chemosis, proptosis	TCCF	Nil	13/234	Cure	8
3	M/21	Chemosis, bruit	TCCF	Nil	7/92	Cure	25
4	F/56	Chemosis, bruit, proptosis	Residual TCCF	Nil	6/78	Cure	13
5	F/39	Chemosis, bruit, proptosis	Bilateral TCCFs	Nil	9/88 6/30	Pseudoaneurysm formation	18
6	F/52	Chemosis, bruit	Residual TCCF	Nil	6/73	Cure	15
7	M/23	Chemosis, proptosis	Residual TCCF	Contralateral TCCF	5/20	Cure	23
8	M/35	Headache	Temporal AVF	Temporal AVM	4/110	Cure	19
9	M/8	ICH	Temporal AVF	Nil	12/268	Cure	12
10	F/7	Headache	Occipital AVF	Nil	12/280	Cure	9
11	M/4	Seizure	Parieto-occipital AVF	Parieto-occipital AVM	8/138	Cure	24
12	F/27	Headache	Frontal AVF	Frontal AVM	9/111	Cure	6
13	F/16	ICH	Tentorium AVF	Nil	6/94	Cure	20

GDC = Guglielmi detachable coil; AVF = arteriovenous fistula; TCCF = traumatic carotid-cavernous fistula; AVM = arteriovenous malformation; ICH = intracranial hemorrhage.

postembolization angiograms in 10 AVFs (Figures 1–3), whereas a small residual flow remained in the other 3 (Figure 4). In all 3 residual AVFs, spontaneous thrombosis was expected, the procedure was discontinued, and total occlusion of the AVFs was

confirmed by follow-up angiograms 3–4 days later. One patient experienced temporary impairment of cranial nerve function, which resolved completely within 6 months. One patient with TCCF had an asymptomatic pseudoaneurysm formation at the

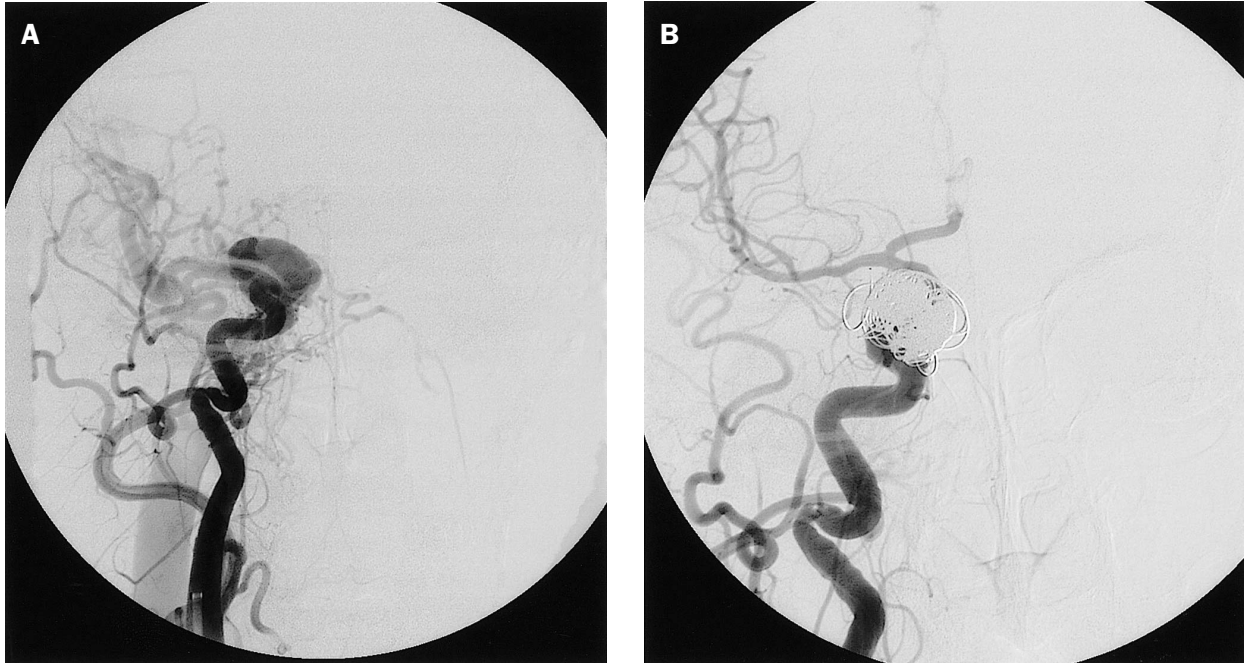


Figure 1. A 24-year-old woman presented with chemosis and proptosis because of traumatic carotid-cavernous fistula (TCCF). (A) Right frontal carotid angiogram shows a TCCF; a detachable balloon was selected to occlude the fistula, but failed to negotiate into the fistula due to a tortuous and stenotic internal carotid artery (ICA). (B) Thirteen Guglielmi detachable coils with a total coil length of 238 cm were employed to occlude the fistula and cavernous sinus and resulted in total occlusion of the fistula with preservation of the ICA.

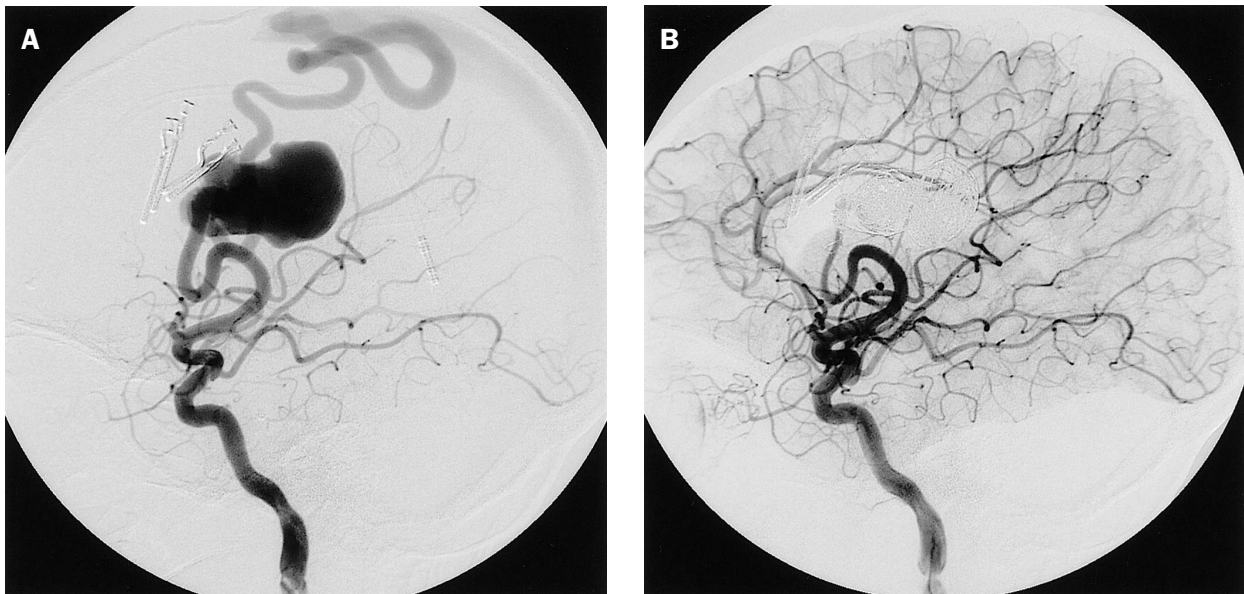


Figure 2. An 8-year-old boy had right temporal arteriovenous fistula (AVF) and presented with intracerebral hemorrhage after surgical treatment. (A) Right lateral carotid angiogram revealed a high-flow AVF at the right temporal lobe with a big venous pouch. (B) Transarterial Guglielmi detachable coil (GDC) embolization with total occlusion of the fistulas was achieved by the placement of 12 GDCs with a total coil length of 268 cm into the fistula tract and venous pouch.

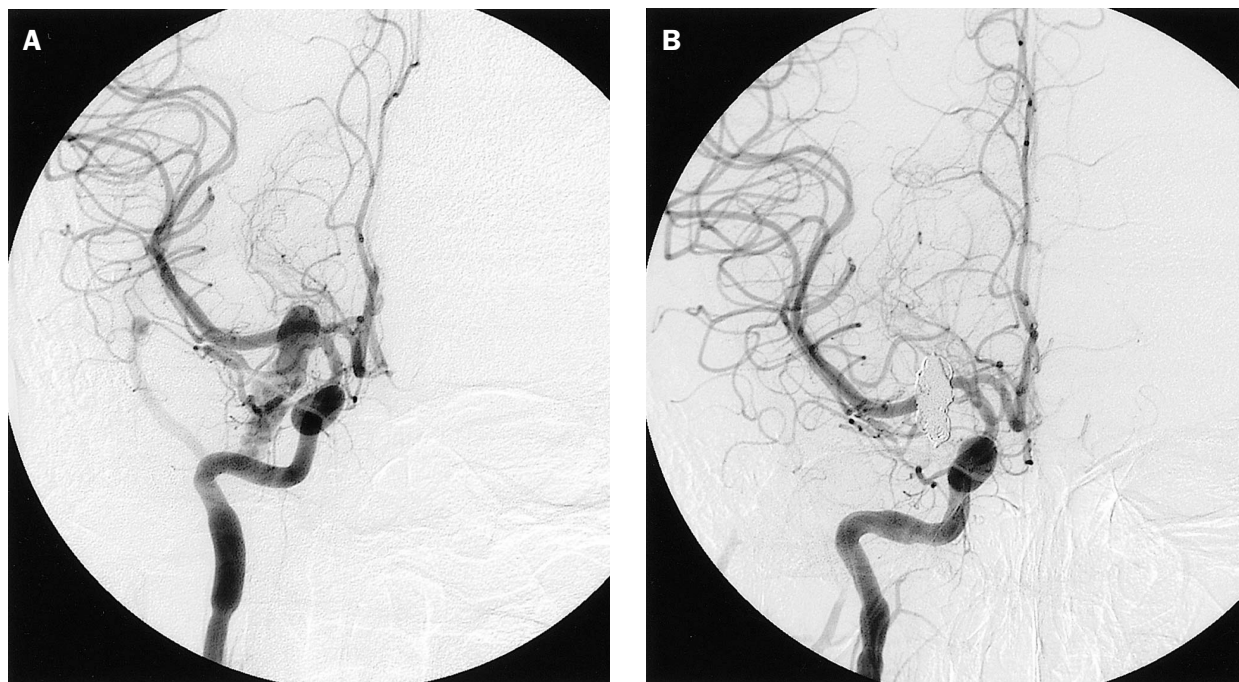


Figure 3. A 16-year-old girl had intracerebral hemorrhage relating to a tentorium arteriovenous fistula (AVF). (A) Right frontal carotid angiogram showed a tentorium AVF with venous pouch. (B) Patient underwent transarterial Guglielmi detachable coil (GDC) embolization resulting in total occlusion of the AVF; six GDCs with a total coil length of 94 cm were employed to occlude the AVF.

cavernous portion of the internal carotid artery (ICA) because of insufficient packing of the cavernous fistula. No significant procedure-related neurologic complications or recurrent AVFs were observed. In 8 patients with follow-up angiograms, no evidence of recurrent AVF was found. All 13 patients had been followed up clinically for an average of 16 months (range, 6–25 months). In all patients, the clinical symptoms and signs related to fistula, such as bruit, chemosis, proptosis, headache, and seizure, immediately or gradually resolved after endovascular treatment.

Discussion

The best endovascular approach for a high-flow AVF is via the transfemoral artery because of relatively easy access. The transvenous route is generally considered in low-flow AVFs involving a large dural sinus^{11,12} or when the arterial route is blocked or access fails. An important concept in endovascular management of high-flow AVFs is to deliver the embolic materials precisely to the fistula site, including the adjacent distal artery and proximal venous drain or pouch. Unintentional distal embolization with embolic material migrating into the venous systems with a

rapid increase in fistula pressure or pulmonary embolization may have disastrous consequences when the fistula is not occluded. Safe, effective therapy of these fistulas often hinges on the deposition of embolic material precisely at the fistula site, a task made more difficult in rapid, high-flow AVFs.

Regarding the selection of embolic agents for intracranial high-flow AVFs, a permanent embolic material that can produce a mechanical obstruction of shunting flow is effective. Common permanent embolic agents employed for endovascular embolization of intracranial high-flow AVFs include detachable balloon and microcoils; on occasion, liquid adhesive has also been used to occlude these high-flow fistulas.

TCCFs are usually treated with a detachable balloon and have a promising outcome.^{13,14} However, in patients with a tortuous ICA, small fistula tract, small venous compartment, or intimal flap, the balloon cannot be guided into such a position that the fistula is occluded and the parent artery is preserved. In addition, the sharp margins of bony fractures or foreign bodies may rupture the balloon during inflation.⁸ In our series, we failed to negotiate the detachable balloon into the cavernous sinus in 5 TCCFs. The potential risks of over-manipulation of the detachable balloon in these difficult patients may result in thromboembolic events.

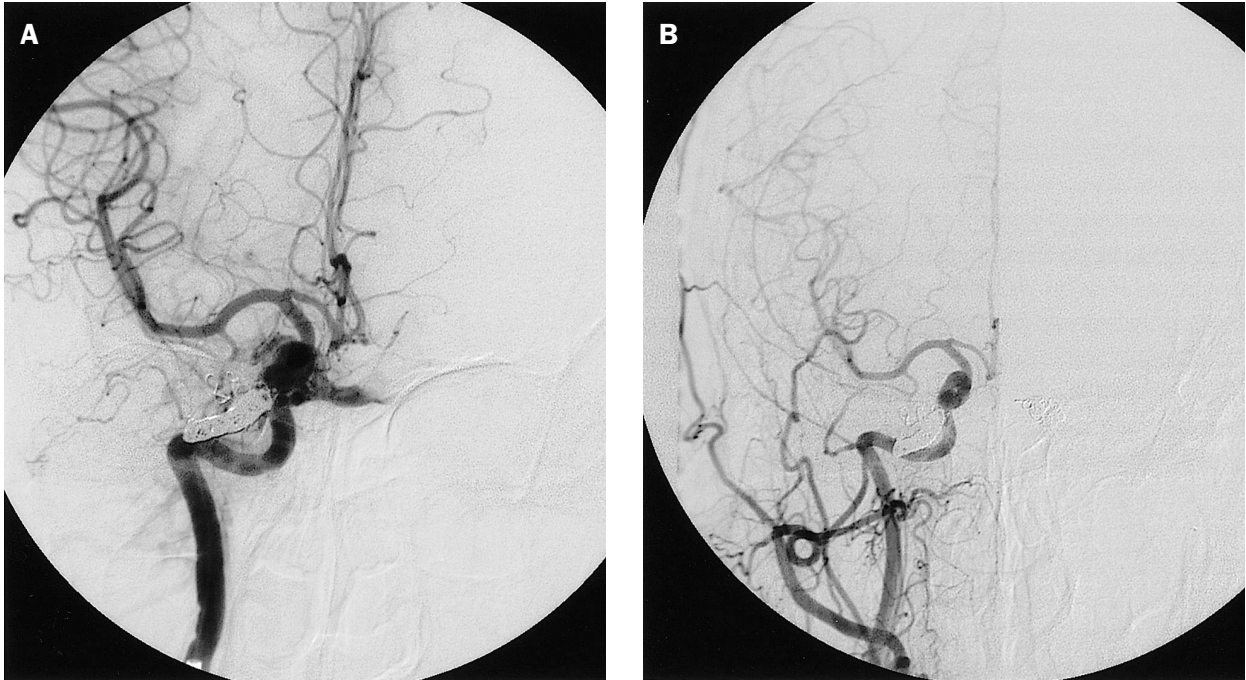


Figure 4. A 39-year-old female had bilateral traumatic carotid-cavernous fistulas and received Guglielmi detachable coil embolization. (A) Postembolization right frontal carotid angiogram revealed subtotal occlusion of the fistula with a small residual shunting flow. (B) Follow-up angiogram 3 days later showed total obliteration of the residual shunting flow.

N-butyl-2-cyanoacrylate (NBCA) has been used widely for embolization of intracranial arteriovenous malformation and occasionally, low- and high-flow intracranial AVFs.¹⁵⁻¹⁷ For high-flow AVFs, it has the advantage of being relatively easy to deliver through a microcatheter, producing rapid induction of thrombosis and permanent occlusion after polymerization. Theoretically, there are 2 main potential disadvantages when NBCA is used as an embolizing agent for treating high-flow AVFs. The first is that highly concentrated NBCA polymerizes very rapidly and tends to stick to the microcatheter. The second drawback is the difficulty in controlling the flow and polymerization of the NBCA and its cast formation during embolization.

The use of a conventional microcoil alone has been reported in the treatment of intracranial high-flow AVFs.¹⁸ Technique pitfalls associated with embolization performed with these coils include the impossibility of easy retrieval, the relative stiffness of the coils, the risk of perforation, and the difficulty of packing them tightly. Moreover, complete obliteration of the fistula may be difficult to achieve, and there is a risk of impingement on the parent vessel and possible distal coil migration. In our series, we found that GDC could generally be deposited predictably at the desired site, and that they could be observed prior to

detachment, to help ensure that the coil was in a secure position, decreasing the chances of unintended passage into the venous outlet. In addition, the coils are soft, and can, therefore, be packed tightly into the targeted vessels that they are intended to occlude. Also, when compared with conventional microcoils, their increased length allows a greater number of coils to be delivered at one time, and their retrievability allows suboptimally placed coils to be repositioned or removed, so as to reduce the risk of coil migration to the distal venous side. In addition, GDCs can act as a template for the deposition of other embolic materials such as NBCA, slowing flow and creating turbulence to promote polymerization of the glue at the fistula site. It can also provide a physical barrier to the further movement of other embolic agents.^{8,15} However, GDCs are not without disadvantages.^{9,10} GDCs are not thrombogenic and they have less space-filling capacity than balloons, which may result in incomplete occlusion if the fistula cannot be densely packed. Detachment of GDCs can take more than 1 hour in individual cases, especially when multiple coils are used. Therefore, the GDC was thought by some physicians as a suitable embolic material for those AVFs with a small fistula tract.^{9,10} Furthermore, GDCs are very expensive as compared with detachable balloon and liquid adhesives. To reduce the cost, the

combination of GDCs with other embolic materials, such as liquid adhesives or other platinum coils, is an alternative.

In our series, the GDC was used alone to occlude the high-flow fistulas. Because the GDC itself is not thrombogenic, many coils may be needed to achieve mechanical blockage of a large shunting fistula. In the present series, 2–13 coils with an average number of 8 and an average length of 126 cm were used to achieve mechanical occlusion of the fistulous connection. In the treatment of fistulas immediately adjacent to a large parent artery, such as a TCCF, exact coil positioning and the prevention of herniation into the parent vessel are critical in minimizing the persistence of pseudoaneurysms and embolic complications. In our series, there was an asymptomatic pseudoaneurysm formation at the cavernous ICA after total occlusion of shunting flow. Subtotal obliteration of the fistulas with small fistula flow was observed in 3 cases at the end of the procedure. Spontaneous closure of the residual fistulas was found on follow-up angiogram 3–4 days after embolization. Therefore, subtotal occlusion with blockage of most parts of the fistula tract that was associated with significant slowing down of the shunting flow on angiography may not indicate failure and does not appear to be a definite indication to place more coils. However, follow-up angiogram is mandatory to check the occurrence of spontaneous thrombosis.

In this series, all patients were treated with GDCs via the transarterial route with excellent results. Transarterial GDC embolization is a useful method in the treatment of intracranial high-flow AVFs. It affords more control over the placement of coils and proves both efficient and safe in the management of intracranial high-flow AVFs.

Acknowledgment

This article was supported, in part, by grants from Taipei Veterans General Hospital (VGH94-398).

References

1. Debrun GM, Vinuela F, Fox AJ, Daves KR, Ahn KS. Indications for treatment and classification of 132 carotid-cavernous fistulas. *Neurosurgery* 1988; 22:285–9.

2. Hallbach VV, Higashida RT, Hieshima GB. Treatment of vertebral arteriovenous fistulas. *AJNR Am J Neuroradiol* 1987; 8:1121–8.
3. Liu HM, Wang YH, Chen YF, Cheng JS, Yip PK, Tu YK. Long-term clinical outcome of spontaneous carotid cavernous sinus fistulae supplied by dural branches of the internal carotid artery. *Neuroradiology* 2001;43:1007–14.
4. Huang YC, Liu HM, Lin SM, Chen YF, Jeng CM. Spontaneous progressive occlusion of a large, high-flow direct carotid cavernous fistula after partial treatment with Guglielmi detachable coils. *Chin J Radiol* 2000;25:215–8.
5. Luo CB, Lirng JF, Teng MMH, Chen SS, Guo WY, Chang T. Endovascular embolization of arteriovenous fistulas of the external carotid artery. *J Chin Med Assoc* 1998;61:260–6.
6. Zubeilaga AF, Guglielmi G, Vinuela F, Duckwiler GR. Endovascular occlusion of intracranial aneurysms with electrically detachable coils: correlation of aneurysm neck size and treatment results. *AJNR Am J Neuroradiol* 1994;15:815–20.
7. Luo CB, Teng MMH, Chang FC, Lirng JF, Chang CY. Endovascular management of the traumatic cerebral aneurysms associated with traumatic carotid cavernous fistulas. *AJNR Am J Neuroradiol* 2004;25:501–5.
8. Evans AJ, Jesen ME, Mathis JM, Dion JE. The Guglielmi detachable coil in the treatment of arteriovenous fistulae. *Interv Neuroradiol* 1996;2:201–7.
9. Guglielmi G, Vinuela F, Duckwiler G, Dion J, Stocker A. High-flow, small-hole arteriovenous fistulas: treatment with electrodetachable coils. *AJNR Am J Neuroradiol* 1995;16: 325–8.
10. Similuoto T, Seppanen S, Kuurne T, Wikholm G, Leinonen S, Svendsen P. Transarterial embolization of a direct carotid cavernous fistula with Guglielmi detachable coils. *AJNR Am J Neuroradiol* 1997;18:519–23.
11. Dawson RC, Joseph GJ, Owen DS, Barrow DL. Transvenous embolization as the primary therapy for arteriovenous fistulas of the lateral and sigmoid sinus. *AJNR Am J Neuroradiol* 1998;19:571–6.
12. Halbach VV, Higashida RT, Hieshima GB, Mehringer CM, Hardin CW. Transvenous embolization of dural fistulas involving the transverse and sigmoid sinuses. *AJNR Am J Neuroradiol* 1989;10:385–92.
13. Lewis AI, Tomsick TA, Tew JM. Management of 100 consecutive direct carotid-cavernous fistulas: result of treatment with detachable balloons. *Neurosurgery* 1995;36:2:239–45.
14. Higashida RT, Halbach VV, Tsai FY, Norman D, Pribram HF, Mehringer CM, Hieshima GB. Interventional neurovascular treatment of traumatic carotid and vertebral artery lesions: results in 234 cases. *Am J Roentgenol* 1989;153:577–82.
15. Luo CB, Teng MMH, Yen DH, Chang FC, Lirng JF, Chang CY. Endovascular embolization of recurrent traumatic carotid-cavernous fistula managed previously with detachable balloons. *J Trauma* 2004;56:1214–20.
16. Kerber CW, Bank WO, Cromwell LD. Cyanoacrylate occlusion of carotid-cavernous fistula with preservation of carotid artery flow. *Neurosurgery* 1979;4:210–5.
17. Pierot L, Moret J, Boulin A, Castaings L. Endovascular treatment of post-traumatic complex carotid-cavernous fistulas, using the arterial approach. *J Neuroradiol* 1992;19:79–87.
18. Halbach VV, Higashida RT, Barnwell SL, Dowd CF, Hieshima GB. Transarterial platinum coil embolization of carotid-cavernous fistulas. *AJNR Am J Neuroradiol* 1991;12:429–33.