

# Embedded Ring Injury of the Middle Finger in an Amphetamine Abuser

Bo-Wei Zeng<sup>1</sup>, Yi-Jie Guo<sup>2</sup>, Cheng-Chin Huang<sup>1\*</sup>

<sup>1</sup>Department of Emergency Medicine, China Medical University Hospital, Taichung,  
and <sup>2</sup>Department of Orthopedics, Taipei City Hospital, Zhongxing Branch, Taipei, Taiwan, R.O.C.

Embedded finger-ring injury is not usually encountered in clinical practice, and most patients present with psychiatric or physical/mental impairment. We report herein an 18-year-old male amphetamine abuser who presented to our emergency department (ED) for embedded finger-ring injury over his left middle finger. The embedded ring was removed in the ED under heavy sedation, and the wound healed uneventfully over 2 weeks. Thereafter, the young man received psychiatric treatment. Embedded finger-ring injury has never been reported in a drug abuser before. [*J Chin Med Assoc* 2006;69(2):95–97]

**Key Words:** abuse, amphetamine, embedded ring injury

## Introduction

Embedded finger-ring injury is uncommon. Only sporadic cases of embedded finger-ring injury have been reported in the literature, and this condition usually occurs in patients with physical/mental impairment.<sup>1</sup> Embedded finger-ring injury has never been reported in a drug abuser before.

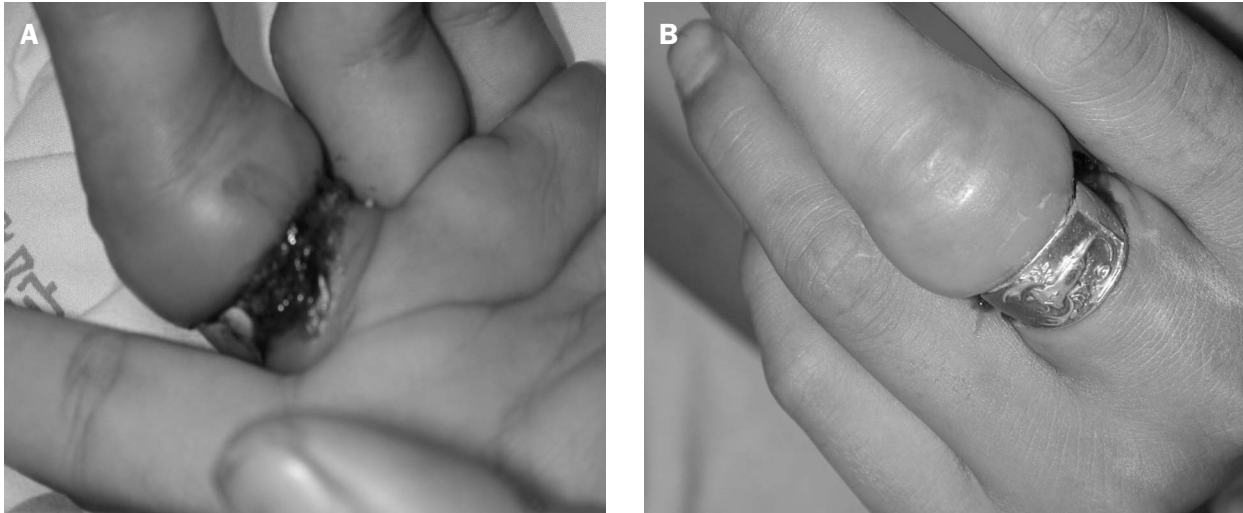
## Case Report

An 18-year-old man was brought to the emergency department (ED) by his mother for a ring on his left middle finger that could not be removed. According to the patient's description, he had put on the ring, a present from his girlfriend, about 2 weeks earlier. Progressive swelling of the finger distal to the ring developed over several days. He tried to remove the ring using a pair of pliers but failed. The ring sank into the palmar side of the finger, and purulent discharge was noted 1 week before presentation. His mother mentioned that the patient was an amphetamine abuser and had refused to abstain from it for months,

even after repeated attempts to persuade him. On examination, the young man looked alert and thin, but anxious and restless. Marked swelling and congestive change of the whole finger were noted. The ring was embedded on the palmar side with some eschar, purulent drainage and necrotic tissue surrounding it (Figure 1). Pain and touch sensation remained, but there was numbness, and the range of motion was limited to moderate flexion.

We used a ring cutter, a wire cutter, and a pin cutter successively while trying to remove the ring, but there was no space to insert the tip of the cutters. Because the ring was so deeply embedded, we could not apply these tools effectively. Another cutter with sharp tips, borrowed from the hospital's engineering department, solved the problem. The ring was cut at the lateral aspect of the finger, piece by piece, with the sharp tip of the cutter. The patient was uncooperative with the procedures due to severe wound pain. After an intravenous injection of analgesic and neuromuscular blocking agent (Demerol 50 mg and Rocuronium 25 mg) and ventilation assisted by a ball-valve mask, the ring was finally removed. A tissue groove, about 4–5 mm deep, lay on the palmar aspect of the finger

\*Correspondence to: Dr. Cheng-Chin Huang, Department of Emergency Medicine, China Medical University Hospital, 2, Yuh-Der Road, Taichung 404, Taiwan, R.O.C.  
E-mail: cmcherkimo@yahoo.com.tw • Received: January 20, 2005 • Accepted: September 27, 2005



**Figure 1.** Palmar (A) and dorsal (B) aspects of the injured finger with the ring in place.

base and was irrigated by a copious amount of saline solution. On the dorsal aspect of the finger where the ring had covered, the skin showed only whitish change and minimal erosion, and there was no evidence of allergy over the surrounding skin. There was only a minimal amount of blood loss during the procedures. About 20 minutes later, after the wound was dressed and the patient awakened, he was discharged.

The patient was followed in the outpatient department and the wound healed uneventfully in about 2 weeks. The patient then received treatment in the psychiatric department.

## Discussion

Emergency physicians sometimes have to manage the probable lethal complications of acute intoxication caused by substance abuse. Amphetamine, a synthetic stimulant, is the most commonly used illicit drug in Taiwan and may cause acute sympathomimetic symptoms. Extreme euphoria, irritability, dehydration, and rhabdomyolysis with resultant acute renal failure or even death may present.<sup>2</sup>

Amphetamine-induced psychosis has been described for decades,<sup>3</sup> and the term “amphetamine psychosis” has been used by some authors.<sup>4,5</sup> It refers to a delusional state caused by the use of amphetamines that does not involve clear hallucinations or changes in one’s state of consciousness. Patients with amphetamine psychosis may reveal restlessness, elation, paranoid ideas, or hallucinosis and are difficult to distinguish from psychosis of schizophrenia unless the drug abuse

history is obtained. However, according to Gunnarsson et al’s report,<sup>6</sup> senior high school students who experienced psychiatric symptoms induced by illicit drugs seldom sought professional treatment or support. For the amphetamine abuse history and restlessness of the patient reported here, a drug-induced psychiatric disorder could not be ignored, although a complete psychiatric assessment was not obtained in the ED.

Almost all of the reported patients who suffered from embedded finger-ring injury had a history of psychiatric or physical/mental impairment.<sup>1, 7-10</sup> An otherwise normal 13-year-old boy who presented with embedded finger ring due to deep embarrassment was reported.<sup>11</sup> Constriction injuries of fingers with resultant swelling and congestion due to venous obstruction are not uncommon. When a patient presents to the ED promptly after self-removal has failed, the constrictive band or ring can be removed reversely by decompression of the swollen finger with a narrow tourniquet or bandage. Erosion of skin, subcutaneous tissue, tendon, or neurovascular bundle may progress if the patient cannot respond well or is ignored. Sometimes, skin will heal over the ring and form an epithelial bridge that may make the diagnosis less clear.<sup>11</sup>

Removal of the ring is always indicated to prevent further injuries, although a patient with psychosis may refuse the procedure and be lost to follow-up.<sup>8</sup> Once the ring is embedded, it cannot be removed without destroying it. A cutter may be needed, and, sometimes, the skin bridge must be incised.<sup>8, 11</sup> However, a ring cutter may not be suitable if there is not enough space to insert the cutter between the ring and soft tissue.

The use of a ring cutter has seldom been discussed in the literature. It is important to choose a cutter with sharp tips and finger fasciotomy; leaving enough space to insert the cutter may be another option to facilitate the procedure. All reported cases in the literature reviewed had good wound recovery, although one of them needed 3–4 weeks.<sup>11</sup>

In conclusion, embedded ring-finger injury may occur in a drug abuser with psychiatric symptoms, and removal of the ring to prevent further injuries is always recommended.

## References

1. Balakrishnan C, Nyitray J. Unusual presentation of a ring injury in a psychiatric patient. *J Psychosoc Nurs Ment Health Serv* 1999;37:37–8.
2. Zealburg JJ, Brady KT. Substance abuse and emergency psychiatry. *Psychiatr Clin North Am* 1999;22:803–17.
3. McGuire PK, Jones P, Harvey I, Bebbington P, Toone B, Lewis S, Murray RM. Cannabis and acute psychosis. *Schizophr Res* 1994;13:161–7.
4. Yui K, Goto K, Ikemoto S, Ishiguro T. Methamphetamine psychosis: spontaneous recurrence of paranoid-hallucinatory states and monoamine neurotransmitter function. *J Clin Psychopharmacol* 1997;17:34–43.
5. Caplehorn JR. Amphetamine psychosis. *Br J Addict* 1990;85:1505–6.
6. Gunnarsson M, Fahlke C, Balldin J. Adolescents who have tried illicit drugs and experienced psychiatric symptoms seldom seek professional help: a pilot study of 18-year-old high school students in an urban district. *Psychol Med* 2003;33:1407–14.
7. Saltz R, Fix J, Grotting JC. Sapphire ring constriction syndrome. *Ann Plast Surg* 1988;21:375–6.
8. Kuschner SH, Gellman H, Hume M. Embedded ring injuries. *Clin Orthop Rel Res* 1992;276:192–3.
9. Keith EF, Dana AJ. Embedded-ring syndrome. *Ann Emerg Med* 1995;25:856–7.
10. Deshmukh NV, Stothard JS. The embedded ring injury: case report and review of literature. *Hand Surg* 2003;8:103–5.
11. Bennett KG, Brou JA, Levine NS. Completely embedded ring in the finger of a growing child. *Ann Plast Surg* 1995;34:76–7.