

Pyomyositis During Induction Chemotherapy for Acute Lymphoblastic Leukemia

Kai-Liang Kao*, Giun-Yi Hung, Betau Hwang

Department of Pediatrics, Taipei Veterans General Hospital, Taipei, Taiwan, R.O.C.

Herein, we report on the correct diagnosis and effective treatment procedures for pyomyositis, a very rare complication that remains a diagnostic challenge in children being treated for acute lymphoblastic leukemia (ALL). We report the case of a 10-year-old girl suffering from pyomyositis with ALL. Correct diagnosis is usually delayed because the initial symptom of pyomyositis, usually local pain, is similar to the common side effect of vincristine, a drug necessary for ALL induction therapy. We summarize the procedures taken to reach a timely diagnosis and therapeutic success. [*J Chin Med Assoc* 2006;69(4):184–188]

Key Words: acute lymphoblastic leukemia, muscle abscess, pyomyositis

Introduction

Pyomyositis is a rare infectious disease that is difficult to diagnose. It is a spontaneous purulent infection of skeletal muscle, first described by Scriba in 1885,¹ who reported 4 cases. It is rare in temperate climates. Grose² reported an incidence rate of 1 per 3,000 pediatric admissions in southern Texas. The pathogenesis of pyomyositis remains unknown and transient bacteremia is suspected.³ Its clinical course is subacute and is often not noted until the secondary stage, leading to delays in effective treatment.^{4–9}

Pyomyositis occurs in children receiving induction therapy for acute lymphoblastic leukemia (ALL). A search of the MEDLINE database found 4 cases. In 1979, Blatt et al⁹ first described it in 2 children with ALL, occurring a few weeks after the initiation of induction therapy. In 1996, Corden and Morgan¹⁰ also presented 2 cases suffering from pyomyositis shortly after induction therapy. In 2004 we also noted a patient with ALL who developed pyomyositis during induction chemotherapy. In this report, we describe our case and the 4 cases recorded in MEDLINE.

Case Report

A 10-year-old Taiwanese girl was transferred to our hospital on May 20, 2004, because of severe anemia. On physical examination, she was weak and pale. Her abdomen was soft and flat without palpable liver or spleen. A 1 × 1-cm lymph node was noted over the right retro-sternocleidomastoid area. There were some ecchymoses over her left arm. The hemogram showed: white blood cells (WBC), 5000/ μ L; hemoglobin, 4.6 g/dL; MCV, 90/fL; and platelet counts, 7,000/ μ L. Blood chemistry revealed: aspartate aminotransferase (AST) 86 U/L (reference, 5~45 U/L); alanine aminotransferase (ALT), 47 U/L (reference, 0~40 U/L); alkaline phosphatase, 169 U/L (reference, 10~100 U/L); lactate dehydrogenase, 404 U/L (reference, 95~213 U/L); and uric acid, 5.1 mg/dL (reference, 1.8~7.2 mg/dL). Acute leukemia was suspected and we performed bone marrow aspiration. The smears showed hypocellularity almost replaced by homogeneous high nuclear-to-cytoplasmic ratio blasts. The trilineage precursors depressed markedly. The cell marker analysis revealed: CD19, 89.9%; CD10, 73.7%; CD20, 7.8%; CD2, 4%; CD3, 4.6%; CD7, 3.5%. Acute precursor B-lymphoblastic leukemia was diagnosed.

*Correspondence to: Dr. Kai-Liang Kao, Department of Pediatrics, Taipei Veterans General Hospital, 201, Section 2, Shih-Pai Road, Taipei 112, Taiwan, R.O.C.

E-mail: gkl.123@yahoo.com.tw • Received: May 3, 2005 • Accepted: August 25, 2005

The Taiwan Pediatric Oncology Group (TPOG) induction chemotherapy TPOG regimen with vincristine (1.5 mg/m^2), epirubicin (20 mg/m^2), and prednisolone (40 mg/m^2) began. Mild nausea and vomiting were noticed initially. One episode of low-grade fever, up to 38.2°C , was noted after 5 days of chemotherapy but it subsided spontaneously. The chemotherapy was continued without delay. However, the patient suffered from left chest wall pain on the 6th day of chemotherapy. There was no local sign of erythema, tenderness, or swelling and her WBC counts were $600/\mu\text{L}$. Vincristine and epirubicin continued on the 8th day under the probability of neuropathic pain of vincristine. However, right thigh pain, followed by bilateral lower leg pain occurred on the 12th day. There was still no local sign of erythema, tenderness, or induration over these painful areas, including the initial lesion of the left chest wall.

Fever developed on the 14th day of chemotherapy, with local tenderness, swelling, and local heat. Empiric antibiotics including vancomycin and ceftazidime were administered and the fever subsided on the 5th day. However, the initially painful lesions were still swelling. Soft-tissue ultrasonography revealed an accumulation of fluid in her left chest wall and right thigh (Figures 1 and 2). Needle aspiration yielded drainage of 1–2 mL pus. Meanwhile, the blood culture before antibiotic prescription yielded methicillin-sensitive *Staphylococcus aureus*. In the following days, a pigtail was inserted in her right thigh because of increased fluid accumulation. The abscess was drained for 11 days, producing a total of 183.5 mL pus fluid. Gram stain and culture revealed no growth. Vancomycin was continued for 4 weeks before shifting to the oral form of oxacillin for 2 weeks. She received regular follow-up at our hospital and

continued the full course of chemotherapy, including early intensification and maintenance. There was no recurrent event of pyomyositis (course charted in Figure 3).

Discussion

Pyomyositis refers to spontaneous abscess of skeletal muscle. It is predominant in tropical areas, and less common in temperate climates where it is responsible for 1 in 3,000 pediatric admissions.² It can be seen in all age groups and is most common in the first and second decades of life.¹¹ In acute leukemia, ALL is prevalent in this age group, but pyomyositis remains a very rare complication in children under induction chemotherapy for ALL.¹⁰ Four boys and 1 girl, aged between 9 and 19 years, have been reported as suffering from this complication in the literature. The clinical presentations are listed in Table 1.

It is difficult to diagnose pyomyositis in children with ALL for the following reasons. First, neuropathic pain is a common complication under vinca alkaloid chemotherapy, including vincristine.^{12,13} Initial symptoms of pyomyositis can be mistaken as the side effects of induction therapy. Second, early examination rarely yields a specific finding to confirm pyomyositis.

All 5 cases reported showed a similar clinical course (Table 1). Local pain began after 1–3 weeks of induction therapy. The prescription in common was vincristine, a drug necessary for ALL induction therapy that unfortunately often causes neuropathic or limb pain.^{12,13} Local pain can be managed by supportive care, but it might also be a common sign of pyomyositis.⁸

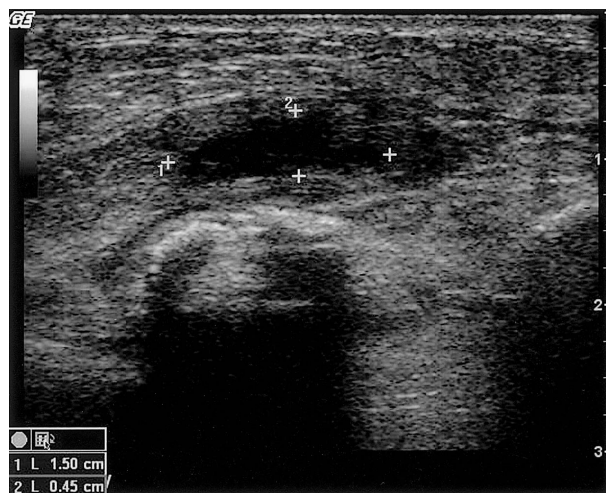


Figure 1. A 1.5×0.45 -cm hypoechoic lesion is noted at the left chest wall on ultrasonography.

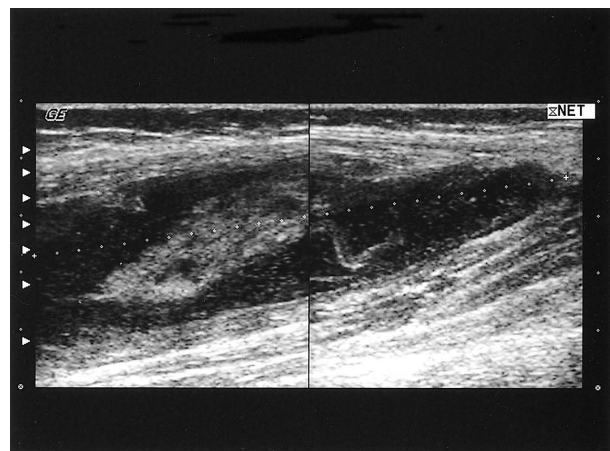


Figure 2. A $15 \times 3.5 \times 2.5$ -cm heterogeneous lesion with echogenic floating material is noted at the antero-lateral aspect of the right thigh on ultrasonography.

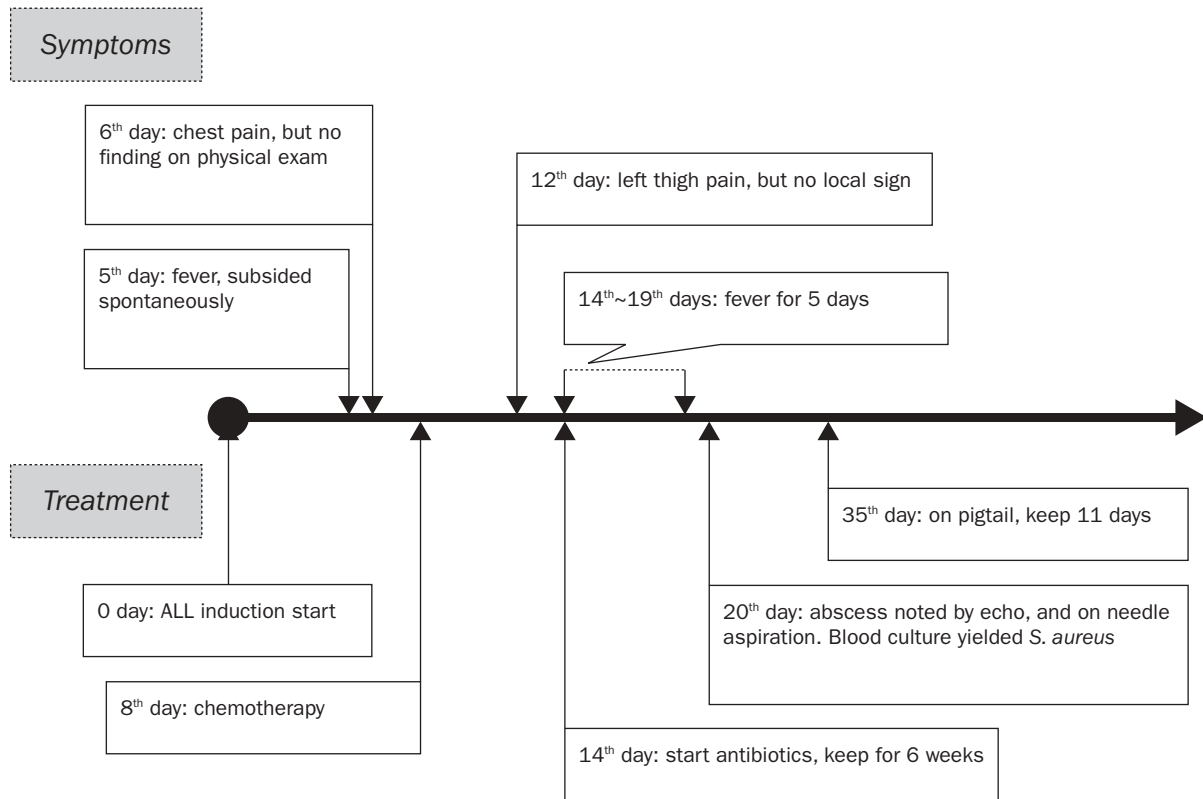


Figure 3. The case patient's hospital course.

Table 1. Clinical presentation in 5 cases with pyomyositis during induction chemotherapy for acute lymphoblastic leukemia*

Case from reference	Age (yr) /sex	Time after induction	Initial symptom site	Lesion sign	Initial temperature (°C)	Initial WBC
Blatt et al ⁹	19/M	3 weeks	R calf R elbow	Pain Tender (+) Rash	38.5	1,000
Blatt et al ⁹	12/M	1 week	R calf L thigh	Pain Erythema Rash	38.3	400
Corden and Morgan ¹⁰	9/M	3 weeks	Bilateral thigh	Pain Weak	37.8	13,700
Corden and Morgan ¹⁰	10/M	18 days	L leg	Pain Limping	Low-grade fever	10,700
Our case	10/F	6 days	L chest wall	Pain	38.2	600

WBC = white blood cell; M = male; F = female; R = right; L = left.

*Induction drugs used in our case were vincristine, epirubicin, and prednisolone. Those used in the other cases were vincristine, daunorubicin, prednisolone, and L-asparaginase

Because the clinical presentation of pyomyositis is rare and vague, the chances of it being listed in the initial diagnosis are low, especially due to the vincristine-induced pain effect. The delay in diagnosis may result in serious complications, such as compartment syndrome, extension into and destruction of an adjacent joint, sepsis, abscess formation on another site, and, occasionally, death. The long-term sequelae of pyomyositis include osteomyelitis, muscle-scarring,

residual weakness, and functional impairment.¹¹ Although none of the 5 cases mentioned earlier died, pyomyositis may affect the course of chemotherapy for ALL, especially when treatment is delayed as a result of the above-mentioned complications.

Pyomyositis requires many investigations. However, the data collected are often more helpful for the treatment course than for the diagnosis. There is usually no specific finding in the hemogram and

Table 2. Clinical treatment in the 5 cases with pyomyositis during induction chemotherapy for acute lymphoblastic leukemia

Case from reference	Pus drainage	Organism	Site of positive culture	Duration of antibiotics (days)	Multiple abscess lesion
Blatt et al ⁹	Aspiration + surgical drainage	<i>S. aureus</i>	Blood and abscess	28	Yes
Blatt et al ⁹	Aspiration + surgical drainage	<i>S. aureus</i>	Abscess	30	Yes
Corden and Morgan ¹⁰	Aspiration + surgical drainage	<i>S. aureus</i>	Abscess	36	Yes
Corden and Morgan ¹⁰	Surgical drainage	<i>S. aureus</i>	Blood	31	Yes
Our case	Aspiration + pigtail	<i>S. aureus</i>	Blood	42	Yes

blood chemistry at the beginning. Leukocytosis, elevated C-reactive protein, and elevated erythrocyte sedimentation rates may be seen at the suppurative stage if patients are not at the nadir stage. Plain films are not helpful in diagnosis.¹⁴ Ultrasound could be used to detect fluid collection, especially at the suppurative stage, but it is far more difficult in the early diagnosis if there is no fluid formation. Subtle findings, such as altered echogenicity, may result in it being easily overlooked.¹⁴ It is important to determine the causative agent, under ultrasound-guided aspiration.

S. aureus is the most common infecting organism in pyomyositis (> 90%) and streptococcal infection is the second most common organism.³ The organism cultured in these 5 cases was *S. aureus* (Table 2). Therefore, initial empirical antibiotic therapy should cover *Staphylococcus*,^{2-4,8,10,11} and should begin as early as possible to avoid massive pus formation. Some healthy children suffering from pyomyositis are cured by antibiotic therapy only.⁸ However, in addition to antibiotic therapy, children with ALL often need surgical drainage because of enlarged abscess accumulation, as in the 5 cases described herein. One case experienced re-debridement due to reaccumulation of pus fluid.¹⁵ Different from the other 4 cases, our case had pigtail pus drainage performed for continuous pus drainage, resulting in a final collection of 183.5 mL of pus fluid in 11 days. All 5 cases had antibiotic therapy for 4–6 weeks, longer than ordinarily needed by healthy children.

The presence of multiple abscess lesions in these 5 cases is also quite different from the single abscess lesion reported in non-ALL children with pyomyositis. Hematogenous spread is a possible cause and it may be necessary to drain the abscess lesions several times.

To date, 5 ALL children suffering from pyomyositis during induction chemotherapy have been reported. The pathogenesis is poorly understood. Previous reports have described possible precipitating factors

such as neutropenia, immunosuppression secondary to their disease and therapy, drug-induced muscle injury potentially resulting from prednisolone treatment, or muscle trauma from injected L-asparaginase.¹⁰ However, there was no L-asparaginase injection before our patient began suffering from pyomyositis. More research is needed to determine the pathogenesis.

In conclusion, local muscle pain, a symptom of pyomyositis, might be misinterpreted as due to vincristine neurotoxicity, until the symptoms get worse or when fever occurs. It may prolong the course of pyomyositis or result in severe complications.

Pyomyositis should be included in the standard diagnostic procedure of children with ALL who present with local pain during induction chemotherapy. Effective standard treatment involves antibiotic therapy, incision, and drainage. Antibiotic therapy should initially cover *S. aureus* until the specific organism is identified. With early recognition and appropriate medical and surgical care, the treatment course can be shortened and morbidity and mortality can be avoided.

References

1. Scriba J. Beitrag zur aetiologie der myositis acuta. *Dtsch Z Chir* 1885;22:497–502.
2. Grose C. Staphylococcal pyomyositis in South Texas. *J Pediatr* 1978;93:457–8.
3. Chiedozi LC. Pyomyositis. Review of 205 cases in 112 patients. *Am J Surg* 1979;137:255–9.
4. Martinez R, Garwacki J. Tropical myositis. *N Engl J Med* 1971;284:196–8.
5. Echeverria P, Clay Vaughn M. Tropical pyomyositis: a diagnostic problem in temperate climates. *Am J Dis Child* 1975;129:856–7.
6. Sirinavin S, McCracken GH Jr. Primary suppurative myositis in children. *Am J Dis Child* 1979;133:263–5.
7. Chaitow J, Martin HCO, Knight P, Buchanan N. Pyomyositis tropicans: a diagnostic dilemma. *Med J Aust* 1980;2:512–3.
8. Gubbay AJ, Isaacs D. Pyomyositis in children. *Pediatr Infect Dis J* 2000;19:1009–13.

9. Blatt J, Reaman G, Pizzo P. Pyomyositis in acute lymphocytic leukemia heralded by cutaneous vasculitis. *Med Pediatr Oncol* 1979;7:237-9.
10. Corden TE, Morgan ER. Pyomyositis during induction chemotherapy for acute lymphocytic leukemia. *J Pediatr Hematol Oncol* 1996;18:323-6.
11. Bickels BJ, Ben-Sira L, Kessler A, Wientroub S. Primary pyomyositis. *J Bone Joint Surg* 2002;84:2277-86.
12. Sandler SG, Tobin W, Henderson ES. Vincristine-induced neuropathy: a clinical study of fifty leukemia patients. *Neurology* 1969;19:367-74.
13. Holland JF, Scharlau C, Gailani S, Krant MJ, Olson KB, Horton J, Shnidwe BI, et al. Vincristine treatment of advanced cancer: a cooperative study of 392 cases. *Cancer Res* 1973;33:1258-64.
14. Trusen A, Beisert M, Schultz G, Chittka B, Darge K. Ultrasound and MRI features of pyomyositis in children. *Eur Radiol* 2003;13:1050-5.
15. Renwick SE, Ritterbusch JF. Pyomyositis in children. *J Pediatr Orthop* 1993;13:769-72.