

# Unusual Origin of Radial Collateral Artery Noted in Quadrangular Space Syndrome

Mohandas Rao Kappettu Gadahad\*, Seetharama Manjunatha Bhat, Venkata Ramana Vollala  
 Department of Anatomy, Melaka Manipal Medical College (Manipal Campus), Manipal, India.

In this paper, an unusual origin of the radial collateral artery of the arm is reported. The radial collateral artery in one of the cadavers dissected by us originated from the posterior circumflex humeral artery. The importance of this abnormal origin of the radial collateral artery from the posterior circumflex humeral artery in quadrangular space syndrome is discussed. [*J Chin Med Assoc* 2006;69(6):276–277]

**Key Words:** posterior circumflex humeral artery, quadrangular space syndrome, radial collateral artery

## Introduction

Normally, the radial collateral artery is one of the terminal branches or it may be the continuation of the profunda brachii artery, given in the posterior compartment of the arm, in the radial groove. This artery accompanies the radial nerve as it passes through the lateral intermuscular septum, descends between the brachialis and brachioradialis, and ends in front of the lateral humeral epicondyle by anastomosing with the radial recurrent artery. In this paper, a variation in the origin of this artery is reported.

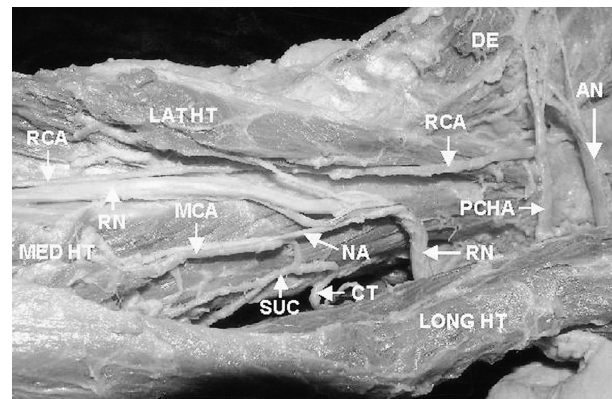
## Case Report

During routine dissections for first-year MBBS students of Melaka Manipal Medical College, Manipal, a case of unusual origin of the arteries of the arm was encountered. The limb belonged to the left side of an approximately 50-year-old male cadaver.

It was observed that the radial collateral artery arose from the posterior circumflex humeral artery in the quadrangular space, and passed downwards posterior to the teres major, deep to the lateral head and lateral to the long head of the triceps (Figure 1).

On reaching the spiral groove, the artery ran along the radial nerve. Its further course was similar to that of normal radial collateral artery.

In the same limb, we also observed that the superior ulnar collateral and middle collateral arteries arose from a common trunk from the brachial artery.



**Figure 1.** Origin of the radial collateral artery (RCA) from the posterior circumflex humeral artery (PCHA). Also seen are the superior ulnar collateral artery (SUCA) and middle collateral artery (MCA) arising from the common trunk (CT). AN = axillary nerve; RN = radial nerve; LONG HT = long head of triceps; MED HT = medial head of triceps; LAT HT = lateral head of triceps; NA = nerve to anconeus; DE = deltoid.

\*Correspondence to: Dr. K.G. Mohandas Rao, Department of Anatomy, Melaka Manipal Medical College (Manipal Campus), International Centre for Health Sciences, Manipal 576104, Karnataka State, India.  
 E-mail: mohandaskg@gmail.com • Received: August 15, 2005 • Accepted: February 13, 2006

The course of the superior ulnar collateral artery was similar to that of a normal one. However, the middle collateral artery accompanied the radial nerve through the lower triangular space to reach the spiral groove. Its further course was normal.

## Discussion

The radial collateral artery vascularizes the posterolateral part of the arm.<sup>1</sup> According to Meirer et al,<sup>2</sup> it is the main artery supplying the lateral forearm flap, which is used for covering minor to moderate-sized defects during plastic surgery. Variation in the origin of the radial collateral artery is not usual. Casoli et al<sup>1</sup> found that it was always a branch of the profunda brachii artery in 69 upper limbs dissected by them. However, Patnaik et al<sup>3</sup> found 1 case out of 50 limbs where it arose as a direct branch of the brachial artery. Our finding of the radial collateral artery as a branch of the posterior circumflex humeral artery is being reported for the first time.

The posterior circumflex humeral artery is the main artery that supplies the upper humeral epiphysis,<sup>4</sup> a major part of the deltoid,<sup>5</sup> and the rotator cuff and capsule of the shoulder joint.<sup>6</sup> It is relatively more vulnerable in the quadrangular space. Traumatic aneurysm of this artery has been reported to be a cause of ischemia of the arm and hand in volleyball players.<sup>7</sup> Quadrangular space syndrome (a condition characterized by tenderness over the quadrangular space and shoulder pain radiating to the arm), caused by the compression of axillary nerve and posterior circumflex humeral artery, has been reported.<sup>8</sup> Okino et al<sup>9</sup> and Cormier et al<sup>10</sup> have reported similar cases of quadrangular space syndrome where the posterior circumflex humeral artery was found occluded. Occlusion of the posterior circumflex humeral artery is considered to be one of the causes of shoulder pain.<sup>10</sup> In such cases of occlusion, it is necessary to know this unusual branching of the radial collateral

artery from the posterior circumflex humeral artery, where ischemia can even be found in the lateral part of forearm and elbow, leading to more extensive pain.

In such cases of quadrangular space syndrome, if patients do not respond to conservative treatment, surgical decompression of the space through the posterior approach should be considered.<sup>11</sup> In such operations, it is essential for the surgeon to be aware of this abnormal origin and the course of the radial collateral artery as reported in this case.

## References

1. Casoli V, Kostopoulos E, Pelissier P, Caix P, Martin D, Baudet J. The middle collateral artery: anatomic basis for the extreme lateral arm flap. *Surg Radiol Anat* 2004;26:172-7.
2. Meirer R, Schrank C, Putz R. Posterior radial collateral artery as the basis of the lateral forearm flap. *J Reconstr Microsurg* 2000;16:21-4.
3. Patnaik VVG, Kalsey G, Singla Rajan K. Branching pattern of brachial artery: a morphological study. *J Anat Soc India* 2002;51:176-86.
4. Dupare F, Muller JM, Freger P. Arterial blood supply of the proximal humeral epiphysis. *Surg Radiol Anat* 2001;23:185-90.
5. Hue E, Gagey O, Mestdagh H, Fontaine C, Drizenko A, Maynou C. The blood supply of the deltoid muscle. Application to the deltoid flap technique. *Surg Radiol Anat* 1998;20:161-5.
6. Determe D, Rongieres M, Kany J, Glasson JM, Bellumore Y, Mansat M, Becue J. Anatomic study of the tendinous rotator cuff of the shoulder. *Surg Radiol Anat* 1996;18:195-200.
7. Vlychou M, Spanomichos G, Chatziioannou A, Georganas M, Zavras GM. Embolization of traumatic aneurysm of the posterior circumflex humeral artery in a volleyball player. *Br J Sports Med* 2001;35:136-7.
8. Chautems RC, Glauser T, Waeber Fey MC, Rostan O, Barraud GE. Quadrilateral space syndrome: case report and review of the literature. *Ann Vasc Surg* 2000;14:673-6.
9. Okino S, Miyaji H, Matoba M. The quadrilateral space syndrome. *Neuroradiology* 1995;37:311-2.
10. Cormier PJ, Matalon TA, Wolin PM. Quadrilateral space syndrome: a rare cause of shoulder pain. *Radiology* 1998;167:797-8.
11. Cahill BR, Palmer RE. Quadrilateral space syndrome. *J Hand Surg* 1993;8:65-9.