

Posterolateral Lumbar Spinal Fusion with Autogenous Bone Chips from Laminectomy Extended with OsteoSet®

Chien-Lung Chen¹, Chien-Lin Liu^{2,3*}, Shih-Sheng Sun¹, Pu-Yu Han¹, Chi-Sheng Lee¹, Wai-Hee Lo¹

¹Department of Orthopedics, Lo-Tung Pohai Hospital, Yilan, ²Department of Orthopedics and Traumatology, Taipei Veterans General Hospital, and ³National Yang-Ming University School of Medicine, Taipei, Taiwan, R.O.C.

Background: This study was conducted to evaluate posterolateral lumbar fusion with autogenous corticocancellous bone chips from the laminae and spinous processes extended with OsteoSet® instead of cancellous bone from the iliac crest.

Methods: A total of 124 patients who underwent posterior decompression and posterolateral fusion with instrumentation between May 2001 and December 2003 were analyzed retrospectively. The study population comprised 49 males and 75 females with a mean age of 66 ± 9.5 years. In all the patients, corticocancellous bone chips from laminectomy and OsteoSet® were used as the graft material. There was no cancellous bone harvested from the iliac crest. The follow-up period was 28 ± 7.1 months.

Results: The overall union rate was 91%, and the average union time was 3.9 months. There were 3 complications, including 2 patients with dura tear, and 1 with deep infection. At the final follow-up, the good and excellent results were up to 83.9%.

Conclusion: Graft material from laminae and spinous processes extended with OsteoSet® is reliable and effective enough to replace the graft from the posterior iliac crest. [*J Chin Med Assoc* 2006;69(12):581–584]

Key Words: bone graft, laminectomy, OsteoSet®, posterolateral fusion

Introduction

Harvesting iliac crest bone graft for posterolateral lumbar fusion is considered the gold standard in spinal fusion surgery. Autogenous bone graft, which is osteoconductive, osteoinductive and possibly osteogenic due to osteocytes and mesenchymal stem cells, remains the best source of grafting material. Unfortunately, the harvest of autograft bone is associated with high rates of postoperative morbidity, such as increase in surgical time and blood loss, infection, numbness or reduced structural integrity.¹ Kurz et al found that 15% of patients had donor-site pain that persisted for more than 3 months.²

Allograft bone is the most frequently used autograft alternative; however, the lack of osteogenicity may decrease osteoinductance and increase infection rates. The higher rates of infection due to allograft bone make us hesitate. It is also difficult to obtain allograft bone in Taiwan because of the insufficiency of bone banks.

With the increasing number of spine fusion surgeries during this decade, arthrodesis of the spine has become the most common reason for autologous bone graft harvesting. Revision surgeries as well as osteoporotic bone will lead the spine surgeon to face the challenge of unavailable autogenous bone graft. In addition, obtaining a sufficient amount of local graft from the laminae and spinous processes for spinal fusion is not easy. Fortunately, biosynthetic composite bone grafts have been developed, such as OsteoSet®. We used it to extend the insufficient amount of graft obtained from laminectomy. There was no graft harvested from the iliac crest in our study group.

Methods

Posterolateral fusion was performed in 124 patients (49 males, 75 females) with degenerative spondylolisthesis

*Correspondence to: Dr Chien-Lin Liu, Department of Orthopedics and Traumatology, Taipei Veterans General Hospital, 201, Section 2, Shih-Pai Road, Taipei 112, Taiwan, R.O.C.

E-mail: clliu@vghtpe.gov.tw • Received: November 18, 2005 • Accepted: November 13, 2006

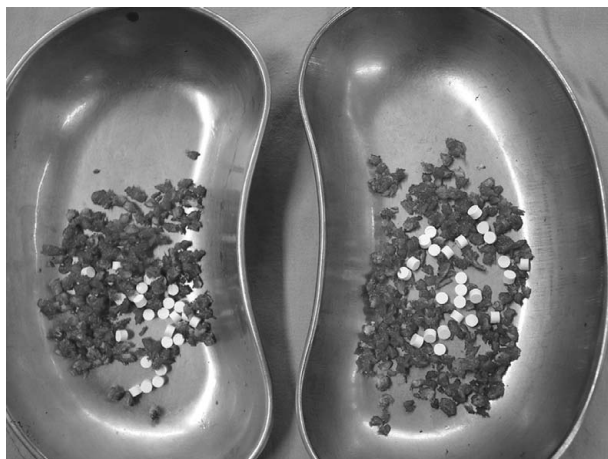


Figure 1. Grafts consist of a mixture of OsteoSet® and morcellized corticocancellous bone chips from laminae and spinous processes with soft tissue cleaned.

and spinal canal stenosis between May 2001 and December 2003. The mean age was 66 ± 9.5 years. Laminectomy was performed in all cases based on the findings of spinal stenosis from magnetic resonance imaging or computed tomography. Arthrodesis was performed in all cases in which instability was noted from dynamic view. In revision surgery, cases of fusion without instrumentation or the use of autogenic iliac crest bone grafts were excluded. All patients received posterior decompression and instrumented posterolateral fusion. Transpedicular instrumentation system was used in all cases, including CD® (Cotrel-Dubousset; Medtronic Sofamor Danek, Memphis, TN, USA) in 87 cases, PROT® (Merries International Inc., Taipei, Taiwan) spinal system in 27 cases, and RPS® (Rod & Plate System; Howmedica Osteonics Corp., Allendale, NJ, USA) in 10 cases. OsteoSet® (Wright Medical, Arlington, TN, USA), a calcium sulfate ceramic material, was used as the graft extension. The harvested corticocancellous bone was cleaned of soft tissue, morcellized, mixed with OsteoSet® (Figure 1), and placed over the decorticated transverse process and intertransverse membrane. There were 38 cases of single-level fusion, 65 of 2-level fusion, 15 of 3-level fusion, 4 of 4-level fusion and 2 of 5-level fusion. We used 5 mL OsteoSet® for single-level and 2-level surgery, 10 mL for 3-level and 4-level surgery, and 15 mL for 5-level surgery.

Results

Anteroposterior and lateral radiographs were obtained postoperatively (Figure 2) every month for the first 6 months and then every 3 months thereafter. Solid fusion

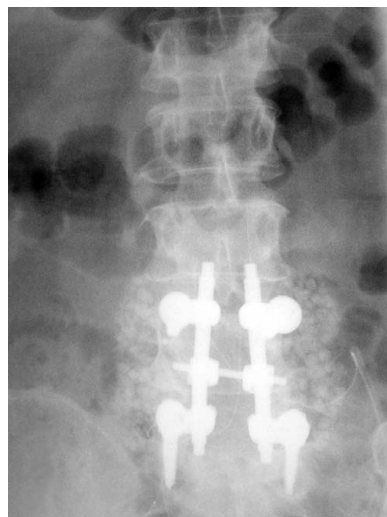


Figure 2. Initial postoperative anteroposterior radiograph of an L4–S1 posterior decompression and posterior lumbar fusion with lamina chips plus OsteoSet® 5 mL.

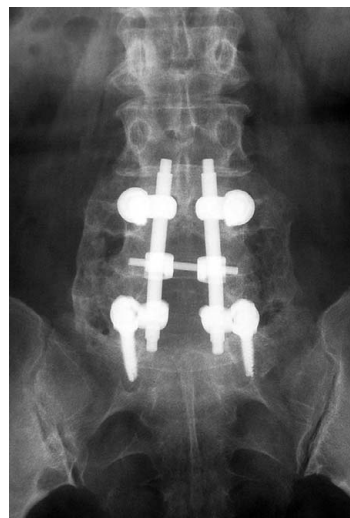


Figure 3. Solid union is observed at the 6-month follow-up; OsteoSet® is absorbed.

was defined as the presence of bilateral continuous bone trabeculae among the fixed segments (Figure 3). Nonunion was defined as “a visible gap, graft collapsed, implants loosening”, as described by Steinman and Herowitz in 1992.³ Dynamic view was not used to judge union or nonunion in our study because the instrument could provide stability as well as the graft. In fact, there were few definite criteria of instability with regard to the instrumented spinal segment. In our study, it was difficult to get accurate dynamic films for some elderly patients.

The clinical results depended on patients’ satisfaction and their use of nonsteroidal anti-inflammatory drugs (NSAIDs), which Greenough described in 1996.⁴ There were 4 grades: (1) *excellent*, very satisfied, unrestricted

Table 1. Results of union and clinical satisfaction

Fusion level	Result	Excellent	Good	Fair	Poor	Total
Single-level	Union	21	11	5	0	37
	Nonunion	0	1	0	0	1
2-level	Union	38	12	6	0	56
	Nonunion	4	2	1	2	9
3-level	Union	7	4	3	0	14
	Nonunion	0	0	1	0	1
4-level	Union	2	1	1	0	4
	Nonunion	0	0	0	0	0
5-level	Union	1	0	1	0	2
	Nonunion	0	0	0	0	0
Total		73	31	18	2	124

activities, complete or almost complete relief, no NSAIDs required postoperatively; (2) *good*, occasional discomfort, a good deal of relief and patients took NSAIDs occasionally; (3) *fair*, intermittent discomfort, not very satisfied, only a little improvement compared with preoperation, restricted activities; (4) *poor*, failure, no relief or worse than before, marked discomfort, need NSAIDs, occasional narcotic medication.

The mean follow-up period in this study was 28 ± 7.1 months (range, 15–48 months). No apparent clear zone was noted around the pedicle screws in all patients. The OsteoSet[®] was well absorbed in all cases by the time of the last follow-up. In single-level fusion, there were 38 cases with 97.4% (37/38) union rate and 86.8% (33/38) good and excellent satisfaction. In 65 cases of 2-level fusion, there were 86.2% (56/65) union rate and 86.2% (56/65) good and excellent satisfaction. We had 15 3-level fusion cases, with 93% (14/15) union rate and 73% (11/15) good and excellent satisfaction. In 4-level fusion, there were only 4 cases, with 100% (4/4) union rate and 75% (3/4) good and excellent satisfaction. Regarding 5-level fusion, there were 2 cases; the union rate was 100% (2/2) and the good and excellent rate was 50% (1/2).

The overall rate of solid union was 91% (113/124). The average union time was 3.9 months (range, 2–9 months). In the union group, there were 85.8% (97/113) with excellent and good results. In the nonunion group, there were 63.6% (7/11) with excellent and good results. Details of the results are shown in Table 1. Regarding overall satisfaction, there were 58.9% (73/124) excellent, 25% (31/124) good, 14.5% (18/124) fair, and 1.6% (2/124) poor. The clinical satisfaction rate for excellent and good was 83.9% (104/124).

There were 3 operative complications. One patient had deep wound infection, which was treated

successfully by removal of the instrument. The other 2 cases had dura tear that occurred during surgery, and no sequelae were noted later.

Discussion

Plain radiographs are the most commonly used imaging technique to evaluate for union or nonunion. Sometimes, the postoperative evaluation is difficult for the hardware disturbance. Steinman described, “The observation of bridging trabecular bone means the consolidation of bone graft. The criteria to diagnose nonunion are a visible gap, graft collapsed, and implant loosening. The lateral view shows radiolucency around the implant, indicating loosening.”³

NSAIDs used postoperatively have been shown to have a strong negative influence on both fusion rates and clinical success rates.⁵ The more NSAIDs used, the poorer the clinical satisfaction that is noted.

In general, it is true that not every fusion leads to a good result and not every failed fusion is symptomatic.^{6,7} There are 3 basic principles of fusion surgery. The first is immobilization. Fischgrund et al reported a study showing that instrumentation improved the fusion rate (83% vs. 45%).⁸ Posterolateral fusion with the addition of pedicle instrumentation could increase the fusion rate.^{5,9} Instrumentation systems decrease motion and assist spinal fusion.^{8,10} The second principle is fusion bed. If there is fibrous tissue interposition in the fusion bed, the bone graft cannot form a contiguous fusion mass. The third principle is bone graft. Auto-genous iliac cancellous bone is the best source of graft. In 1992, Fernyhough et al reported a donor site complication rate of 28–31% depending on the choice of incision, including persistent donor site pain, neurovascular

damage, infection and even subsequent pelvic fractures.¹¹ We used corticocancellous bone chips from laminectomy and OsteoSet[®] as the graft material. There was no graft harvested from the iliac crest, and that helped to avoid these complications.

Autogenous iliac bone graft is considered the gold standard in spinal fusion and the most effective form of graft material. However, the limited sources and significant donor site morbidity associated with autologous bone graft harvesting have raised great interest in alternatives. OsteoSet[®] is purely osteoconductive and used in conjunction with corticocancellous bone from laminae and spinous processes, which provide osteoinductive and osteogenic capacity. The rate of resorption is consistent with that of new bone growth.¹² In 2005, Chen et al reported a study where autologous iliac crest bone graft was placed in 1 posterolateral gutter, while on the other side, an equal quantity of autogenous laminectomy bone supplemented with calcium sulfate was placed.¹³ There was no significant difference between the fusion rate and sizes of the fusion bone mass. Kasai et al reported using different mixture ratios of local bone to bone substitute, which were 2:1, 1:1 and 1:2, while the total volume of graft bone was the same; they found no differences in the union rates among the different ratios.¹⁴ The amount of graft is more important than the mixture ratios of the graft. Insufficiency of supply from local lamina graft is the pertinent issue. However, higher rates of pseudoarthrosis are noted in posterolateral fusion.¹⁵ The risk of fusion failure was reported as 10–65%.^{8,16,17} Some factors, including mechanical instability, infection, smoking, and some medications like NSAIDs, are known to increase the failure rate of arthrodesis. Fusion failure has been associated with poor clinical results. Fischgrund reported that long-term clinical outcome was excellent or good in 86% of patients with solid union, but only 56% of patients developed a pseudoarthrosis ($p=0.01$).¹⁸ This result is similar to that of our study.

In conclusion, lumbar posterolateral fusion can be successfully achieved by corticocancellous bone chips from laminectomy extended with OsteoSet[®]. The donor site of the posterior iliac crest bone is not needed if lumbar posterolateral fusion follows laminectomy. The clinical results have been quite promising. Although it is obvious that the quality of lamina graft is inferior to the graft harvested from the iliac crest, with addition of instrumentation, it is sufficient to produce a good outcome. Due to there being no harvested grafts from posterior iliac crest, there was no donor site morbidity. The operation time and blood loss during operation decreased. The need for early

postoperative analgesia was reduced, and the incidence of late postoperative donor site pain was avoided. The iliac bone could be preserved for the next surgery, which might need more grafts.

References

1. Fernyhough JC, Schimandle JJ, Weigel MC. Chronic donor site pain complicating bone graft harvesting from the posterior iliac crest for spinal fusion. *Spine* 1992;17:1474–80.
2. Kurz LT, Garfin SR, Booth RE. Harvesting autogenous iliac bone grafts. A review of complications and technique. *Spine* 1989;14:1324–31.
3. Steinman JC, Herowitz HN. Pseudoarthrosis of the spine. *Clin Orthop* 1992;284:80–90.
4. Greenough C. Outcome of fusion: assessment techniques and comparison of anterior fusion with posterior fusion. *Hosp Joint Dis* 1996;55:162–5.
5. Deguchi M, Rapoff AJ, Zdeblick TA. Posterolateral fusion for isthmic spondylolisthesis in adults: analysis of fusion rate and clinical results. *J Spinal Disord* 1988;1:459–64.
6. Lenke LG, Bridwell KH, Bullis D. Results of *in situ* fusion for isthmic spondylolisthesis. *J Spinal Disord* 1992;5:433–42.
7. Laueran WC, Bradford DS, Ogilvie JW. Results of lumbar pseudoarthrosis repair. *J Spinal Disord* 1992;5:149–57.
8. Fischgrund JS, Mackay M, Herkowitz HN. 1997 Volvo Award winner in clinical studies. Degenerative lumbar spondylolisthesis with spinal stenosis: a prospective, randomized study comparing decompressive laminectomy and arthrodesis with and without spinal instrumentation. *Spine* 1997;22:2807–12.
9. Hanley EN Jr. The indications for lumbar spinal fusion with and without instrumentation. *Spine* 1995;20:143–53.
10. Nork SE, Hu SS, Workman KL. Patient outcomes after decompression and instrumented posterior spinal fusion for degenerative spondylolisthesis. *Spine* 1999;24:561–9.
11. Fernyhough JC, Schimandle JJ, Wsigel MC. Chronic donor site pain complicating bone graft harvesting from the posterior iliac crest for spinal fusion. *Spine* 1992;17:1474–80.
12. Finkemeier CG. Bone grafting and bone graft substitutes. *J Bone Joint Surg Am* 2002;84:454–64.
13. Chen WJ, Tsai TT, Chen LH, Niu CC, Lai PL, Fu TS, McCarthy K, et al. The fusion rate of calcium sulfate with local autograft bone compared with autologous iliac bone graft for instrumented short-segment spinal fusion. *Spine* 2005;30:2293–7.
14. Kasai Y, Takegami K, Uchida A. Mixture ratios of local bone to artificial bone in lumbar posterolateral fusion. *J Spinal Disord Tech* 2003;16:31–7.
15. Baramki HG, Steffen T, Lander P, Chang M. The efficacy of interconnected porous hydroxyapatite in achieving posterolateral lumbar fusion in sheep. *Spine* 2000;25:1053–60.
16. France JC, Yaszemski MJ, Laueran WC. A randomized prospective study of posterolateral lumbar fusion: outcomes with and without pedicle screw instrumentation. *Spine* 1999;24:553–60.
17. Vaccaro AR, Patel T, Fischgrund J, Anderson DG, Truumees E, Herkowitz HN, Phillips F, et al. A pilot study evaluating the safety and efficacy of OP-1 putty (rhBMP-7) as a replacement for iliac crest autograft in posterolateral lumbar arthrodesis for degenerative spondylolisthesis. *Spine* 2004;29:1885–92.
18. Fischgrund JS. The argument for instrumented decompressive posterolateral fusion for patients with degenerative spondylolisthesis and spinal stenosis. *Spine* 2004;29:173–4.