

Vestibular Rehabilitation in a Patient with Whiplash-associated Disorders

Kwo-Shieng Tuo¹, Yuan-Yang Cheng², Chung-Lan Kao^{2,3*}

¹*Department of Physical Medicine and Rehabilitation, Kaohsiung Armed Forces General Hospital, Kaohsiung,*

²*Department of Physical Medicine and Rehabilitation, Taipei Veterans General Hospital, and*

³*National Yang-Ming University School of Medicine, Taipei, Taiwan, R.O.C.*

Whiplash-associated disorders are characterized by multiple physical complaints after a flexion-extension trauma to the neck. They are difficult to treat, and they often result in great impact on the patient's quality of life. In this paper, the comprehensive treatment of a patient with whiplash-associated disorders is presented. The purpose is to highlight the importance of accurate diagnosis and appropriate treatment plans to improve patients' quality of life. This 23-year-old woman experienced a traffic accident which caused severely painful neck disability, numbness over bilateral upper limbs, dizziness, double vision and loss of balance. Among these symptoms, dizziness was the problem that bothered the patient most. She received a comprehensive rehabilitation program including physical modalities, trigger point injections for relief of pain, as well as a vestibular rehabilitation program, which included exercises challenging and improving her balance function, head-eye coordination exercise, visual-ocular control exercise and sensory substitution-promoting exercises. She resumed her previous full-time work after 3 weeks of treatment. This successfully treated case illustrates the importance of correct diagnosis and appropriate treatment for patients who suffer from whiplash-associated disorders. [*J Chin Med Assoc* 2006; 69(12):591-595]

Key Words: dizziness, vestibular rehabilitation, whiplash-associated disorders

Introduction

Whiplash injury involves hyperextension of the neck followed by flexion, and typically results from an automobile accident when a person has been hit from behind. Although the majority of people recover within weeks or months, about 12–40% will persist in having complicated sequelae such as neck pain, stiffness, painful paresthesia of the neck and upper limbs, temporomandibular dysfunction, dizziness, tinnitus, and headaches, which are hard to elucidate and treat.¹ These symptoms are collectively called whiplash-associated disorders (WADs). Among these symptoms, dizziness may be most bothersome for the patient, and it is also most difficult to treat. As there is no specific medication for the treatment of dizziness, a special method of rehabilitation, so-called vestibular rehabilitation, has recently gained widespread attention. The concept of head, body and coordinated eye exercises

is applied for patients who suffer from motion intolerance and imbalance problems.² We report a patient with whiplash injury who had all of the symptoms described above. Satisfactory results were obtained after a comprehensive multidisciplinary rehabilitation program.

Case Report

A 23-year-old woman, who was generally healthy before, with no major surgical history or systemic disease, had a traffic accident while she was riding a motorcycle. She was hit from behind by a car, and was thrown into the air. Epistaxis with multiple lacerated wounds over her right-side face, nose, and limbs were noted. No initial loss of consciousness was experienced, but she felt dizziness with painful numbness of bilateral upper limbs immediately after the impact. Physical examination in the emergency room revealed multiple lacerations over her

*Correspondence to: Dr Chung-Lan Kao, Department of Physical Medicine and Rehabilitation, Taipei Veterans General Hospital, 201, Section 2, Shih-Pai Road, Taipei 112, Taiwan, R.O.C.

E-mail: clkao@vghtpe.gov.tw • Received: March 14, 2006 • Accepted: July 14, 2006

right-side face and nose, and all 4 limbs. Generalized decreased muscle power with poor neck control was also noted. Radiographic filming of her skull and pelvis were arranged, but no abnormal findings were obtained. She was discharged subsequently after simple wound treatment.

Three days later, the patient noted impaired short-term memory, poor orientation, and difficulty in recognizing people. Severe dizziness, neck pain and double vision were also present. She was sent to our emergency room where brain computed tomography (CT) and skull radiography revealed no significant findings except for right orbital fracture. An emergent operation for the orbital fracture was suggested, but the patient refused.

Four months later, she visited the outpatient clinic of the Department of Physical Medicine and Rehabilitation with the chief complaints of neck pain, limited range of neck motion, double vision, hearing impairment, imbalance and numbness over bilateral upper limbs. She did not complain of any further memory or orientation disturbance. Her neck pain could be elicited by all directions of neck motion. She also complained of episodic dizziness lasting for minutes to hours without rotational vertigo, as well as vague unsteadiness and loss of balance. The unsteadiness could be induced by neck movement, and it was associated with increased neck pain. No spontaneous nystagmus was observed under room light and infra-red Frenzel goggles. Horizontal head-shaking and Dix-Hallpike positional tests all had negative findings. She was admitted to our ward for further examination and rehabilitation.

During admission, a series of studies including brain CT and pure tone audiometry were performed, which all showed normal results. Cervical spine magnetic resonance imaging (MRI) showed a bulging disc at the C6/7 level with mild spinal stenosis (Figure 1). A multidisciplinary rehabilitation program, including cervical traction, isometric neck muscle strengthening exercises, cervical spine mobilization technique, biofeedback relaxation training, hydrotherapy, activities of daily living training, and neuropsychosocial consultation, were arranged for her. The painful limited neck motion was much improved after neck muscle stretching and local injection of 3 mL 1% xylocaine once over trigger points that were carefully identified over bilateral cervical paraspinal muscles, upper trapezius, levator scapulae, and rhomboideus. The frequency and intensity of the patient's numbness over bilateral upper limbs also gradually decreased. Tinetti falls efficacy scale³ was applied for the assessment of balance function. Her total score was 24, indicating that she had a moderate risk for falling. Another assessment scale for falling that was used

was the Dynamic Gait Index (DGI).⁴ The patient's total DGI score on the day of admission was 12, indicating a high risk for falling.

The vestibular rehabilitation training program was started, with exercises challenging and training her balance function such as sitting on an elastic ball with bouncing (Figure 2), stepping on a trampoline (Figure 3), and standing on a tilting board with movement

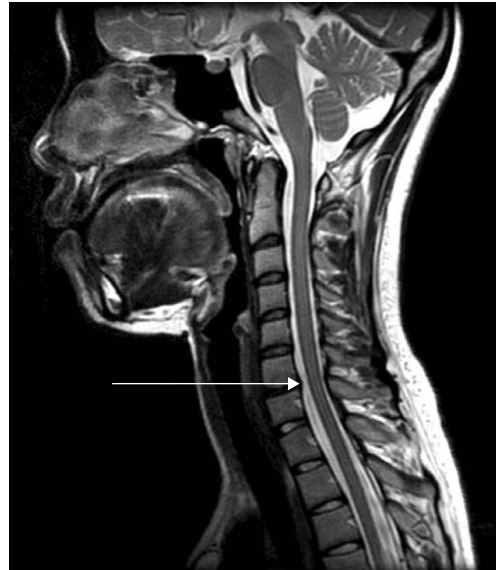

Figure 1. Magnetic resonance imaging of the cervical spine shows only a bulging disc at the C6/7 level with mild spinal stenosis. As the arrow indicates, the black-sigaled space between C6 and C7 is protruding into the white-sigaled spinal canal filling with cerebrospinal fluid.



Figure 2. Patient sits on an elastic ball with bouncing as a sensory substitution-promoting exercise and postural strategy practice.

in coronal and sagittal directions (Figure 4). In addition, programs that included head-eye coordination and visual-ocular control exercises with other sensory substitution-promoting exercises were also taught to the patient. Her dizziness persisted even after 3 weeks of the intensive rehabilitation program, but her balance function improved according to the patient's subjective description of her daily activities and improved performance of rehabilitation exercises.

The patient resumed her previous full-time work after 3 weeks of the rehabilitation program. She

continued receiving physical therapy as an outpatient. One and a half years after the injury, the patient continued to complain of occasional mild dizziness, but it did not affect her daily activities. Excessive neck flexion and extension induced dizziness, but her neck pain had almost completely disappeared. The patient was evaluated again using the Tinetti scale and DGI, and her total scores were 31 and 17, respectively, both indicating a low risk for falling.

Discussion

Whiplash injury is notorious for its constellation of chronic symptoms that are difficult to treat. These symptoms are generally called WADs. As Rodriguez et al mentioned in their comprehensive review,⁵ WADs may include neck pain, headache, dizziness, paresthesia, temporomandibular dysfunction, visual disturbance, memory impairment, concentration problems, and psychosocial distress. These symptoms may cause greater functional disability and psychologic stress than anticipated. Among these symptoms, subjective dizziness with subsequent impaired balance function may be the problem that affects patients most. It is also more difficult to evaluate and treat clinically, so deserves extra attention and discussion.

Neck pain is relatively common in whiplash-injured patients. Painful inhibition of muscles results in subsequent limited range of motion. Although the reason for neck pain may be psychiatric somatization,⁶ other explanations such as myofascial pain secondary to cervical



Figure 3. Patient steps on a trampoline as a sensory substitution-promoting exercise and postural strategy practice.

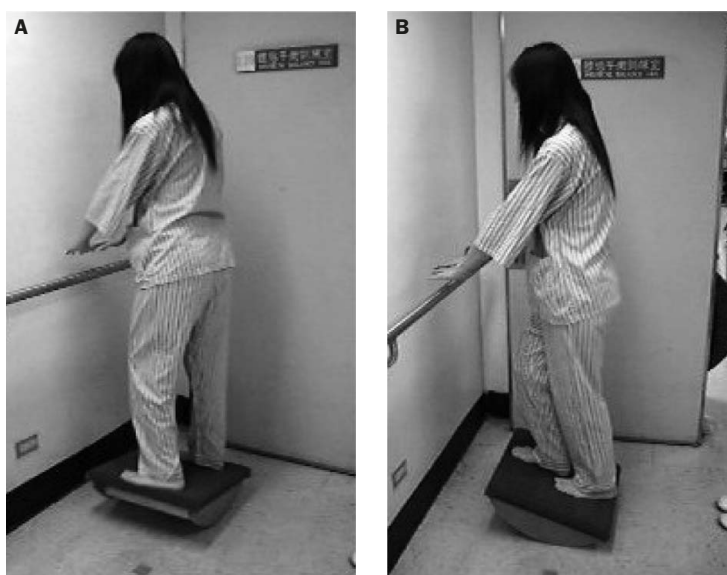


Figure 4. Patient stands on a tilting board with movement in (A) coronal direction and (B) sagittal direction as a sensory substitution-promoting exercise and postural strategy practice.

sprain, cervical disc herniation, cervical spondylolisthesis, cervical spine fracture, and injury to the cervical zygoapophyseal facet joint are also possible reasons. The richly innervated cervical facet joints are most vulnerable during the initial neck hyperextension stage while being hit from behind, and it has been considered to be the most possible reason responsible for neck pain in whiplash-injured patients.⁵ Therefore, treatments such as local anesthetic block of the medial branch of the cervical dorsal rami which supply only the zygoapophyseal joints,⁷ percutaneous radiofrequency neurotomy for facet joint innervation,⁸ and intra-articular corticosteroid or anesthetic injection for facet joints⁹ have been suggested in the literature. In this case, cervical spine MRI showed a bulging disc at the C6/7 level with mild spinal stenosis, but her numbness pattern did not correspond with C6/7 dermatome. Therefore, the diagnosis of myofascial pain-induced numbness was considered first. After xylocaine injection at the trigger points over bilateral cervical paraspinal muscles, upper trapezius, levator scapulae, and rhomboideus, the patient's symptoms of pain and numbness resolved completely.

The Tinetti fall efficacy scale and the DGI are commonly used to evaluate patients' balance function. The Tinetti fall efficacy scale³ includes a total balance domain and a gait balance domain with 13 and 9 functional movements to evaluate, respectively. Scoring on the scale is based on a 2-point scale from 0 to 2, with 0 indicating severe impairment and 2 indicating normal ability. The maximum total score is 37. Scores >31 indicate a low risk for falling, and scores <25 indicate a high risk for falling. The DGI⁴ includes 8 functional movements to evaluate, such as walking while changing speed and turning the head, walking over and around obstacles, and stair climbing. Scoring of the DGI is based on a 4-point scale from 0 to 3, with 0 indicating severe impairment and 3 indicating normal ability. The maximum total score is 24, and scores >19 indicate a low risk for falling.¹⁰ As indicators of a patient's balance function, both scales are clinically practical in evaluating the falling risk in daily activities of living.

Dizziness is a frequent complaint after whiplash injury. Damage to various structures such as vestibular apparatus, brainstem, cerebellum, vertebral artery, and cervical proprioceptive receptors during whiplash injury are postulated as causes for dizziness. If neither subjective vertigo complaint nor nystagmus are present, then vestibular dysfunction is less likely. If brain imaging studies and other cerebellar function tests are normal at the same time, which is usually the case in whiplash-injured patients, cervicogenic dizziness may be the most likely explanation.¹¹ During whiplash injury, extensive damage to neck muscles and joints is highly possible,

which may cause proprioceptive receptor dysfunction. The abnormal proprioceptive signal from the neck conflicts with visual and vestibular signals, and a sensation of dizziness arises. In this patient, diplopia resulting from orbital fracture may be another cause of her dizziness. However, the patient refused any orbital surgery. Therefore, treatment could only rely on a long-term vestibular rehabilitation program.^{12,13} The training program included: (1) head-eye coordination exercise: eye focused on a fixed or moving target while moving head from side to side; (2) visual-ocular control exercise to train smooth pursuit and saccade eye movement; (3) adaptation and habituation exercise for motion-provoked dizziness symptoms; (4) sensory substitution-promoting exercises such as progressive challenge progressing from walking with support to walking on foam with head movement; and (5) postural strategy practicing exercises such as ankle response, hip response, stiffening response, counterbalance response, stepping response, grabbing response and rescue response. For our patient, the training program we arranged included activities such as sitting on an elastic ball with bouncing (Figure 2), stepping on a trampoline (Figure 3), and standing on a tilting board with movement in coronal and sagittal directions (Figure 4), which are sensory substitution-promoting and postural strategy practicing exercises. These vestibular rehabilitation programs utilize the plasticity of the central nervous system by means of adaptation, habituation and substitution to reorganize balance perception while training postural strategy in case of falling. Our patient's balance improved after the exercises, suggesting the significant role of vestibular rehabilitation programs in improving patients' quality of life. The risk of falling also decreased according to the DGI evaluation. The improved DGI score was compatible with the results described in a previous report.¹⁴

In conclusion, WADs are considered to be some of the most difficult problems to diagnose and treat. The symptoms are mostly chronic, often resulting in great financial and mental burdens to the patient, patient's family and society. However, if the correct diagnosis for the symptoms can be made, some of the problems can be successfully treated. Vestibular rehabilitation program focusing on the adaptation and habituation of the subjective dizziness and imbalance sensation can be considered as an alternative treatment strategy to treat dizziness in whiplash-injured patients.

References

1. Barnsley L, Lord S, Bogduk N. Whiplash injury. *Pain* 1994; 58:283-307.

2. Michael CS, Susan JH. Vestibular rehabilitation. In: O'Sullivan SB, Schmitz TJ, eds. *Physical Rehabilitation Assessment and Treatment*, 4th edition. Philadelphia: FA Davis Company, 2001: 821–41.
3. Tinetti ME, Richman D, Powell L. Falls efficacy as a measure of fear of falling. *J Gerontol* 1990;45:239–43.
4. Shumway-Cook A, Baldwin M, Polissar NL, Gruber W. Predicting the probability for falls in community-dwelling older adults. *Phys Ther* 1997;77:812–9.
5. Rodriguez AA, Barr KP, Burns SP. Whiplash: pathophysiology, diagnosis, treatment, and prognosis. *Muscle Nerve* 2004;29: 768–81.
6. Guez M, Brannstrom R, Nyberg L, Toolanen G, Hildingsson C. Neuropsychological functioning and MMPI-2 profiles in chronic neck pain: a comparison of whiplash and non-traumatic groups. *J Clin Exp Neuropsychol* 2005;27:151–63.
7. Lord SM, Barnsley L, Wallis BJ, Bogduk N. Chronic cervical zygoapophyseal joint pain after whiplash: a placebo-controlled prevalence study. *Spine* 1996;21:1737–44.
8. Lord SM, Barnsley L, Wallis BJ, McDonald GJ, Bogduk N. Percutaneous radio-frequency neurotomy for chronic cervical zygoapophyseal-joint pain. *N Engl J Med* 1996;335:1721–6.
9. Barnsley L, Lord SM, Wallis BJ, Bogduk N. Lack of effect of intraarticular corticosteroids for chronic pain in the cervical zygoapophyseal joints. *N Engl J Med* 1994;330:1047–50.
10. Whitney SL, Hudak MT, Marchetti GF. The dynamic gait index relates to self-reported fall history in individuals with vestibular dysfunction. *J Vestib Res* 2000;10:99–105.
11. Treleaven J, Jull G, Sterling M. Dizziness and unsteadiness following whiplash injury: characteristic features and relationship with cervical joint position error. *J Rehabil Med* 2003;35: 36–43.
12. Revel M, Minguet M, Gregoy P, Vaillant J, Manuel JL. Changes in cervicocephalic kinesthesia after a proprioceptive rehabilitation program in patients with neck pain: a randomized controlled study. *Arch Phys Med Rehabil* 1994;75:895–9.
13. Shailesh SP, Champa VB. Vestibular rehabilitation. In: Joel AD, Bruce MG, Nicolas EW, eds. *Physical Medicine and Rehabilitation Principle and Practice*, 4th edition. Philadelphia: Lippincott Williams & Wilkins, 2005:957–73.
14. Brown KE, Whitney SL, Wrisley DM, Furman JM. Physical therapy outcomes for persons with bilateral vestibular disease. *Neurol Res* 2000;24:181–2.