

Villous Adenoma of the Ureter with Manifestation of Mucus Hydronephrosis

Chi-Min Shih¹, Sheng-Chuan Wu^{2*}, Chueng-Chen Lee³, Chin-Chen Pan^{4,5}

¹Division of Anatomic Pathology, St Joseph's Hospital, ²Division of Urology and ³Department of Radiology, Tzu-Ai General Hospital, Yunlin, ⁴Department of Pathology, Taipei Veterans General Hospital, and ⁵National Yang-Ming University School of Medicine, Taipei, Taiwan, R.O.C.

Ureteral tumor is prone to result in lumen obstruction. Villous adenoma is most frequently found in the colon and rectum, seldom in the urinary tract and even more rarely in the ureter or pelvis. Herein, we present a case of bilateral renal stones of more than 10 years' duration with the chief complaint of right flank pain. Obstruction of the right upper ureter with hydronephrosis was observed on sonography, computed tomography and retrograde pyelography. Ureteroscopy revealed papillary tumor obstructing the upper third of the ureter and inducing hydronephrosis with abundant mucoid content. The ureteral tumor proved to be villous adenoma by pathologic examination. It should be noted that ureteral villous adenoma may be related to previous enteric-type metaplastic mucosa or ureteritis glandularis, demonstrates profuse production of mucus, and may eventually undergo malignant transformation. [*J Chin Med Assoc* 2007;70(1):33–35]

Key Words: hydronephrosis, hydronephrosis, hydronephrosis, hydronephrosis, hydronephrosis, hydronephrosis, hydronephrosis, hydronephrosis, hydronephrosis, hydronephrosis

Introduction

Ureteral obstruction other than from stone impaction can be from tumorous lesions of the ureter, such as transitional cell carcinoma, papilloma, ureteritis glandularis, ureteritis cystica, and other inflammatory reactive lesions. Villous adenoma, characterized by mucous type glandular neoplastic cells arranged in sessile papillary architecture, is mainly found in the colon and rectum, but uncommonly develops in the urinary tract.^{1–4} It even more rarely occurs in the upper urinary tract.^{3,5} Herein, we present an unusual case of ureteral villous adenoma with abundant mucus production, inducing mucus retention in dilated proximal ureter and pelvis. The term *muconephrosis* has been used by Park et al⁶ to describe a case of renal pelvic villous adenoma with mucus-filled kidney.

Case Report

The patient was a 64-year-old man who had been suffering from recurrent bilateral renal stones for more

than 10 years, and who had undergone several treatments of extracorporeal shock wave lithotripsy. This time, he visited the urology clinic with the chief complaints of right flank pain, nausea and general discomfort. Urinalysis showed cloudy urine with 25–30 red blood cells/high power field (HPF) and 70–75 white blood cells/HPF. Serum blood urea nitrogen and creatinine were 22.5 mg/dL and 1.9 mg/dL, respectively. Sonography of the right kidney suggested severe hydronephrosis with thinned cortex. Retrograde pyelography revealed marked right hydronephrosis with filling defect and obstruction over the upper third of the ureter at the L3 level without stone in the obstructed lumen (Figure 1A). Computed tomography of the abdomen and pelvis with intravenous contrast revealed a few small stones over focal minor calyces of the right kidney, thinned cortex, severe hydronephrosis with higher mean value, 5–20 Hounsfield units (HU) of the fluid content, and eccentric wall thickening over the obstruction site of the right upper third ureter (Figure 1B). Ureteroscopic findings of the obstruction site showed papillary tumor arising from the ureteral mucosa. When the ureteroscope retrogradely

*Correspondence to: Dr Sheng-Chuan Wu, Division of Urology, Tzu-Ai General Hospital, 321-90, Sin-She, Si-Luo, Yun-Lin 648, Taiwan, R.O.C.
E-mail: alanodin0730@gmail.com • Received: March 3, 2006 • Accepted: November 21, 2006

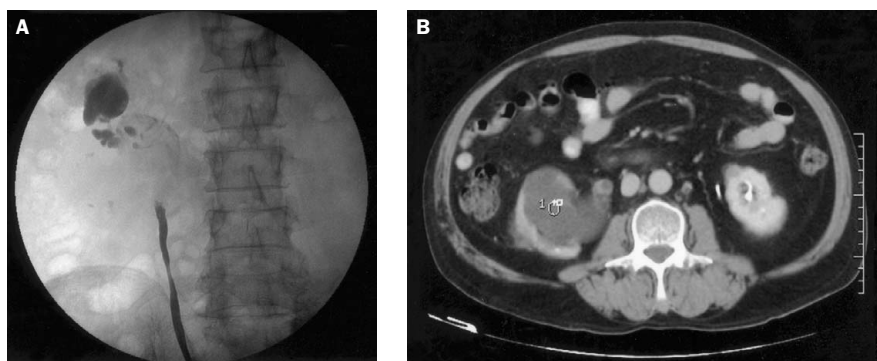


Figure 1. (A) Retrograde pyelography reveals obstruction over the right upper ureter and filling defect over the dilated proximal urinary tract. (B) Abdominal computed tomography shows partial obstruction over the upper ureter, with measurable mean value of 10.33 HU over the central portion of hydronephrotic content that is compatible with mucous substance.

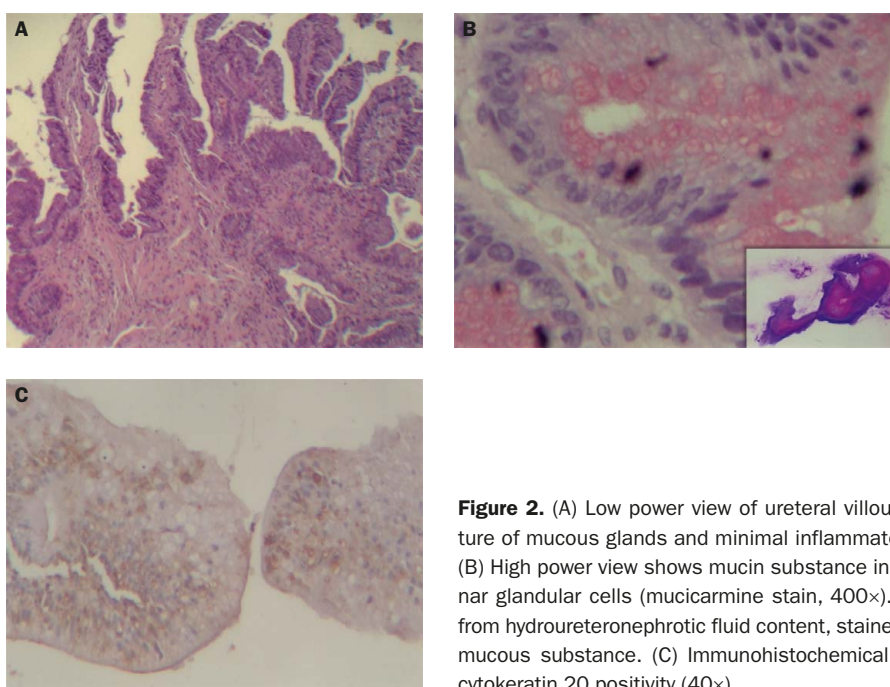


Figure 2. (A) Low power view of ureteral villous adenoma reveals finger-like architecture of mucous glands and minimal inflammatory change (hematoxylin & eosin, 40 \times). (B) High power view shows mucin substance in the cytoplasmic vacuoles of the columnar glandular cells (mucicarmine stain, 400 \times). Inset: scanning view of cytologic slide from hydronephrotic fluid content, stained with Liu's stain on dry smear, showing mucous substance. (C) Immunohistochemical study of the tumor cells show strong cytokeratin 20 positivity (40 \times).

passed the tumor region, abundant mucous substance could be drained out from the dilated ureter and pelvis by suction.

Pathologic examination of the ureteroscopic biopsy specimen showed villous adenoma (Figure 2A) with presence of basally located nuclei of the simple mucus columnar epithelium, and a few scattered goblet cells among the villiform glands. No dysplastic or malignant change was found. Neither ureteritis glandularis nor intestinal metaplasia could be found in the specimen. Positive mucicarmine stain (Figure 2B) and periodic acid-Schiff stain without diastase treatment were generally present in the cytoplasm of the villous glandular cells and goblet cells. Immunohistochemical studies of the tumor cells showed strong cytokeratin 20 (CK20) positivity (Figure 2C) and focal carcinoembryonic

antigen (CEA) positivity but negative staining for cytokeratin 7 (CK7). No concurrent colonic villous adenoma or adenocarcinoma was found 7 months after ureteral biopsy.

The patient continued to complain of dull right flank pain and passage of mucous substance in his urine, but he refused to receive any aggressive procedure, including percutaneous pyelostomy for the dilated right kidney shown on renal echographic studies twice since the last ureteroscopic biopsy 7 months ago.

Discussion

Except for colonic villous adenoma, villous adenoma can be uncommonly found in the urinary tract, ampulla

vater, bile duct, vagina and vulva.^{1,4,6-10} Villous adenomas of the urinary tract most commonly arise from the urinary bladder, followed by the urethra.³ There have been dozens of villous adenomas over the urinary bladder, fewer over the urethra, 2 cases of ureteral villous adenoma,^{1,2,4,5,11} 2 cases of pelvic villous adenoma,^{6,12} and 1 case of pelvic mucinous adenocarcinoma¹³ reported in the literature.

The typical clinical presentation of villous adenoma of the urinary tract is hematuria and irritative symptoms.⁴ Villous adenoma of the urinary tract is thought to arise from intestinal metaplasia of transitional epithelium after long-term irritation (such as stone impaction), chronic inflammation, or occasionally from bladder urachus.^{1,3} Although ureteritis glandularis and enteric-type epithelium may be precursors of villous adenoma,^{1,2,4,11} the specimen in this case was too small to find these precursors. Adenocarcinoma of the urinary tract has been diagnosed after initial detection of intestinal metaplasia or enteric-type adenoma for several years, but intestinal metaplasia is not a strong risk factor for the development of villous adenoma or adenocarcinoma.² Like villous adenomas of the colon and rectum, villous adenomas of the urinary tract also have CK20 and CEA positivity. CK7 positivity may be present in about 50% of urinary tract villous adenomas.⁴ In this villous adenoma, the antigenicity of CK7 had been lost.

Mucin production by villous adenoma of the urinary tract is often copious.^{1,6} Therefore, tumor growth with mucus retention was considered to be the main cause of ureteral obstruction in this patient. However, obstruction in the ureter from mucus-producing villous adenoma has not been previously reported in the literature. Because of the thin caliber of the ureteral lumen and profuse mucus production of the tumor, villous adenoma might result in early obstruction of the ureter and require total excision of this benign tumor. On account of only minimal inflammatory change over the fibrovascular stalks of villous adenoma, there was no strong evidence of associated stone impaction near this villous adenoma. However, we should follow up this patient's ureteral condition regularly, due to the possibility of residual or multifocal villous adenomas

of the urinary tract recurring or progressing to adenocarcinoma.^{1,2,5,11}

Acknowledgments

We would like to thank the staff of the Department of Pathology, Taipei Veterans General Hospital, for their kind help in the immunohistochemical staining of CK7 and CK20.

References

1. Seibel JL, Prasad S, Weiss RE, Bancila E, Epstein JI. Villous adenoma of the urinary tract: a lesion frequently associated with malignancy. *Human Pathol* 2002;33:236-41.
2. Adegboyega PA, Adesokan A. Tubulovillous adenoma of the urinary bladder. *Mod Pathol* 1999;12:735-8.
3. Tamboli P, Ro JY. Villous adenoma of the urinary tract: a common tumor in an uncommon location. *Adv Anat Pathol* 2000;7:79-84.
4. Cheng L, Montironi R, Bostwick DG. Villous adenoma of the urinary tract: a report of 23 cases, including 8 with coexistent adenocarcinoma. *Am J Surg Pathol* 1999;23:764-71.
5. Fernando Val-Bernal J, Torio B, Mayorga M, Garcia-Arranz P, Garijo MF. Concurrent tubulovillous adenoma and transitional cell carcinoma associated with diffuse gastric and intestinal metaplasia of the defunctioned ureter. *Pathol Res Pract* 2001;197:507-13.
6. Park S, Meng MV, Greenberg MS, Deng DY, Stoller ML. Muconephrosis. *Urology* 2002;60:344.
7. Motton G, Veraldi GF, Fracastoro G, Ricci F, Laterza E, Dorrucchi V, Cordiano C. Vater's papilla and periampullary area villous adenoma: personal experience about nine cases and review of the literature. *Hepatogastroenterol* 1996;43:448-55.
8. Chae BW, Chung JP, Part YN, Yoon DS, Yu JS, Lee SJ, Lee KS, et al. Villous adenoma of the bile ducts: a case report and a review of the reported cases in Korea. *Yonsei Med J* 1999;40:84-9.
9. Lee SE, Park NH, Park IA, Kang SB, Lee HP. Tubulovillous adenoma of the vagina. *Gynecol Oncol* 2005;96:556-8.
10. Vitrey D, Frachon S, Balme B, Golfier F. Tubulovillous adenoma of the vulva. *Obstet Gynecol* 2003;102:1160-3.
11. Channer JL, Williams JL, Henry L. Villous adenoma of the bladder. *J Clin Pathol* 1993;46:450-2.
12. Bos I, Lichtenauer HP, Frontzeck M. Intestinal type of villous adenoma of the kidney pelvis. *Pathologie* 1988;9:109-14. [In German]
13. Yip SK, Wong MP, Cheung MC, Li JH. Mucinous adenocarcinoma of the renal pelvis and villous adenoma of the bladder after caecal augmentation of the bladder. *Aust NZ J Surg* 1999;69:247-8.