

Management of Transorbital Brain Injury

Hung-Lin Lin, Han-Chung Lee, Der-Yang Cho*

Department of Neurosurgery, China Medical University Hospital, Taichung, Taiwan, R.O.C.

Transorbital brain injuries caused by metal bar penetration are uncommon and often cause serious damage without prompt treatment. Artifacts caused by the penetrating metal bar on computed tomography (CT) often obscure the actual brain damage along the path of penetration, and delayed treatment for the brain insult may result. We present 2 cases of transorbital brain injury following penetration by a metal bar. CT scans were initially performed on both patients. However, image resolution was poor and the extent of brain damage could not be ascertained due to severe artifacts associated with the metal bars. Both patients deteriorated in the emergency room and subsequently received surgical intervention. One patient recovered uneventfully. Unfortunately, the other patient died following surgery due to an unrecognized intracranial hemorrhage with brain herniation. Based on this experience, we recommend prompt surgical decompression with early CT follow-up to determine the true extent of brain damage and assess for possible delayed events in patients with extended transorbital brain injuries caused by metal bars. [*J Chin Med Assoc* 2007;70(1):36–38]

Key Words: computed tomography, head injury, metal bar, transorbital

Introduction

The majority of penetrating brain injuries in civilian neurosurgical practice are missile injuries.¹ Most non-missile penetrating brain injuries are caused by knives or cutting implements.² Transorbital brain injuries, although uncommon, can result in serious damage and even death if not promptly treated.³ Here, we present 2 cases of transorbital brain injury caused by penetration of a metal bar and discuss the surgical and radiologic management of such cases.

Case Reports

Case 1

An 83-year-old female fell forward while walking. An iron bar (1 cm in diameter and 20 cm long) penetrated her right orbit via the medial canthus. The patient remained conscious with vision loss in the right eye and left hemiplegia. Skull X-rays showed that the metal bar had penetrated through the roof of the orbit and was lodged high in the right parietal lobe (Figures 1A and 1B). Computed tomography (CT) scan of the brain showed marked artifacts over the

trajectory of the metal bar without obvious brain contusion hemorrhage (Figure 1C). The patient became lethargic following the CT scan examination. An emergent right frontotemporoparietal craniotomy was performed, and the intracranial part of the metal bar was removed from the entry site under direct visualization. The patient recovered, but with blindness in the right eye and left hemiparesis (Glasgow outcome scale score, 3).⁴

Case 2

A 55-year-old male fell forward onto the ground after being hit on the back by an object. A metal bar (2 cm in diameter and 30 cm long) penetrated his left orbit from the medial canthus, and his left eyeball protruded outside the orbital cavity. The patient remained conscious but deteriorated rapidly in the emergency room with decorticated posture. Brain CT revealed severe artifacts along the path of the metal bar, and left occipital bone fracture caused by direct compaction of the metal bar was also noted (Figure 2). Emergent right frontotemporoparietal craniotomy was performed, and the intracranial part of the metal bar was removed under direct visualization from the entry point without marked resistance. No obvious brain contusion

*Correspondence to: Dr Der-Yang Cho, Department of Neurosurgery, China Medical University Hospital, 2, Yu-Der Road, Taichung 404, Taiwan, R.O.C.

E-mail: linhunglin0405@yahoo.com.tw • Received: April 6, 2006 • Accepted: December 5, 2006

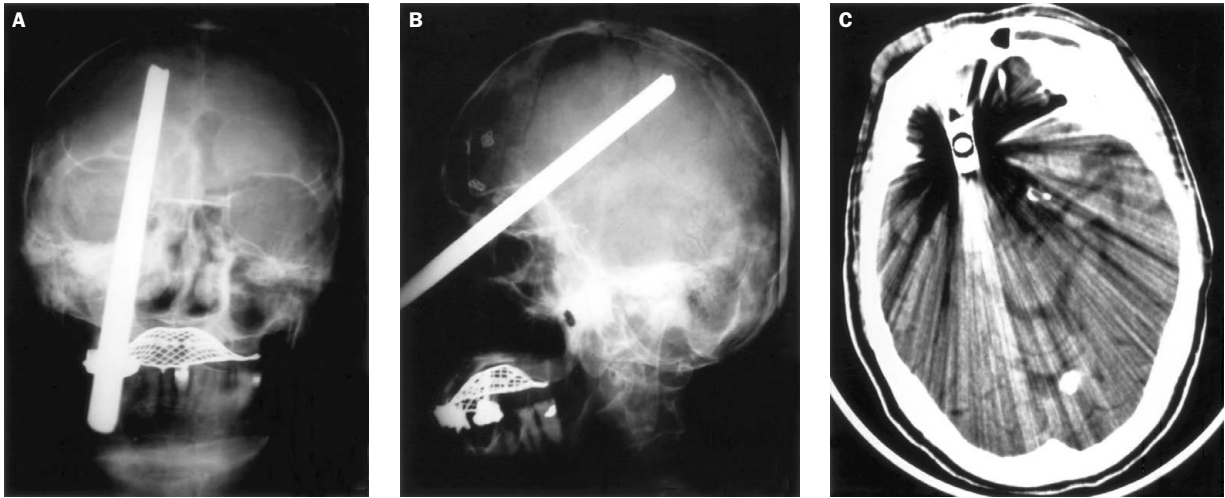


Figure 1. Skull X-rays of case 1 show that the skull is penetrated by a metal bar through the medial canthus of the right eye and through the orbital roof into the skull vertex: (A) anteroposterior view; (B) lateral view. (C) Computed tomography reveals marked artifacts but visible basal cisterns.

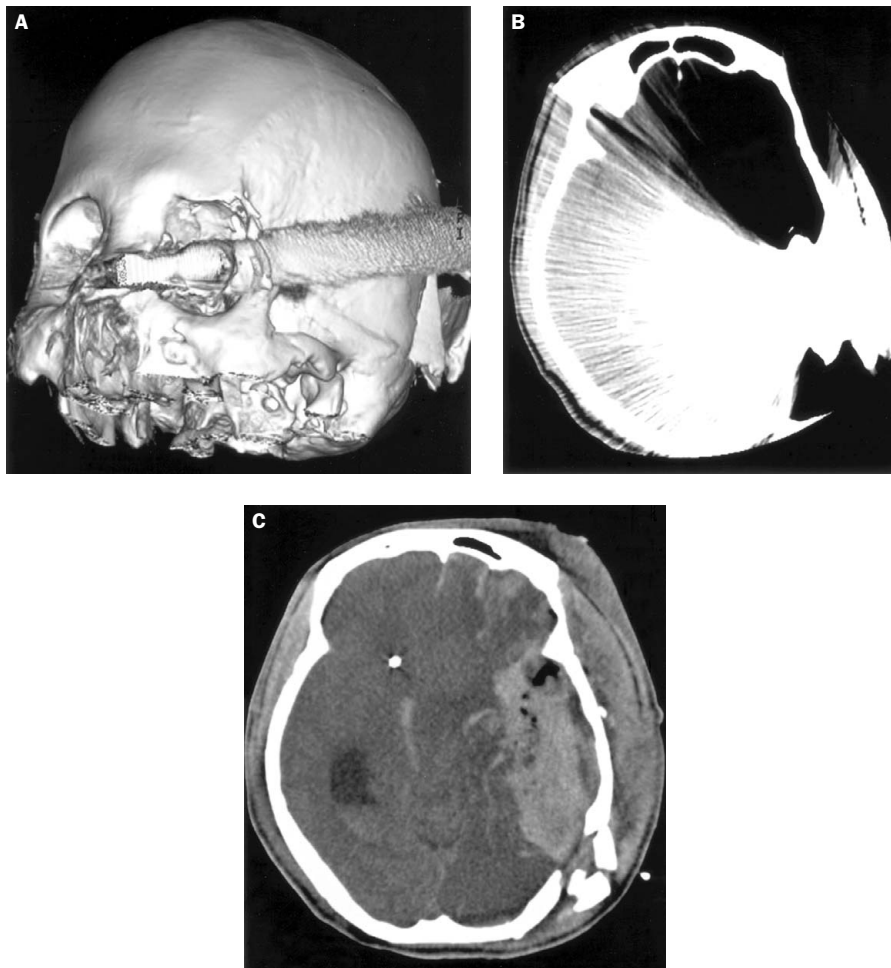

Figure 2. Case 2: (A) 3-dimensional reconstruction computed tomography (CT) shows that the metal bar has gone through the medial canthus of the left orbit and caused ipsilateral occipital bone fracture. (B) CT reveals marked artifacts along the trajectory of penetration and the basal cisterns could not be assessed. (C) Postoperatively, CT reveals large residual (or delayed) hematoma with severe brain shift.

hemorrhage was noted intraoperatively. However, 1 day postoperatively, follow-up brain CT revealed a massive residual or delayed hematoma along the penetrating path and severe brain shift without elevation of intracranial pressure. Surgical intervention was again undertaken, but severe generalized brain swelling developed and the patient died 2 weeks later due to central failure with intractable increased intracranial pressure.

Discussion

The orbit is a bony pyramid shaped structure with thin walls that are vulnerable to injury. Foreign bodies typically penetrate the orbit from the medial canthus and usually pass through the optic canal and superior orbital fissure to lodge in the ipsilateral or contralateral side of the cranium.⁵ The most frequent path of penetration is via the roof of the orbit due to the fragile structure of the superior orbital plate of the frontal bone, often resulting in frontal lobe contusion, as found in case 1. The second most frequent path of penetration is the superior orbital fissure, by which foreign bodies occasionally reach the brain stem through the cavernous sinus and cause serious damage, as observed in case 2.⁶ Brain damage in these cases can include cerebrospinal fluid fistulas, pneumocephalus, orbital cellulites, carotid-cavernous sinus fistula, central nervous system (CNS) infections, and intracranial hemorrhage.

The most appropriate management in the field is to leave the transorbital object *in situ* and transport the patient to the trauma center carefully. Management of patients with transorbital brain injuries and foreign bodies *in situ* should follow basic surgical principles, including removal of the object under direct vision in order to reduce further brain tissue damage by the foreign bodies catching on bone fragments.² Following removal of the foreign body, thorough debridement with removal of all involved skull bone and foreign materials, hematoma evacuation followed by careful hemostasis along the trajectory, and meticulous dural closure to reduce the possibility of cerebrospinal fluid fistula are mandatory.¹ For patients with deep-seated bullet in the brain, it is not necessary to remove the bullet because of the potential for further brain damage and because of the low incidence of CNS infection. However, metal bars and other missiles with extracranial components must be removed, and prophylactic antibiotics should be considered.⁷

CT is typically the first-line radiologic examination in the emergency room for head-injured patients. However, scanning artifacts from metal objects can sometimes limit visualization of brain tissue and brain

damage along the trajectory of the penetrating object. In patients with transorbital brain injuries, the path of penetration often passes near the cavernous sinus and basal cisterns. Thus, corresponding brain contusion hemorrhages with great mass effect may be obscured in the initial CT scan. Notably, in case 2, a large hematoma with no change in intracranial pressure was detected on postoperative CT (Figure 2C). We therefore recommend an immediate follow-up CT scan postoperatively in order to look for missed contusion brain damage and possible hemorrhage. An alternative approach is endoscopic brain surgery via the transorbital route, which may offer direct visualization of unidentified brain damage along the penetrating path and provide direct hemostasis.

Finally, angiography is advocated by some authors for possible cerebral vascular injuries in patients following penetrating head injuries.¹ In 1 study, Kieck and Villiers³ reported 11 vascular lesions identified with cerebral angiography in 18 transorbital head-injured patients (61%). However, due to prolonged radiologic intervention procedures and inadequate CT scan resolution, patients with extended transorbital brain injuries may deteriorate rapidly, as in the 2 cases presented in this report. We propose that prompt craniotomy for decompression and direct hemostasis for vascular injuries is a better option than cerebral angiography in patients with extended transorbital brain injuries.

In conclusion, transorbital brain injury caused by a metal bar is a rare but fatal event. Emergent surgical intervention and early follow-up CT is necessary if there is to be any chance of saving the life of the patient.

References

1. O'Neill OR, Gilliland G, Delashaw JB, Purtzer TJ. Transorbital penetrating head injury with a hunting arrow: case report. *Surg Neurol* 1994;42:494-7.
2. Seex K, Koppel D, Fitzpatrick M, Pyott A. Transorbital penetrating head injury with a door key. *J Craniomaxillofac Surg* 1997;25:353-5.
3. Kieck CF, Villiers JC. Vascular lesions due to transcranial stab wounds. *J Neurosurg* 1984;60:42-6.
4. Jennett B, Bond MR. Assessment of outcome after severe brain damage. *Lancet* 1975;1:480-4.
5. Davis GA, Holmes AD, Kulg GL. Delayed presentation of transorbital intracranial pen. *J Clin Neurosci* 2000;7:542-60.
6. Matsumoto S, Hasuo K, Mizushima A, Mihara F, Fukui M, Shirouzu T, Masuda K. Intracranial penetrating injuries via the optic canal. *Am J Neuroradiol* 1998;19:1163-5.
7. Harsh GR. Penetrating wounds of the head. In: Wilkins RH, Rengachary SS, eds. *Neurosurgery*. New York: McGraw-Hill, 1985:1670-8.