

# Treatment of Massive Retroperitoneal Hemorrhage from Adrenal Metastasis of Hepatoma

Por-Wen Yang<sup>1</sup>, Wen-Yen Wang<sup>2\*</sup>, Chin-Hua Yang<sup>3</sup>, Chia-Cheng Chou<sup>4</sup>,  
David Hung-Tsang Yen<sup>5,6</sup>, Jason Chou<sup>7</sup>

*Departments of*<sup>1</sup>*Internal Medicine,* <sup>3</sup>*Radiology,* <sup>4</sup>*Surgery and* <sup>7</sup>*Pathology, Taoyuan General Hospital, Taoyuan,* <sup>2</sup>*Department of Surgery, Hsinchu General Hospital, Hsinchu,* <sup>5</sup>*Department of Emergency Medicine, Taipei Veterans General Hospital, and* <sup>6</sup>*National Yang-Ming University School of Medicine, Taipei, Taiwan, R.O.C.*

Spontaneous rupture of metastatic adrenal tumor with massive retroperitoneal hemorrhage and shock is an uncommon clinical event. Herein, we report a case of hepatocellular carcinoma (HCC), where left hepatic lobectomy and right adrenalectomy for metastatic HCC were performed in April and August 2002, respectively. Subsequently, the patient presented to the emergency room with acute-onset severe left flank and back pain in March 2004, accompanied by a falling hemoglobin level. Computed tomography revealed a 7-cm left adrenal tumor mass with retroperitoneal hemorrhage. The ruptured adrenal tumor was further confirmed by selective angiography, which demonstrated that the bleeder was supplied by the left suprarenal artery. Transarterial embolization (TAE) to stop tumor bleeding was performed successfully. The patient then underwent tumor resection with left adrenalectomy 5 days after the embolization, with pathology subsequently revealing metastatic HCC. The recurrent intrahepatic HCC was controlled with TAE, and the patient underwent hormone replacement therapy with prednisolone 10 mg/day. Metastatic adrenal tumor bleeding should be suspected in hepatoma patients who suffer abrupt flank pain and shock. Hemodynamically unstable patients require supportive transfusions and urgent surgical exploration. Angiographic embolization, if deemed feasible, may be a valuable adjunct for achievement of hemostasis prior to definite surgery. [*J Chin Med Assoc* 2007;70(3):126–131]

**Key Words:** adrenal tumor, embolization, hepatocellular carcinoma, metastasis

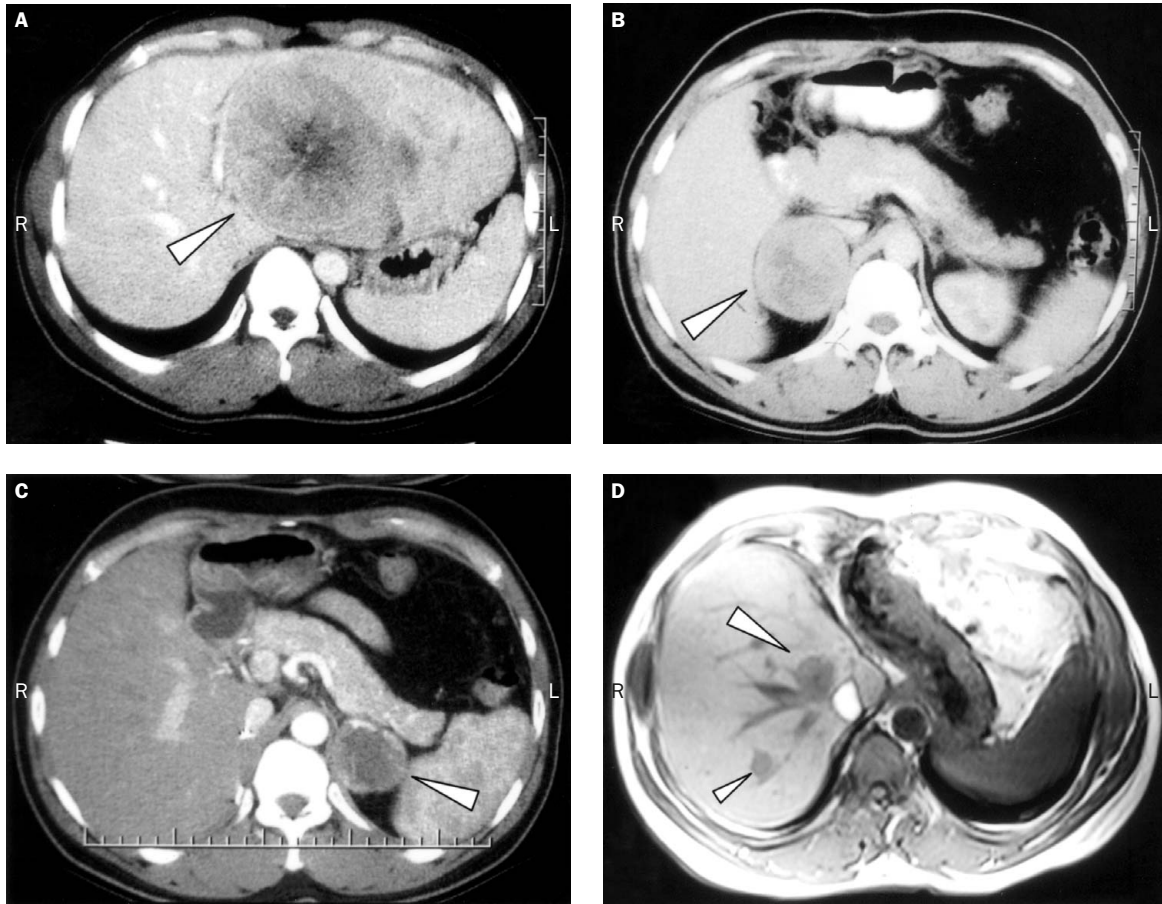
## Introduction

Metastasis to the adrenal gland is a common complication of malignancy, with a reported incidence of 13–27%.<sup>1,2</sup> These lesions are rarely clinically significant, however, and massive adrenal hemorrhage into the retroperitoneum with shock secondary to metastasis is rare.<sup>3</sup> We report a case of hepatocellular carcinoma (HCC) with metastatic adrenal tumor bleeding. Transarterial embolization (TAE) to stop tumor bleeding was successful. Tumor resection with left adrenalectomy was performed after the embolization. The clinical manifestations, diagnostic modalities, treatment and prognosis for adrenal tumor bleeding are also reviewed.

## Case Report

A 37-year-old man presented to our emergency room in March 2004 because of acute-onset dull pain in the left flank radiating into the left upper abdomen. The patient had not recently sustained any trauma. Past history included chronic hepatitis B-related liver cirrhosis. In March 2002, he had visited our hospital because of right-side abdominal pain. Computed tomography (CT) scan at that time revealed a huge mass in the left hepatic lobe (Figure 1A), with a high level of  $\alpha$ -fetoprotein (AFP; 61.83 ng/dL; reference range, 0.00–10.00) detected. From these findings, HCC in the left hepatic lobe was strongly suspected, and a left hepatic lobectomy was performed in April 2002.

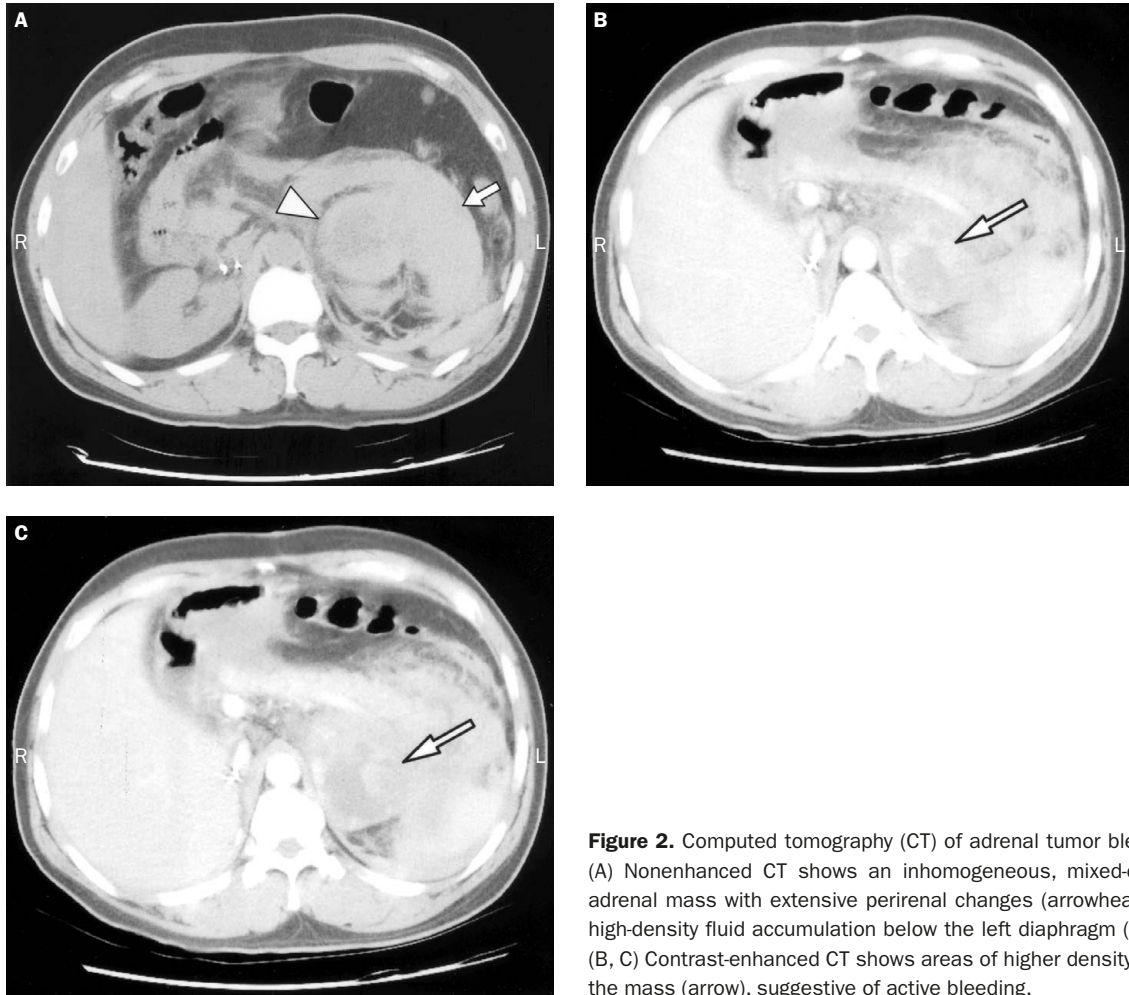
\*Correspondence to: Dr Wen-Yen Wang, Department of Surgery, Hsinchu General Hospital, Department of Health, The Executive Yuan, No. 25, Lane 442, Section 1, Jingguo Road, Hsinchu City 300, Taiwan, R.O.C.  
E-mail: hywwy@hch.gov.tw • Received: July 4, 2006 • Accepted: January 3, 2007



**Figure 1.** (A) Tumor shadow with low density is visible (arrowhead) during computed tomography (CT), delayed phase, of the primary hepatic lesion. (B) CT before the 2<sup>nd</sup> operation shows right adrenal tumor (arrowhead). (C) CT before the 3<sup>rd</sup> operation shows left adrenal tumor (arrowhead). (D) Magnetic resonance imaging before the 3<sup>rd</sup> operation shows intrahepatic nodules (arrowheads).

Histopathologic examination confirmed HCC. Two months after the operation, the AFP level had decreased to within the normal range (7.63 ng/dL). At the 4-month follow-up, however, the AFP level had increased to 10.21 ng/dL. Diagnostic CT revealed a solitary well-enhanced nodular mass with central necrosis in the right adrenal gland, about 6 cm in diameter, strongly suggestive of metastasis (Figure 1B). There was no evidence of recent hemorrhage inside the right adrenal tumor. An endocrine survey revealed cortisol level of 18.3  $\mu\text{g}/\text{mL}$  (normal range, 4.0–12.0  $\mu\text{g}/\text{mL}$ ), adrenocorticotrophic hormone of 22.6 pg/mL (normal range, 0.0–46.0 pg/mL) and 24-hour urine vanillylmandelic acid of 1.1 mg/day (normal range, 1.5–7.5 mg/day). As there was no evidence of other extrahepatic metastasis or intrahepatic recurrence, the right adrenal tumor was resected 4 months after the 1<sup>st</sup> operation. Pathologic examination revealed adrenal metastasis of HCC. AFP (3.59 ng/dL) decreased to within normal range 2 months after this operation. One year and 5 months after the 2<sup>nd</sup> operation, however, AFP increased to

12.14 ng/dL again. CT and magnetic resonance imaging (MRI) revealed a well-enhanced and well-demarcated tumor (5  $\times$  3  $\times$  4 cm) with central necrosis in the left adrenal gland and several intrahepatic nodules, suggesting recurrence (Figure 1 C,D). There was no evidence of recent hemorrhage inside the left adrenal tumor. Although there was no further intervention, the patient was followed up at the outpatient department until March 2004, when the acute left flank pain occurred. He appeared to be in moderate distress from left flank pain, with pulse rate 71 beats/minute, blood pressure 109/63 mmHg, temperature 35.9°C, and respiration 18 breaths/minute. Inspection of the abdomen revealed 1 surgical scar in the shape of an inverse Y over the upper abdomen and another linear surgical scar over the right flank. The patient had moderate abdominal tenderness with guarding over the left flank and left upper abdomen. Rebound pain was also noted. There was no palpable mass. The remainder of the physical examination was unremarkable. White cell count was 10,120/ $\text{mm}^3$ , and urinalysis was normal.



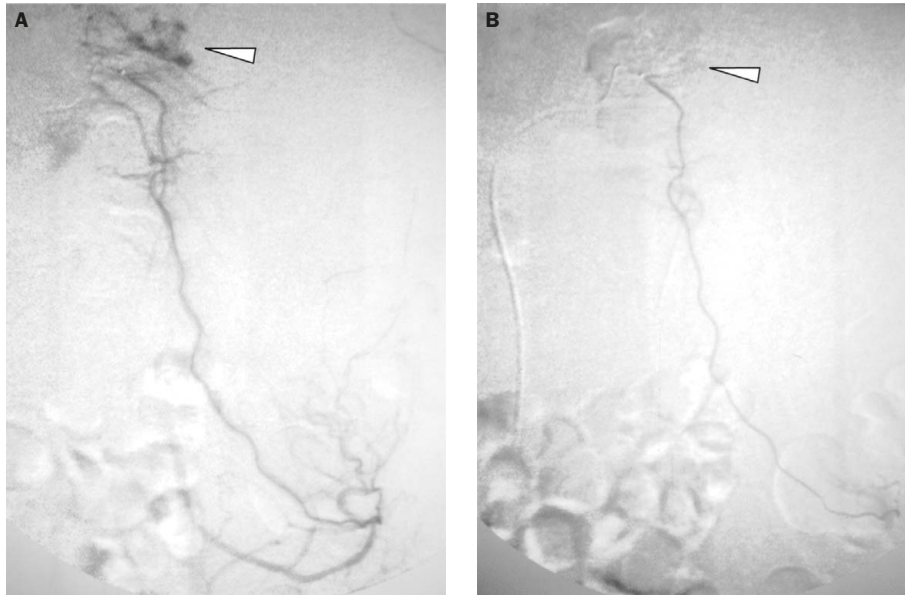
**Figure 2.** Computed tomography (CT) of adrenal tumor bleeding. (A) Nonenhanced CT shows an inhomogeneous, mixed-density adrenal mass with extensive perirenal changes (arrowhead) and high-density fluid accumulation below the left diaphragm (arrow). (B, C) Contrast-enhanced CT shows areas of higher density within the mass (arrow), suggestive of active bleeding.

Hemoglobin was 14.1 g/dL, but this fell to 8.9 g/dL within the first 24 hours. CT showed enlargement of the left adrenal gland with ill-defined contour and surrounding hematoma formation in the left perirenal fascia and splenic hilum up to the left subdiaphragmatic space. Contrast-enhanced CT also showed areas of higher density within the mass, suggestive of active bleeding (Figure 2). Transfemoral abdominal angiography was used to identify the bleeding site (Figure 3A). Coil embolization in the bleeding vessels, specifically branches of the left suprarenal artery, was performed (Figure 3B), with active bleeding successfully controlled. Another operation was performed 5 days after the embolization for evacuation of the hematoma and excision of the adrenal gland, which showed tumorous changes. Immediately after the surgery, cortisol supplementation was initiated according to the following daily regimen: operation to postoperative day 2, 100 mg hydrocortisone (intravenous); postoperative days 3–7, 15 mg prednisolone tablet daily; after postoperative day 7, 10 mg prednisone tablet daily. Histopathologic

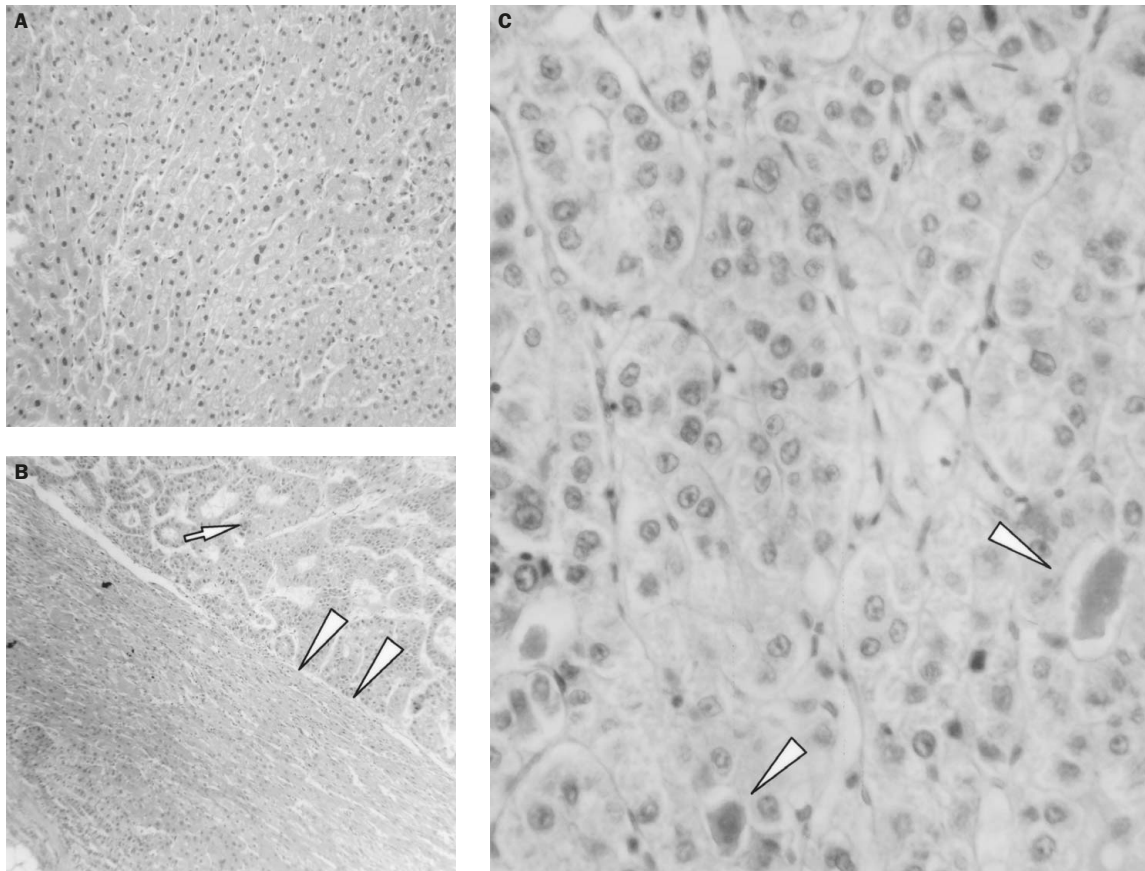
examination revealed metastatic cancer cells in the left adrenal tumor similar to HCC. When the histologic findings for specimens from the primary HCC and the metastatic left and right adrenal tumors were compared, there was no definite differentiation of tumor cells (Figure 4). The postoperative course was uneventful, with the patient discharged on postoperative day 28, and steroid hormone replacement with prednisolone 10 mg/day prescribed. TAE for recurrent HCC was arranged after the 3<sup>rd</sup> operation, and the patient was still alive at follow-up 18 months after the 3<sup>rd</sup> operation (Figure 5).

## Discussion

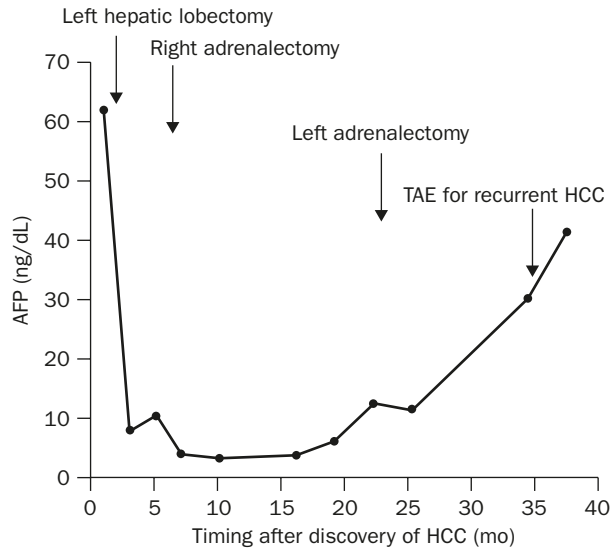
Usually discovered incidentally in autopsy studies, metastatic lesions to the adrenal glands are rarely clinically significant, however, up to 27% of deceased cancer patients are found to harbor adrenal metastases.<sup>2</sup> With the continuing development of imaging



**Figure 3.** Angiographic embolization. (A) Bleeding site was found by angiography (arrowhead). (B) Coil embolization was performed in the bleeding vessels, specifically branches of the left suprarenal artery, successfully stopping the bleeding (arrowhead).



**Figure 4.** Comparison of microscopic findings in specimens obtained during the 1<sup>st</sup> and 3<sup>rd</sup> operations. (A) First operation: primary hepatic lesion (hematoxylin & eosin [H&E], 100 $\times$ ). (B) Third operation: metastatic tumor (arrow) within the left adrenal capsule (arrowheads) (H&E, 40 $\times$ ). (C) Close-up of bile in the bile canaliculi (arrowheads) (H&E, 400 $\times$ ).



**Figure 5.** Timing of resection of hepatocellular carcinoma (HCC)/adrenalectomy/transarterial embolization (TAE) and serial changes in serum  $\alpha$ -fetoprotein (AFP) levels.

techniques, an increasing number of adrenal metastases are being detected incidentally during follow-up or at the time of initial presentation.<sup>4</sup> In this case, the AFP value was useful for detecting adrenal metastasis. Sequential follow-up evaluation of tumor markers and diagnostic imaging is essential for the early detection of metastatic lesions.

Adrenal metastasis rarely produces symptoms.<sup>5</sup> However, our patient presented with acute-onset severe left flank and back pain, accompanied by a fall in the hemoglobin level, due to adrenal hemorrhage. The major clinical manifestations of adrenal hemorrhage depend on whether 1 or both adrenal glands are involved, if their function is partially or completely destroyed, and the extent of the protrusion/containment of the hemorrhage within the adrenal glands. Signs and symptoms may include severe pain in the upper abdomen of abrupt onset, usually radiating to the flank, occasionally with diaphragmatic irritation. There may be signs of peritoneal irritation, especially when blood enters the peritoneal cavity. Shock and decreasing hemoglobin concentration may occur, but not invariably.<sup>6</sup>

We selected CT as the first choice of diagnostic modality because of its unique ability to identify tissue densities characteristic of blood, fat and so forth.<sup>7</sup> Typically, CT findings show an inhomogeneous, mixed-density adrenal mass with extensive perirenal changes.<sup>6</sup> Acute bleeding is often identified as areas of higher density within the mass on contrast-enhanced CT.<sup>8</sup>

Report of bilateral adrenalectomy for HCC metastases is rare. It is of interest to discuss the therapeutic

strategy for such cases, however. Metastasis of HCC to the adrenal gland, which is the 2<sup>nd</sup> most common site of hematogenous spread after the lung, has been reported in 8.4% of cases on autopsy.<sup>9</sup> With improved imaging modalities, metastatic adrenal tumors can be identified at an early stage before spread to any other part of the body. The discovery of adrenal metastasis in patients with primary tumor automatically transfers them to an advanced stage.<sup>3</sup> Recent advances in the diagnostic and therapeutic modalities used for many tumors have resulted in increased life expectancies in some cancer patients,<sup>3,10,11</sup> and increased the clinical significance of distant metastases. Therefore, it is possible to improve the prognosis of adrenal metastasis from HCC through multidisciplinary treatment. Therapeutic modalities should be chosen according to each individual's clinical features, including the size of the metastatic tumor, whether there is invasion into the inferior vena cava, function of the remaining liver, and the existence of intrahepatic and/or nonadrenal extrahepatic lesions.<sup>12,13</sup>

Several treatment modalities are available for adrenal metastasis from HCC, such as adrenalectomy, TAE, percutaneous ethanol injection therapy (PEIT) and radiation therapy. With respect to TAE, the adrenal gland has 3 feeder arteries (inferior phrenic artery, abdominal aorta, renal artery), making it difficult to perform complete TAE for adrenal tumors.<sup>12</sup> The US-guided PEIT technique not only involves technical difficulties with respect to puncture of a small nodule situated deep in the back behind the cirrhotic liver, but also carries a risk of tumor seeding via the needle tract or bleeding from the punctured tumor.<sup>12</sup> The effect of radiation therapy on adrenal metastasis was uncertain in the past,<sup>13</sup> however, some progress has been achieved recently with respect to advancement of this therapeutic modality. Adrenal metastases from HCC are sensitive to radiation treatment. Radiation therapy (50 Gy) for adrenal gland metastases is good palliative therapy for pain relief, providing reasonable safety.<sup>14</sup> Surgical resection is indicated when the extrahepatic recurrence is solitary and intrahepatic recurrence is not found; at this stage, it is also the only way to achieve long-term disease-free survival.<sup>12,13</sup> Since patients with an adrenal mass are at risk for hemorrhage into the adrenal gland in the event of tumor growth, the prevention of massive adrenal hemorrhage may prolong their survival and enhance quality of life.<sup>15</sup> Based on the encouraging 18-month survival achieved in our patient after treatment for metastatic adrenal tumor hemorrhage, it appears reasonable to suggest aggressive surgical treatment for HCC and its adrenal metastasis if intrahepatic recurrence and/or other extrahepatic metastases are

controlled. If other lesions are not so well controlled, however, interventional therapies such as TAE, PEIT and radiation therapy would be the treatment of choice for adrenal metastasis from HCC.<sup>13,16</sup>

When the left-side adrenal tumor bleeding was detected in our case, supportive transfusions and TAE were selected as the first choice of treatment because: (1) clinically significant adrenal hemorrhage secondary to metastasis is rare, and most of the reported patients were stabilized hemodynamically after transfusions and required no further surgical intervention;<sup>3</sup> (2) massive bleeding from an adrenal metastasis requires surgical laparotomy for hemostasis,<sup>3</sup> however, acute surgical removal of an adrenal tumor within a large retroperitoneal hematoma should be avoided as proper oncologic resection may not be possible under such conditions;<sup>17</sup> and (3) in patients with active bleeding, angiographic embolization is a valuable adjunct for achievement of hemostasis, allowing further workup of the adrenal tumor and improvement in the effectiveness of subsequent oncologic resection.<sup>17-20</sup> In this case, the clinical course of massive tumor bleeding from adrenal metastasis shows the efficacy of embolization with respect to achievement of hemostasis prior to subsequent tumor resection, however, the clinical significance of this strategy can be evaluated only after further long-term follow-up of a relatively large number of patients.

Metastatic adrenal tumor bleeding should be suspected in HCC patients who suffer abrupt flank pain and shock. CT scan is suggested as initial screening for probable bleeding focus. Hemodynamically unstable patients require supportive transfusions and urgent surgical exploration. Angiographic embolization, if deemed feasible, may be a valuable adjunct for achievement of hemostasis prior to definite surgery.

## References

1. Glomset DA. Incidence of metastasis of malignant tumors to the adrenals. *Am J Cancer* 1938;32:57-61.
2. Abrams HL, Spiro R, Goldstein N. Metastases in carcinoma: analysis of 1000 autopsied cases. *Cancer* 1950;3:74-85.
3. Lam KY, Lo CT. Metastatic tumours of the adrenal glands: a 30-year experience in a teaching hospital. *Clin Endocrinol* 2002; 56:95-101.
4. Berte SJ. Spontaneous adrenal hemorrhage in the adult: literature review and report of two cases. *Ann Intern Med* 1953; 38:28-37.
5. Siekavizza JL, Bernardino ME, Samaan NA. Suprarenal mass and its differential diagnosis. *Urology* 1981;18:625-32.
6. Shah HR, Love L, Williamson MR, Buckner BC, Ferris EJ. Hemorrhagic adrenal metastases: CT findings. *J Comput Assist Tomogr* 1989;13:77-81.
7. Swift DL, Lingman JE, Baum WC. Spontaneous retroperitoneal hemorrhage: a diagnostic challenge. *J Urol* 1980;123: 577-81.
8. Liu L, Haskin ME, Rove LI, Bemis CE. Diagnosis of bilateral adrenocortical hemorrhage by computed tomography. *Ann Intern Med* 1982;97:720-1.
9. Nakashima T, Okuda K, Kojiro M, Jimi A, Yamaguchi R, Sakamoto K, Ikari T. Pathology of hepatocellular carcinoma in Japan. *Cancer* 1982;51:863-77.
10. Lin CP, Yu HC, Cheng JS, Lai KH, Lo GH, Hsu PI, Lin CK, et al. Clinical effects of intra-arterial infusion chemotherapy with cisplatin, mitomycin C, leucovorin and 5-fluorouracil for unresectable advanced hepatocellular carcinoma. *J Chin Med Assoc* 2004;67:602-10.
11. Huo TI, Huang YH, Wu JC. Percutaneous ablation therapy for hepatocellular carcinoma: current practice and future perspectives. *J Chin Med Assoc* 2005;68:155-9.
12. Sakamoto Y, Kubuto K, Mori M, Inoue K, Abe H, Harihara Y, Bandai Y, et al. Surgical management for adrenal gland metastasis of hepatocellular carcinoma. *Hepatogastroenterol* 1999; 46:1036-41.
13. Momoi H, Shimahara Y, Terajima H, Iimuro Y, Yamamoto N, Yamamoto Y, Ikai I, et al. Management of adrenal metastasis from hepatocellular carcinoma. *Surg Today* 2002;32:1035-41.
14. Zeng ZC, Tang ZY, Fan J, Zhou J, Qin LX, Ye SL, Sun HC, et al. Radiation therapy for adrenal tumor gland metastases from hepatocellular carcinoma. *Jpn J Clin Oncol* 2005;35:61-7.
15. Seidenwurm DJ, Elmer EB, Kaplan LM, Williams EK, Morris DG, Hoffman AR. Metastases to adrenal glands and the development of Addison's disease. *Cancer* 1984;54:552-7.
16. Morimoto T, Honda G, Oh Y, Ozaki N, Iimuro Y, Yamamoto Y, Sakai Y, et al. Management of adrenal metastasis of hepatocellular carcinoma by synchronous resection of bilateral adrenal glands. *J Gastroenterol* 1999;34:132-7.
17. Hendrickson RJ, Katzman PJ, Queiroz R, Sitzmann JV, Koniaris LG. Management of massive retroperitoneal hemorrhage from an adrenal tumor. *Endocr J* 2001;48:691-6.
18. Chng SM, Lin MB, Ng FC, Chng HC, Khoo TK. Adrenal myelolipoma presenting with spontaneous retroperitoneal haemorrhage demonstrated on computed tomography and angiogram: a case report. *Ann Acad Med Singapore* 2002;31: 228-30.
19. Park JH, Kang KP, Lee SJ, Kim CH, Park TS, Baek HS. A case of a ruptured pheochromocytoma with an intratumoral aneurysm managed by coil embolization. *Endocr J* 2003;50: 653-6.
20. Nakajo M, Onohara S, Shinmura K, Fujiyoshi F, Nakajo M. Embolization for spontaneous retroperitoneal hemorrhage from adrenal myelolipoma. *Radiat Med* 2003;21:214-9.