

# Rifabutin-induced Hypopyon Uveitis in Patients with Acquired Immunodeficiency Syndrome Infected with *Mycobacterium avium* Complex

Hsin-Hui Wang<sup>1</sup>, Yu-Mei Chung<sup>2\*</sup>, Ying-Cheng Lin<sup>1</sup>, Hsing-Chuan Hu<sup>1</sup>, Wing-Wai Wong<sup>3</sup>

<sup>1</sup>Department of Ophthalmology, Taipei Veterans General Hospital, <sup>2</sup>Uveitis Service, Department of Ophthalmology, National Yang-Ming University and Taipei Veterans General Hospital, and <sup>3</sup>Division of Infectious Diseases, Department of Internal Medicine, Taipei Veterans General Hospital and National Yang-Ming University, Taipei, Taiwan, R.O.C.

Rifabutin is a semi-synthetic antimycobacterial agent mainly used in the prophylaxis and treatment of *Mycobacterium avium* complex (MAC) in acquired immunodeficiency syndrome patients. Uveitis as a side effect of rifabutin has been recognized and established since 1994, but there was no case previously described in Taiwan so far. We report 2 cases of rifabutin-induced hypopyon uveitis in patients with human immunodeficiency virus and MAC infection. Both patients received the regimen of clarithromycin and rifabutin to treat MAC infection. Uveitis resolved after discontinuing of rifabutin and treatment with topical corticosteroid and mydriatics. Early recognition of this entity can prevent invasive ocular procedures and treatments. Doctors who prescribe rifabutin should be aware of this ocular complication of uveitis and drug–drug interactions. Ophthalmologists should put this on the list of differential diagnoses for uveitis. [*J Chin Med Assoc* 2007;70(3):136–139]

**Key Words:** HIV, hypopyon, *Mycobacterium avium* complex, rifabutin, uveitis

## Introduction

*Mycobacterium avium* complex (MAC) infection is a common opportunistic infection in patients with acquired immunodeficiency syndrome (AIDS). Since the number of AIDS patients are increasing in Taiwan, we should pay more attention to AIDS-related disorders. The US Public Health Service has recommended rifabutin as prophylaxis for MAC infection in patients with advanced AIDS at a dosage of 300 mg/day.<sup>1</sup> It is also frequently used in combination therapy for treatment of MAC infection. Usually, rifabutin is well tolerated,<sup>2</sup> although several cases of rifabutin-induced uveitis in human immunodeficiency virus (HIV)-infected patients have been reported since 1994.<sup>3–6</sup> But there has been no case described in Taiwan so far. We report 2 cases of rifabutin-induced hypopyon uveitis in patients with HIV and MAC infection, and review the clinical manifestations of this disease.

## Case Reports

### Case 1

A 26-year-old man was referred to our uveitis clinic on August 26, 2003. Anterior uveitis of his left eye was diagnosed 9 days previously at a local clinic, and the symptoms were relieved gradually after treatment. However, blurred vision and photophobia developed in his right eye thereafter.

On tracing the patient's history, it was found that he was a case of AIDS under highly active antiretroviral combination therapy (HAART) with combivir (lamivudine 150 mg and zidovudine 300 mg, twice daily) and nelfinavir (1,250 mg twice daily). He was also on sulfamethoxazole–trimethoprim, clindamycin and fluconazole for other opportunistic infections. In addition, he had received treatment for MAC infection with a regimen of clarithromycin (500 mg/day), ethambutol (800 mg/day) and rifabutin (300 mg/

\*Correspondence to: Dr Yu-Mei Chung, Department of Ophthalmology, Taipei Veterans General Hospital, 201, Section 2, Shih-Pai Road, Taipei 112, Taiwan, R.O.C.  
E-mail: ym\_chang@vghtpe.gov.tw • Received: May 18, 2006 • Accepted: January 22, 2007

day) since June 2003. Ocular history was entirely normal.

On ophthalmic examination, best corrected visual acuity (BCVA) was 6/10 oculus dexter (OD) and 6/6.7 oculus sinister (OS). Slit lamp examination showed 1 mm hypopyon with 4+ aqueous cells in the right eye (Figure 1) and 2+ aqueous cells in the left eye. Fundus examination showed blurred view in both eyes.

Rifabutin therapy was stopped immediately and topical steroid with 1% prednisolone acetate 4 times a day and 2% homotropine eyedrops twice a day to both eyes were started. Hypopyon uveitis completely resolved after 2 weeks. One month later, visual acuity had improved to 6/6 in both eyes. No recurrence of uveitis was noted during 2 years of follow-up.

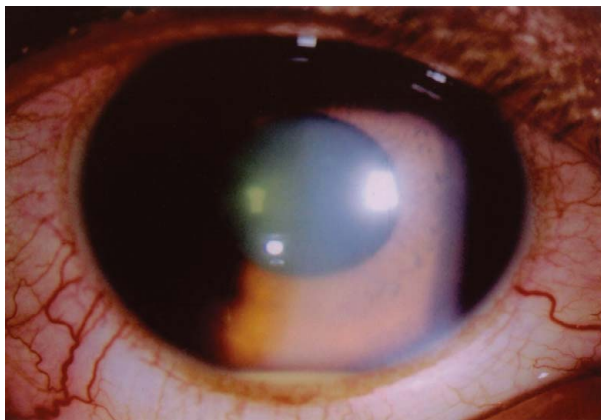
### Case 2

A 33-year-old man visited our clinic with the complaints of sudden blurred vision and severe pain in his left eye for 1 day on August 24, 2004.

From his past history, the patient was found to have HIV infection under treatment with HAART with kaletra (lopinavir 200 mg and ritonavir 50 mg, 3 tablets

q12h), lamivudine (150 mg, twice daily) and stavudine (40 mg, twice daily). Also, he had cytomegalovirus (CMV) retinitis in both eyes (Figure 2) under maintenance ganciclovir therapy, in addition to clarithromycin, levofloxacin, pyrazinamide (PZA), rifabutin (300 mg/day) and sulfamethoxazole–trimethoprim for MAC infection and simultaneous *Pneumocystis carinii* pneumonia.

At the time of presentation, BCVA was 6/12 OD and 6/60 OS. Slit lamp examination showed silent anterior chamber in the right eye and hypopyon with 3+ aqueous cells and flare in the left eye. Fundoscopic examination revealed inactive CMV retinitis in the right eye and obscuration in the left eye. Prednisolone acetate 1% every 2 hours and atropine 1% 3 times a day to the left eye were prescribed. Four days later, similar symptoms in the right eye were reported. Hypopyon was noted in the right eye (Figure 3). Topical steroid and mydriatic were applied to both eyes, and rifabutin therapy was stopped. Two months later, BCVA returned to 6/12 OD and 6/8.6 OS with silent anterior chamber. No recurrence of uveitis was noted during a 1-year follow-up period.

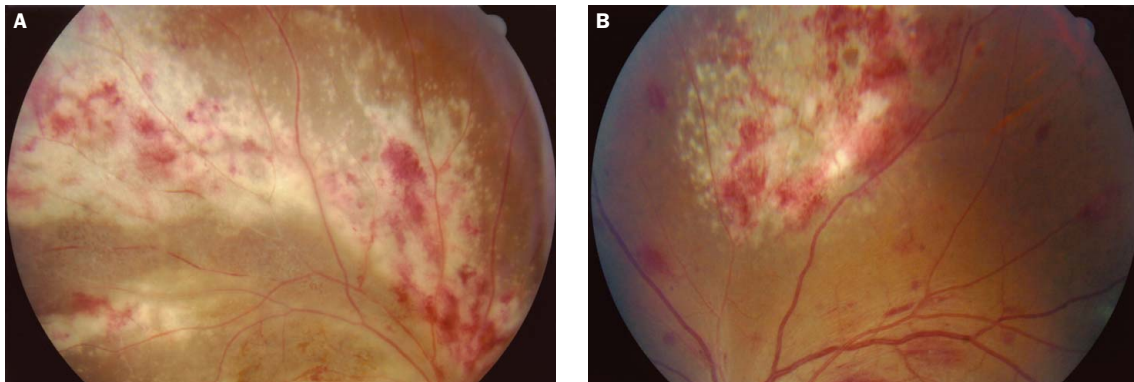


**Figure 1.** Case 1: slit lamp examination of the right eye shows 1 mm hypopyon with 4+ aqueous cells in the anterior chamber.

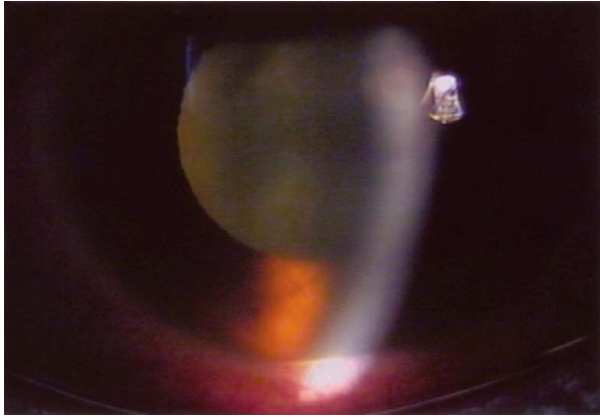
### Discussion

Causes of uveitis in patients infected with HIV are frequently associated with opportunistic infections, such as herpes zoster ophthalmicus, tuberculosis, CMV retinitis, toxoplasmosis and possibly secondary to HIV itself.<sup>7</sup> Usually, it presents as a posterior segment disease. Hypopyon iritis is not a characteristic of any of these opportunistic infectious uveitis syndromes.

Rifabutin is a semi-synthetic spiro-piperidyl-rifamycin S derivative of rifamycin. It was approved by the FDA in December 1992 for use in HIV-infected patients with CD4<sup>+</sup> cell counts less than 100/mm<sup>3</sup> for MAC prophylaxis. It is also a part of the multidrug



**Figure 2.** Case 2: fundus photographs of both eyes reveal cytomegalovirus retinitis. (A) Right eye; (B) left eye.



**Figure 3.** Case 2: slit lamp examination of the right eye shows hypopyon with 3+ aqueous cells in the anterior chamber.

regimen for treatment of disseminated MAC infections. However, uveitis as a side effect of rifabutin therapy has been recognized since 1994.<sup>3-6</sup> Initially, the majority of these cases were diagnosed as endophthalmitis and received invasive work-up.

Shafran et al<sup>3</sup> conducted a prospective randomized study of treatment for disseminated MAC infection. Fifty-nine patients were on a regimen of rifabutin (600 mg daily), clarithromycin (1,000 mg twice daily) and ethambutol 15 mg/kg of body weight daily. Uveitis developed in 23 of these 59 patients and it was treated with topical corticosteroids and mydriatics, with favorable outcomes in all patients. Therefore, the MAC Study Group of the Canadian HIV Trial Network recommended a reduction in the dose of rifabutin to 300 mg daily and the discontinuation of rifabutin therapy in patients with uveitis.

The pathogenetic mechanisms of rifabutin-induced uveitis in MAC-infected patients have not yet been elucidated. Possible pathogenic mechanisms may be an immune reaction or direct drug toxicity. Saran et al assumed that the rifabutin-associated uveitis might be analogous to the Jarisch–Herxheimer reaction when penicillin is used in the treatment of systemic syphilis.<sup>5</sup> An inflammatory response to dead MAC organisms or their released toxins is plausible. Direct rifabutin toxicity was advocated by Shafran et al,<sup>8</sup> as evidenced by dose-dependency, cumulative time-dependency, involvement of both eyes in most cases when there was rifabutin maintenance, and reversibility on drug discontinuation.

In this report, both patients presented with unilateral progressing to bilateral anterior uveitis after rifabutin therapy for about 2 months. The presentation and response to medication were similar to those that have been previously reported. Both of them were receiving rifabutin 300 mg daily and clarithromycin therapy for pulmonary MAC infection in addition to

HAART. They were being treated with currently recommended multidrug regimens in recommended doses, but still developed severe uveitis. The main cause was drug–drug interactions.

Most authors have commented on the increased risk of rifabutin-induced uveitis in cases of concomitant treatment with clarithromycin.<sup>4,5,9</sup> Clarithromycin is a member of the macrolide group of antibiotics, which inhibits cytochrome P450 (CYP450). Clarithromycin inhibited rifabutin's metabolism and doubled the blood level.<sup>10</sup> Simultaneous fluconazole or protease inhibitor treatment also increased the risk by a similar mechanism.<sup>4-6,11</sup> Of the available protease inhibitors, ritonavir has the highest potency in inhibiting CYP450.<sup>11</sup> Thus, reduced rifabutin dosage of 150 mg daily or 150 mg 2–3 times per week is recommended if there is any co-administration of rifabutin with the protease inhibitors used in our cases ritonavir and nelfenavir.<sup>12</sup>

In case 2, immune recovery uveitis may be suspected due to the CMV retinitis history in this era of HAART. However, immune recovery uveitis is characterized by significant vitritis, cystoid macular edema, epiretinal membranes and disc edema, rather than hypopyon as occurred in our cases. Besides, in a prospective clinical trial of 14 patients with stable CMV retinitis and HIV infection during HAART, 12 (89.7%) of the 14 patients had immune recovery uveitis. The median CD4<sup>+</sup> cell count at baseline in the study was more than 300 cells/ $\mu$ L.<sup>13</sup> The CD4<sup>+</sup> cell count in case 2 was 112 cells/ $\mu$ L. Therefore, immune recovery uveitis was less likely.

In summary, rifabutin-associated uveitis is an acceptable and known risk of rifabutin therapy, especially co-administration of rifabutin with clarithromycin, fluconazole, or some protease inhibitors. It can be treated with topical corticosteroids and mydriatics, with favorable outcomes. The discontinuation of rifabutin therapy is suggested in patients with recalcitrant uveitis if systemic conditions permit. Early recognition of this entity can prevent invasive ocular procedures and treatments. To our knowledge, no such case had previously been reported in Taiwan. We suggest that doctors who prescribe this drug should pay more attention to the ocular complication, uveitis, and drug–drug interactions. Ophthalmologists should put this on the list of differential diagnoses for uveitis.

## References

1. CDC. Recommendations on prophylaxis and therapy for disseminated *Mycobacterium avium* complex for adults and adolescents infected with human immunodeficiency virus. *MMWR* 1993; 42(RR-9):14–20.

2. Nightingale SD, Cameron DW, Gordin FM, Sullam PM, Cohn DL, Chaisson RE, Eron LJ, et al. Two controlled trials of rifabutin prophylaxis against *Mycobacterium avium* complex infection in AIDS. *N Engl J Med* 1993;329:828–33.
3. Shafran SD, Deschenes J, Miller M, Philips P, Toma E. The MAC study Group of the Canadian HIV Trial Network: uveitis and pseudojaundice during a regimen of clarithromycin, rifabutin and ethambutol. *N Engl J Med* 1994;330:438–9.
4. Jacobs DS, Piliero PJ, Kuperwaser MG, Smith JA, Harris SD, Flanigan TP, Goldberg JH, et al. Acute uveitis associated with rifabutin used in patients with human immunodeficiency virus infection. *Am J Ophthalmol* 1994;118:717–22.
5. Saran BR, Maguire AM, Nichols C, Frank I, Hertle RW, Brucker AJ, Goldman S, et al. Hypopyon uveitis in patients with acquired immunodeficiency syndrome treated for systemic *Mycobacterium avium* complex infection with rifabutin. *Arch Ophthalmol* 1994;112:1159–65.
6. Havlir D, Torriani F, Dube M. Uveitis associated with rifabutin prophylaxis. *Ann Intern Med* 1994;121:510–2.
7. Mwanza JC, Kayembe DL. Uveitis in HIV-infected patients. *Eur J Ophthalmol* 2001;11:53–6.
8. Shafran SD, Singer J, Zarowny DP, Deschenes J, Phillips P, Turgeon F, Aoki FY, et al. Determinants of rifabutin-associated uveitis in patients treated with rifabutin, clarithromycin, and ethambutol for *Mycobacterium avium* complex bacteria: a multivariate analysis. Canadian HIV Trial Network Protocol Study Group. *J Infect Dis* 1998;177:252–5.
9. Kelleher P, Helbert M, Sweeney J, Anderson J, Parkin J, Pinching A. Uveitis associated with rifabutin and macrolide therapy for *Mycobacterium avium intracellulae* infection in AIDS patients. *Genitourin Med* 1996;72:419–42.
10. DATRI 001 Study Group. Coadministration of clarithromycin alters the concentration–time profile of rifabutin. 34<sup>th</sup> Interscience Conference on Antimicrobial Agents and Chemotherapy. Washington, DC: American Society for Microbiology 1994: Abstract A2.
11. CDC. Prevention and treatment of tuberculosis among patients infected with human immunodeficiency virus: principles of therapy and revised recommendations. *MMWR* 1998;47(RR-20):1–51.
12. CDC. Notice to readers: updated guidelines for the use of rifabutin or rifampin for the treatment and prevention of tuberculosis among HIV-infected patients taking protease inhibitors or nonnucleoside reverse transcriptase inhibitors. *MMWR* 2000; 49(RR-9):185–9.
13. Whitcup SM, Fortin E, Lindblad AS, Griffiths P, Metcalf JA, Robinson MR, Manischewitz J, et al. Discontinuation of anti-cytomegalovirus therapy in patients with HIV infection and cytomegalovirus retinitis. *JAMA* 1999;282:1633–7.