

# Ocular Uveitis as the Initial Presentation of Syphilis

May-Ching Hong<sup>1</sup>, Shwu-Juan Sheu<sup>1,2</sup>, Tsung-Tien Wu<sup>1</sup>, Chiu-Tung Chuang<sup>1\*</sup>

<sup>1</sup>Department of Ophthalmology, Kaohsiung Veterans General Hospital, Kaohsiung, and

<sup>2</sup>National Yang-Ming University School of Medicine, Taipei, Taiwan, R.O.C.

**Background:** To document the characteristics of syphilitic patients who present with ocular uveitis clinically and are diagnosed by an ophthalmologist first.

**Methods:** Retrospective chart review of uveitis patients in the department of ophthalmology between 1992 and 2004 was done. We included only those patients with positive serologic tests, active ocular uveitis, and record of detailed examination.

**Results:** There were 8 syphilitic patients (14 eyes) who presented with ocular syphilis clinically and who were diagnosed by an ophthalmologist first. The ocular diagnosis included panuveitis (11 eyes, 78.6%), anterior uveitis (2 eyes, 14.3%), and posterior uveitis (1 eye, 7.1%). Two patients (25%) had unilateral eye involvement, and 6 patients (75%) had involvement in bilateral eyes. One patient (2 eyes) with panuveitis also had bilateral exudative retinal detachment and chronic angle closure glaucoma. All 8 patients were negative for human immunodeficiency virus. Dark field examination of aqueous humor in 2 cases revealed *Treponema pallidum*, which was confirmed by immunofluorescent test. Treatment included systemic penicillin in 7 patients and oral tetracycline in 1 patient (due to penicillin allergy). Visual function and uveitis improved after treatment in all patients.

**Conclusion:** Syphilis can be presented initially as ocular uveitis without obvious systemic manifestation. Ophthalmologists play an important role in the early diagnosis and treatment of syphilis. If treated early enough, the response is good, even if the patient is allergic to penicillin. Awareness of the multiple manifestations of ocular syphilis is the key to early detection of the disease. [*J Chin Med Assoc* 2007;70(7):274–280]

**Key Words:** syphilis, *Treponema pallidum*, uveitis

## Introduction

Syphilis is a sexually transmitted, chronic, systemic infection caused by the spirochete *Treponema pallidum*. If left untreated, the disease progresses through 4 stages, with the potential to cause significant morbidity to any major organ of the body. Common syphilitic ocular manifestations, including interstitial keratitis, anterior, intermediate and posterior uveitis, chorioretinitis, retinitis, retinal vasculitis, and cranial nerve, and optic neuropathy, can occur at any stage of the disease. The ocular manifestations are highly variable, so syphilis is known as “the great masquerader”. With the emerging increased incidence of human immunodeficiency virus (HIV), syphilis is now increasing too. Ocular syphilis has even regained attention as a “new epidemic”. Involvement of

the eye may be the presenting manifestation of syphilis and is often associated with delayed diagnosis and delayed treatment, which may result in irreversible visual loss and structural changes. That is why we should have a high degree of clinical suspicion for early diagnosis and treatment, especially in those without systemic symptoms. From the aspect of public health, early diagnosis of syphilis also helps to control the spread of infection. It is known that venereal disease research laboratory (VDRL) can be nonreactive in immunocompetent and immunosuppressed syphilitic patients, and patients with concurrent HIV infection may be seronegative on all serologic tests for syphilis.

Ophthalmologists bear the responsibility of early diagnosis. Here, we report 8 cases of ocular uveitis presenting as the initial manifestation of syphilis.

\*Correspondence to: Dr Chiu-Tung Chuang, Department of Ophthalmology, Kaohsiung Veterans General Hospital, 386, Ta-Chung 1<sup>st</sup> Road, Kaohsiung 813, Taiwan, R.O.C.  
E-mail: ctchuang@vghks.gov.tw • Received: September 26, 2006 • Accepted: May 31, 2007

## Methods

We retrospectively reviewed the charts of 219 uveitis patients at the department of ophthalmology from 1992 to 2004. Recorded data included age, gender, laterality of eye involvement, visual acuity (initial and final), biomicroscopic examination, fundus examination, concomitant systemic findings, laboratory data, HIV antibody status, treatment, and course of disease. Serologic tests for syphilis included VDRL, fluorescent treponemal antibody absorption (FTA-ABS), and the *Treponema pallidum* hemagglutination (TPHA) test. The diagnosis of syphilitic uveitis was made by at least 1 positive result of serum VDRL and TPHA, together with evidence of an appropriate pattern of active ocular inflammation. All patients underwent HIV screening.

## Results

There were 8 patients (7 males, 1 female; 14 eyes) diagnosed with ocular syphilis without previous systemic manifestation of syphilis. All patients were diagnosed with syphilis by an ophthalmologist first. The mean age of the patients was 57.7 years (range, 32–82 years). Six patients had bilateral eye involvement, whereas 2 patients had unilateral involvement. The main presenting symptom in all patients was decreased visual acuity. Seven patients (11 eyes, 78.6%) were diagnosed with panuveitis, and there was anterior uveitis in 2 eyes (14.3%), and posterior uveitis in 1 eye (7.1%). Thirteen eyes disclosed anterior chamber reaction (92.8%). The most common findings of the posterior segment were vitritis and disc edema, found in 28.6% of eyes, followed by keratic precipitates (28.6%), glaucoma (28.6%), macular edema (21.4%), serous retinal detachment (14.3%), and retinitis (14.3%) (Table 1). The duration of follow-up ranged from 0.75 to 21.5 months (mean, 4.3 months).

**Table 1.** Ocular presentation in the 14 affected eyes of 8 patients

Signs	n (%)
Anterior chamber reaction	13 (92.9)
Vitritis	4 (28.6)
Keratic precipitates	4 (28.6)
Disc edema	4 (28.6)
Glaucoma	4 (28.6)
Macular edema	3 (21.4)
Serous retinal detachment	2 (14.3)
Retinitis	2 (14.3)

All patients were HIV negative. All patients had positive TPHA or VDRL test (Table 2). The diagnosis of syphilitic uveitis was made by 1 positive result of serum VDRL or combined positive TPHA when VDRL titer was low. Lumbar puncture was performed in 5 patients, with 2 of them showing positive findings. The VDRL analysis of cerebrospinal fluid was positive in 1 patient, and the FTA-ABS test was positive in another.

The initial best-corrected visual acuity (BCVA) ranged from light perception (LP) to 6/8.6, and the final BCVA ranged from 1/60 to 6/6. Improvement of vision was noted in all patients. The vision of these 8 patients gained at least 1 line, and the inflammation subsided after treatment in all patients (Table 2).

Six patients received intravenous crystal penicillin G 12–18 MU/day for 6–14 days, followed by supplementary intramuscular penicillin G 2.4 MU weekly for 3–4 weeks. One patient received intravenous penicillin for 10–14 days as primary therapy. Corticosteroid therapy was discontinued immediately after syphilis was diagnosed in case 2 and case 4. Case 8 was allergic to penicillin, and oral tetracycline 500 mg QID was prescribed for 26 days.

## Case reports

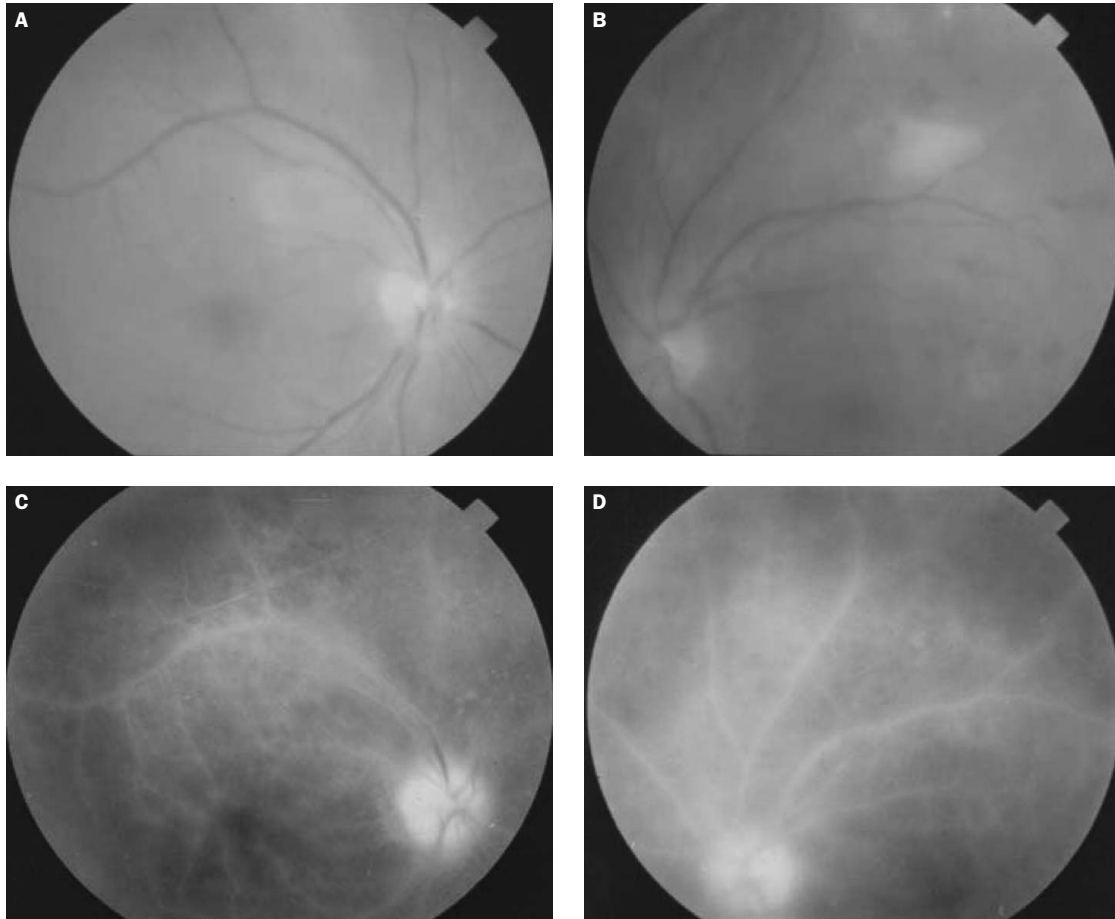
### Case 7

A 55-year-old woman complained of blurred vision for 6 months. She had received thyroidectomy because of goiter 30 years before this admission. At presentation, BCVA was 5/60 in the right eye and 6/12 in the left eye. Slit-lamp examination revealed bilateral mild cataracts and pigmentary keratic precipitates in her left cornea. The anterior chamber was 1+ cells in the left eye. Ophthalmoscopy showed bilateral disc edema, and color vision was also affected (1/21) in bilateral eyes. Under the impression of uveitis, she was admitted for further evaluation and treatment. One week later, there were multiple whitening patches accompanied by retinal hemorrhage along the temporal upper arcade in her left eye. Fluorescein angiography (FAG) revealed diffuse vascular leakage, disc staining, and choroidal leakage (Figure 1). Plasma test showed VDRL 1:128, and FTA-ABS +3. HIV antibody testing was negative. The result of lumbar puncture showed VDRL 1:4. Paracentesis revealed *Treponema pallidum* in aqueous humor through dark field microscopy, which was confirmed by immunofluorescent test (Figure 2). Except uveitis, no systemic manifestations of syphilis were found. The patient received intravenous penicillin 3 MU Q4H for 10 days, followed by intramuscular penicillin 4.8 MU QW, for 3 times. After treatment, BCVA improved to 6/30 in her right eye and 6/15 in her left eye. The abnormal FAG findings regressed after penicillin treatment.

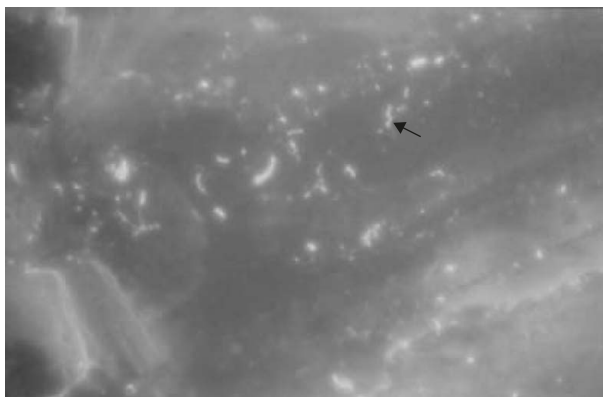**Table 2.** Demographic and clinical characteristics of patients

Case	Sex/ Age	Affected eye	Initial BCVA	Final BCVA	Ocular findings	VDRL	FTA-ABS	TPHA	Treatment	HIV	CSF	Systemic presentation	T. <i>pallidum</i> in A/C	F/U (mo)
1	M/82	OU	OD 6/60 OS 6/60	OD 6/30 OS 6/30	A/C: cell+, OU; F'd: VO.	> 1:1,024	+	> 1:1,280	PCN IV	-	VDRL-	No	NA	1
2	M/63	OU	OD CF/10 cm OS CF/5 cm	OD 6/12 OS 6/15	A/C: cell+, fine Kps, OU; F'd: cell+++, ME, OU.	1:128	+	1:5,120	MTP PCN IV, IM	-	NA	Skin rash Hx of genital ulcer	-	6.5
3	M/58	OS	OD 6/5-1 OS 6/8.6 cc	OD 6/6 OS 6/6	A/C: cell++; Kps+, OS; F'd: disc hyperemia, OS.	1:256	+	1:1,280	PCN IV, IM	-	VDRL-	Skin rash	NA	2.5
4	M/32	OD	OD CF/40 cm OS 6/6	OD 1/60 OS 6/6	A/C: cell+, OD; F'd: disc edema, snow ball, ME, OD.	1:60	NA	1:2,560	Oral steroid PCN IV, IM	-	VDRL-	No	+	0.75
5	M/58	OU	OD CF/20 cm OS 6/12	OD 6/15 OS 6/6	A/C: OD cell++, OS clear; F'd: choroid atrophy, glaucoma.	1:4	+	1:320	PCN IV, IM	-	NA	S-J joint pain	NA	2
6	M/48	OU	OD 6/20 OS 6/30	OD 6/6.7 OS 6/6.7	A/C: cell++, OU; F'd: retina, exudates, retinitis, OU.	1:1,024	+	1:1,280	PCN IV, IM	-	NA	Oral ulcer Skin rash, genital ulcer 1 year previously	-	21.5
7	F/55	OU	OD 5/60 OS 6/12	OD 6/30 OS 6/15	A/C: pigment Kps, cell+, flare+, OU; F'd: disc edema, OU, chorioretinitis, OS.	1:128	+3	NA	PCN IV, IM	-	VDRL 1:4		+	1.75
8	M/66	OU	OD LP OS LP	OD 6/12 OS 6/15	A/C: cell++, exudation, OU; F'd: total serous RD, glaucoma, OU.	1:1	2+	1:1,280	Tetracycline 500 mg QID	-	FTA-ABS 1+, VDRL-		-	3

A/C = anterior chamber; BCVA = best-corrected visual acuity; F'd = fundus; Kps = keratic precipitates; LP = light perception; MTP = methylprednisolone; ME = macular edema; NA = not available; PCN = penicillin; RD = retinal detachment; VO = vitreous opacity.



**Figure 1.** Color fundus picture of case 7 shows disc edema: (A) right eye; (B) left eye. Fluorescein angiography shows diffuse vascular leakage, disc staining, and dye pooling at the late phase: (C) right eye; (D) left eye.



**Figure 2.** *Treponema pallidum* (black arrow) in the aqueous humor is confirmed by immunofluorescent test.

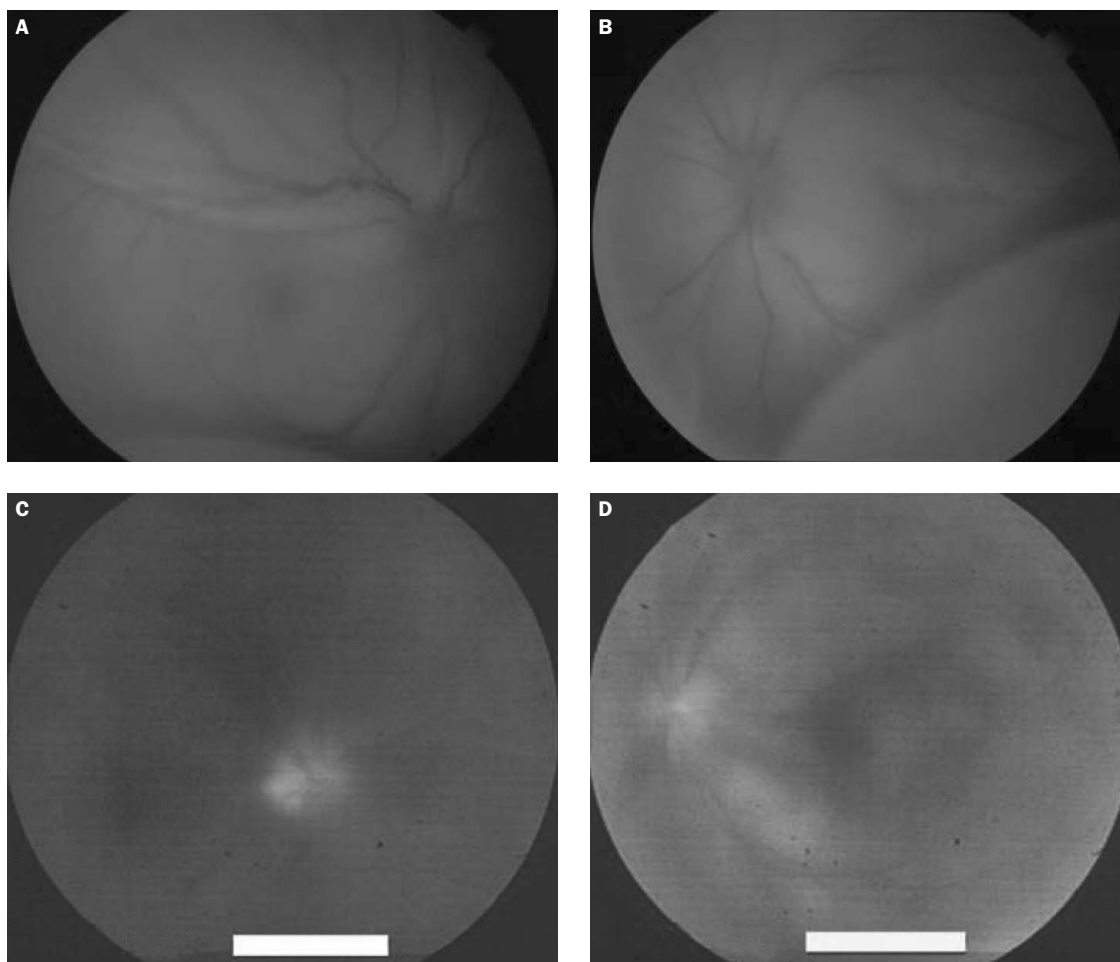
### Case 8

A 66-year-old man presented with a 7-day history of blurred vision in both eyes. The BCVA of both eyes were light perception only. Slit-lamp biomicroscopy revealed exudation and cell++ in the anterior chamber and posterior synechiae in both eyes. Ophthalmoscopy showed bilateral disc edema, and exudative retinal

detachment. Under the impression of panuveitis with exudative retinal detachment, the patient was admitted for further evaluation and treatment. Paracentesis of the left eye was negative for dark field microscopy. FAG revealed disc leakage and diffuse dye pooling at late phase (Figure 3). Plasma testing showed VDRL 1:1 and TPHA 1:1,280. HIV antibody testing was negative. The result of lumbar puncture showed FTA-ABS 1+. Except panuveitis, no other systemic manifestation of syphilis was found. As he was allergic to penicillin, the patient received oral tetracycline 500 mg QID for 26 days. After treatment, BCVA returned to 6/12 in his right eye and 6/15 in his left eye. The fundus showed attached retina and diffuse retinal pigment epithelial changes (Figure 4).

### Discussion

Syphilis is divided into primary, secondary, latent, and tertiary stages. Primary syphilis is characterized by a chancre. This painless ulceration appears 2–6 weeks

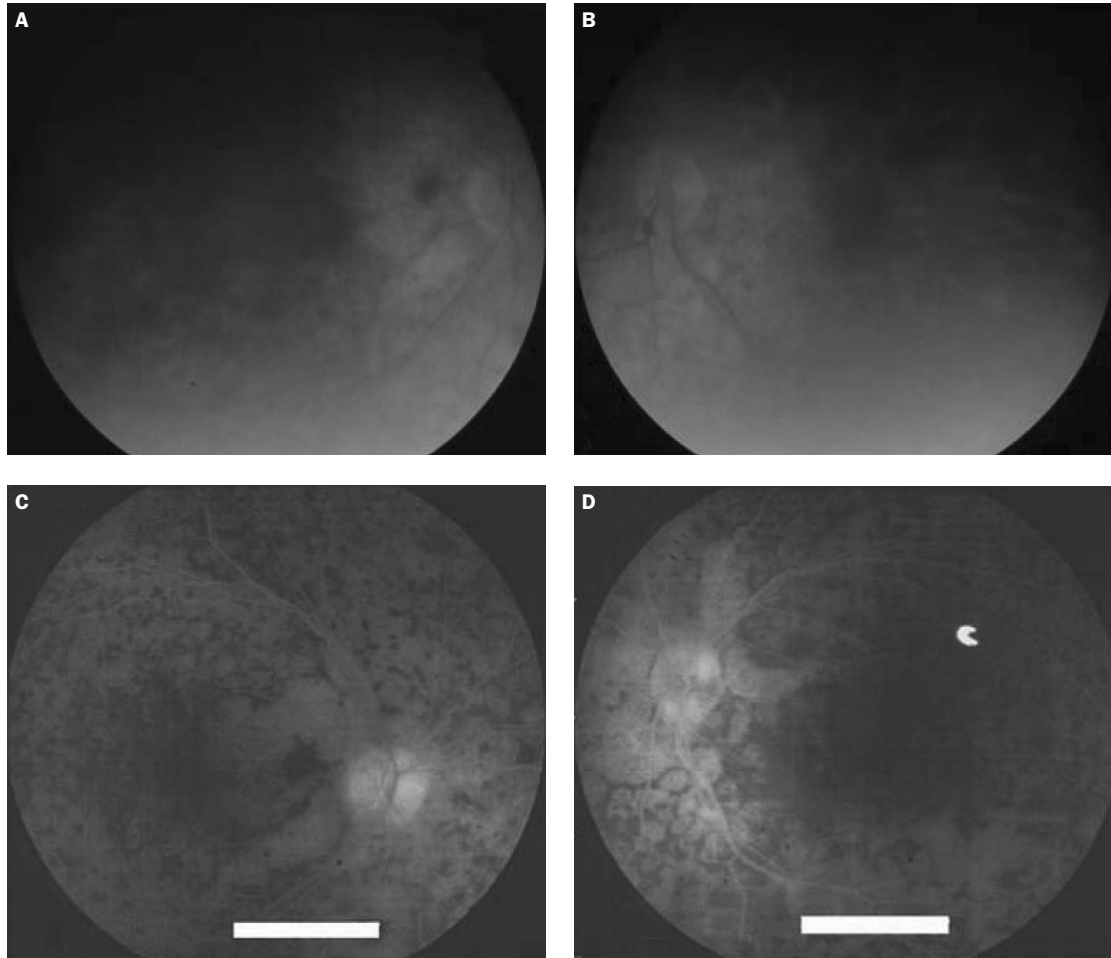


**Figure 3.** Color fundus picture of case 8 shows total retinal detachment and disc edema: (A) right eye; (B) left eye. Fluorescein angiography shows disc leakage and diffuse dye pooling at the late phase: (C) right eye; (D) left eye.

after infection and normally resolves within 3–6 weeks. The most common sign of secondary syphilis is diffuse maculopapular rash, which tends to resolve in all patients. If left untreated, patients will progress to tertiary syphilis, which manifests cardiovascular disorders and neurosyphilis.<sup>1</sup> The diagnosis of syphilis can easily be missed if the systemic signs and symptoms have resolved. Syphilis is known as “the great masquerader”, and can affect all of the structures of the eye. Many infective and inflammatory diseases are also imitated by ocular syphilis, like candidiasis, toxoplasmosis, Wegener’s granulomatosis, sarcoidosis, and tuberculosis. The uveitis routine is done in all suspected cases, including rheumatoid factor, antinuclear antibody, VDRL, chest X-ray, blood routine, urine routine, and FAG, for differential diagnosis.

The ophthalmologic manifestations of syphilis include uveitis, retinitis, scleritis, vitritis, retinal vasculitis, optic nerve involvement, and papillary abnormality. Ocular involvement in syphilis mainly occurs in the secondary and tertiary stages.<sup>2–4</sup> Barile and Flynn<sup>5</sup>

reported that the most common manifestation of syphilitic inflammation was iridocyclitis (71%, 17/24 patients), followed by panuveitis (13%, 3/24 patients), posterior uveitis (8%, 2/24 patients), and keratouveitis (8%, 2/24 patients). In our series, 7 patients (11 eyes, 78.6%) were diagnosed with panuveitis, and there was anterior uveitis in 2 eyes (14.3%), and posterior uveitis in 1 eye (7.1%). Jumper et al<sup>6</sup> described 3 cases of exudative retinal detachment in syphilis, and the choroids presented with thickening in all 3 cases. The visual outcome of these was poor, with 1/200 or worse in 3 of 4 eyes with exudative retinal detachment. Although choroidal thickening is a finding in the active stage, this persistent inflammation may lead to chorioretinal atrophy in the late stage, which is the main cause of poor vision. However, delayed treatment may be another reason for poor vision. We had 1 case of bilateral serous retinal detachment accompanied with panuveitis in case 8. Even though he was allergic to penicillin, the subretinal fluid resolved after oral tetracycline treatment, and



**Figure 4.** After antibiotic therapy, the retina was attached and showed diffuse retinal pigment epithelial changes: (A) right eye; (B) left eye. Fluorescein angiography shows multiple foci of hyperfluorescence and hypofluorescence, which correspond to diffuse retinal pigment epithelial changes: (C) right eye; (D) left eye.

vision improved. Early treatment will lead to good prognosis, just as for systemic involvement of syphilis. If there is delay in antibiotic therapy, many severe complications will result in poor vision.<sup>7,8</sup>

*Treponema pallidum* does not grow in routine culture media, and the diagnosis of syphilis mainly depends on the serologic test and clinical features. Although rarely obtained, direct microscopy is considered a highly specific test for syphilis. The infective specimens can be obtained not only from a chancre or lymph node aspiration, but also from the ocular specimen. The identification of spirochetes from aqueous humor by dark field microscopy confirmed the syphilitic nature of the uveitis in our 2 patients. They were further confirmed by immunofluorescent test. The direct identification of *Treponema pallidum* from aqueous humor indicated the active ocular syphilis.<sup>4,8</sup> Serologic tests, including VDRL, FTA-ABS and TPHA, can be false positive or false negative clinically, especially in the co-infection of syphilis and HIV. The clinical presentations

of syphilis can be confused with HIV co-infection. Currently, co-infection of HIV and syphilis has increased, and it is thought to be related to high-risk sexual behavior. Fortunately, all our cases showed negative HIV test. The co-infection of syphilis and HIV will accelerate the progression of ocular syphilis and the natural course of syphilis, but does not affect response to a neurosyphilis regimen of penicillin in the short term.<sup>9-11</sup> Therefore, we suggest that HIV and syphilitic serologic tests should be routinely checked in ocular inflammation. Penicillin remains the standard treatment for syphilis. The recommended regimen for treatment of ocular syphilis is the same as that for neurosyphilis. If the patient is allergic to penicillin, like case 8, then oral tetracycline is a good alternative. Early diagnosis and treatment will usually preserve visual acuity and ocular function. As ocular syphilis can mimic any type of ocular inflammation and may be the initial presentation of syphilis, ophthalmologists must have a high degree of clinical suspicion in

unspecific ocular inflammation. Early detection and prescription are imperative to save the eyes.

## References

1. Wilhelmus KR, Lukehart SA. Syphilis. In: Pepose JS, Holland GN, Wilhelmus KR, eds. *Ocular Infection & Immunity*. St. Louis: Mosby, 1996:1437–66.
2. Deschenes J, Seamone CD, Baines MG. Acquired ocular syphilis: diagnosis and treatment. *Ann Ophthalmol* 1992;24:134–8.
3. Schlaegel TF, Kao SF. A review (1970–1980) of 28 presumptive cases of syphilitic uveitis. *Am J Ophthalmol* 1982;93:412–4.
4. Aldave AJ, King JA, Cunningham ET Jr. Ocular syphilis. *Curr Opin Ophthalmol* 2001;12:433–41.
5. Barile GR, Flynn TE. Syphilis exposure in patients with uveitis. *Ophthalmology* 1997;104:1605–9.
6. Jumper JM, Macheimer R, Gallemore RP, Jaffe GJ. Exudative retinal detachment and retinitis associated with acquired syphilitic uveitis. *Retina* 2000;20:190–4.
7. Pao D, Goh BT, Bingham JS. Management issues in syphilis. *Drugs* 2002;62:1447–61.
8. Margo CE, Hamed LM. Ocular syphilis. *Surv Ophthalmol* 1992;37:203–20.
9. Browning DJ. Posterior segment manifestations of active ocular syphilis, their response to a neurosyphilis regimen of penicillin therapy, and the influence of human immunodeficiency virus status on response. *Ophthalmology* 2000;107:2015–23.
10. Liu IH, Chen SJ, Chung YM, Chiou SH, Wong WW. Syphilitic uveitis as the initial manifestation of HIV infection. *J Formos Med Assoc* 2002;101:642–5.
11. Thami GP, Kaur S, Gupra R, Kanwar AJ, Sood S. Syphilitic panuveitis and asymptomatic neurosyphilis: a marker of HIV infection. *Int J STD AIDS* 2001;12:754–6.