

A Missing Silk Strip During Laparoscopic Radical Cystectomy and Bilateral Nephroureterectomy

Yu-Lung Chang, Hsiao-Jen Chung*, Kuang-Kuo Chen

Division of Urology, Department of Surgery, Taipei Veterans General Hospital, and Department of Urology, National Yang-Ming University School of Medicine, Taipei, Taiwan, R.O.C.

Many accidents and complications may occur intraoperatively and postoperatively. Herein, we present an intraoperative accident of a missing yellowish silk strip, which was sucked out by a hook cautery and suction probe during laparoscopic radical cystectomy and bilateral nephroureterectomy. [*J Chin Med Assoc* 2007;70(8):350–351]

Key Words: complication, laparoscopy, radical cystectomy and bilateral nephroureterectomy, silk strip

Introduction

Laparoscopic surgery is not only used in obstetrics and gynecology,^{1,2} but also in urology. Invasive urothelial carcinoma can be treated with radical cystectomy with an open method³ or a laparoscopic method.⁴ Many accidents and complications may occur intraoperatively and postoperatively.^{5,6} Some accidents, though we would never have imagined them, just happen. Herein, we present an intraoperative accident of a missing yellowish silk strip, which was sucked out by a hook cautery and suction probe during laparoscopic radical cystectomy and bilateral nephroureterectomy.

Case Report

A 76-year-old female had suffered from end-stage renal disease with hemodialysis for 1 year. She also had congestive heart failure, acute pulmonary edema, hypertension, and bilateral hip joint arthritis status post bilateral total hip replacement. Owing to gross hematuria noted recently, she came to our outpatient department for help. Urine routine showed red blood cells 3+/high powered field (HPF) and white blood cells 2+/HPF. Sonography showed a big heterogeneous echoic mass lesion measuring 6.9 × 3.8 cm in the urinary bladder. Cystoscopy showed a huge bladder

tumor over the trigone and right lateral wall. Pathology of the bladder tumor biopsy revealed papillary urothelial carcinoma, high grade. Bone scan showed no bony metastasis. The bladder condition could not be well evaluated by computed tomography due to severe artifacts induced by the bilateral total hip replacement implants.

Due to gross hematuria again on May 31, 2004, the patient presented to our emergency room for help. Physical examination showed nothing particular except no vagina and only a valve-like structure over the perineal area. Agenesis of Müllerian duct was suspected by the gynecologist. Transurethral resection of the bladder tumor was performed, and pathology showed invasive papillary urothelial carcinoma, high grade, pT1. Thereafter, the patient received laparoscopic radical cystectomy and bilateral nephroureterectomy on June 24, 2004. The operative findings were a tumor mass over the right lateral wall and trigone of the urinary bladder near the bladder neck, no uterine and vagina development, bilateral intact ovaries and bilateral atrophic kidneys. During the operation, a yellowish silk strip (3 × 170 mm) was used to loop the ureter. However, the yellowish silk strip disappeared 30 minutes later. Due to its radiolucent character,⁷ we did not use portable X-ray to search for the missing yellowish silk strip. We searched the peritoneal cavity for 60 minutes but in vain, so we decided to continue

*Correspondence to: Dr Hsiao-Jen Chung, Division of Urology, Department of Surgery, Taipei Veterans General Hospital, 201, Section 2, Shih-Pai Road, Taipei 112, Taiwan, R.O.C.
E-mail: hjchung@vghtpe.gov.tw • Received: December 15, 2006 • Accepted: June 11, 2007

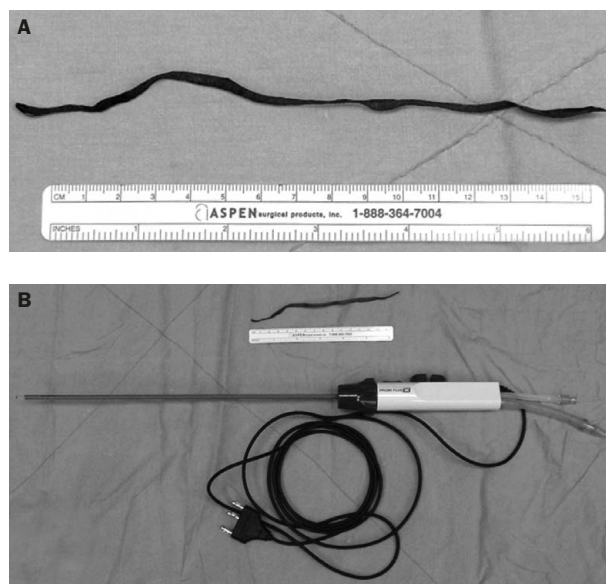


Figure 1. (A) The yellowish silk strip. (B) The yellowish silk strip, hook cautery and suction probe device.

with the operation. At the end of the operation, we tried our best again to find the silk strip. We reviewed the operative video record and searched the peritoneal cavity again laparoscopically. Then we extended the lower abdomen mini-laparotomy wound, which was used to remove the whole specimen and check the entire potential intraperitoneal space. We spent 2 hours searching, but nothing could be found. Finally, the silk strip was found in the suction bottle. The yellowish silk strip had been sucked out by the hook cautery and suction probe (Endopath Electrosurgery Probe Plus II; Ethicon Endo-Surgery Inc.) (Figure 1). The operative time was 15 hours and 55 minutes, including the time taken to search for the strip. Unfortunately, extrapyramidal syndrome (EPS) occurred on the second postoperative day after operation. After biperiden treatment, EPS improved, but delirium occurred thereafter. After stopping biperiden and estazolam use, the patient recovered uneventfully. The final pathology report showed an invasive urothelial carcinoma of the urinary bladder, high grade, pT2a. Thereafter, the patient was followed-up at our outpatient department, and no recurrence has been noted till now.

Discussion

This accident of a silk strip being sucked out by a hook cautery and suction probe during laparoscopic surgery is the first such case reported. Though the diameter of the hook cautery and suction probe was

only 5 mm, the yellowish silk strip was sucked out. Since then, we always fix the silk strip with endoclips when we use it for looping the ureter, and no further similar accidents have occurred. Tracing back the operative video record, we found some reasons for why we did not notice the accident immediately. The first one was that the yellowish silk strip was difficult to distinguish from the surrounding tissue and blood when the yellowish silk strip was soaked with blood. The second reason was that we had not fixed the 2 ends of the silk strip with any instrument. The third reason was that when the strip was sucked, the strip was immersed in blood and no one noticed. The small diameter, < 5 mm, of the suction probe channel, the hook probe inside the already narrow channel, and the relatively long yellowish silk strip, 3 × 170 mm, made us think that the strip would be impossible to be sucked out without our noticing. So we did not check the suction bottle immediately when the yellowish strip was missing. Because silk is a radiolucent material,⁷ we did not use portable X-ray to search for the missing silk strip. The most probable location of the missing silk strip was in the abdominal cavity, so we spent a lot of time searching for it in the abdominal cavity. The methods by which this type of accident may be prevented are to use silk strips with a radio-opaque mark or vessel loops to loop the ureter and fix the ends with endoclips. By these means, we have not subsequently lost any silk strips during laparoscopic surgery.

References

1. Ding DC, Chen SS. Conservative laparoscopic management of ovarian teratoma torsion in a young woman. *J Chin Med Assoc* 2005;68:37–9.
2. Chen JS, Ho ES, Chen MJ. Operative laparoscopy in benign cystic teratoma of ovary. *J Chin Med Assoc* 1992;50:194–7.
3. Wen YC, Kuo JY, Chen KK, Lin AT, Chang YH, Hsu YS, Chang LS. Urothelial carcinoma of the urinary bladder in young adults—clinical experience at Taipei Veterans General Hospital. *J Chin Med Assoc* 2005;68:272–5.
4. Berglund RK, Matin SF, Desai M, Kaouk J, Gill IS. Laparoscopic radical cystoprostatectomy with bilateral nephroureterectomy: initial report. *BJU Int* 2006;97:37–41.
5. Parsons JK, Varkarakis I, Rha KH, Jarrett TW, Pinto PA, Kavoussi LR. Complications of abdominal urologic laparoscopy: longitudinal five-year analysis. *Urology* 2004;63:27–32.
6. Simon SD, Castle EP, Ferrigni RG, Lamm DL, Swanson SK, Novicki DE, Andrews PE. Complications of laparoscopic nephrectomy: the Mayo clinic experience. *J Urol* 2004;171:1447–50.
7. Schmutz F, McAuliffe W, Anderson DM, Elliott JP, Eskridge JM, Winn HR. Embolization of cerebral arteriovenous malformations with silk: histopathologic changes and hemorrhagic complications. *AJNR Am J Neuroradiol* 1997;18:1233–7.