

# Prenatal 3- and 4-dimensional Ultrasonographic Findings of Giant Fetal Nuchal Hemangioma

Jenn-Jhy Tseng<sup>1,3,4\*</sup>, Min-Min Chou<sup>1</sup>, Wen-Hsein Chen<sup>2</sup>

Departments of <sup>1</sup>Obstetrics and Gynecology and <sup>2</sup>Radiology, Taichung Veterans General Hospital, <sup>3</sup>Hung-Kuang University, Taichung, and <sup>4</sup>Institute of Clinical Medicine, National Yang-Ming University School of Medicine, Taipei, Taiwan, R.O.C.

A precise prenatal diagnosis of hemangioma may be uncertain although a variety of the antenatal appearances on 2-dimensional sonography have been reported. A 27-year-old primigravida was referred at 32 weeks of gestation for evaluation of a fetal nuchal mass. Two-dimensional sonography showed an extracranial mixed echogenic mass (65 × 54 × 59 mm) occupying the posterior neck. Color Doppler imaging revealed intense hypervascularization. Three-dimensional (3D) and 4-dimensional (4D) sonography showed that the mass was lobulated, with a lumpy internal structure. Nuchal hemangioma was further confirmed by clinical examination and postnatal magnetic resonance imaging. The tumor began to regress in size when the infant was 7 months old. Prenatal 3D/4D ultrasound techniques could be considered as complementary diagnostic tools for such a tumor. They have the advantages of providing accurate and inexpensive virtual reality images through more realistic interactions with the virtualized *in utero* condition. [*J Chin Med Assoc* 2007; 70(10):460–463]

**Key Words:** fetal nuchal tumor, hemangioma, magnetic resonance imaging, prenatal diagnosis, ultrasonography

## Introduction

Hemangiomas are the most common benign tumor in infancy, affecting approximately 10% of infants.<sup>1</sup> More than half of hemangiomas involve the head and neck. The prenatal diagnosis of hemangiomas can be challenging, and precise diagnosis may be controversial but is essential to ensure optimal peripartum management. We report a case of a giant nuchal hemangioma prenatally assessed and characterized by 3-dimensional (3D) and 4-dimensional (4D) ultrasonography, and which was confirmed by postnatal magnetic resonance imaging (MRI).

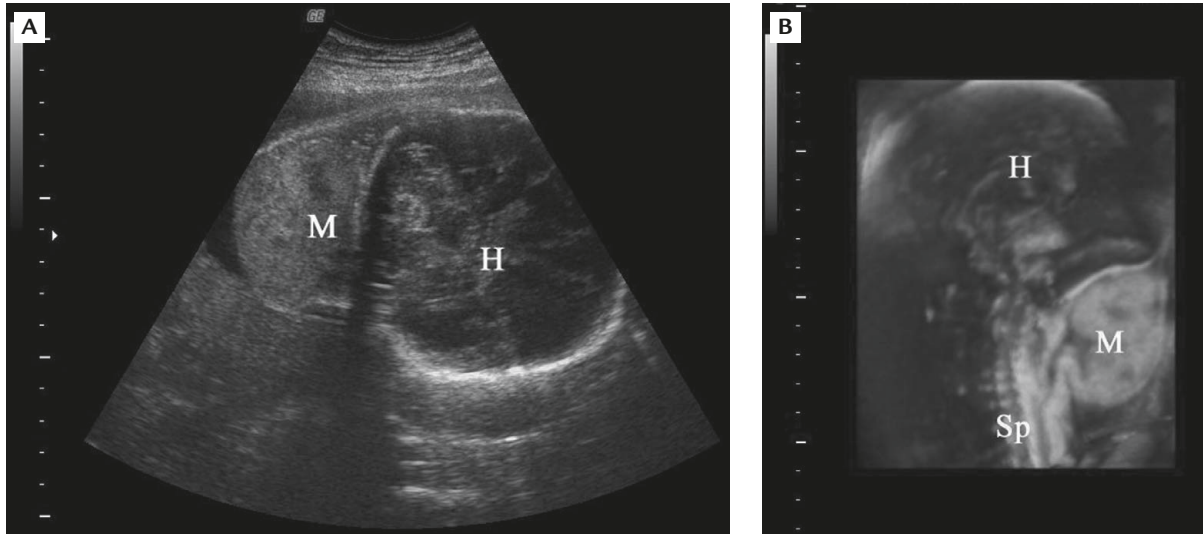
## Case Report

A 27-year-old primigravida was referred to our hospital for prenatal care at 32 weeks of gestation because of a suspected fetal neck tumor. Fetal 2-dimensional (2D) ultrasonography showed a neck mass with mixed

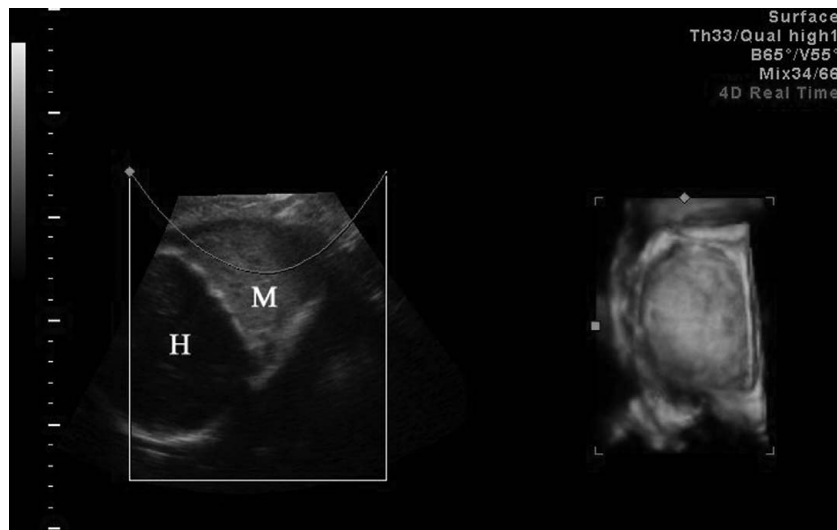
echogenicity, measuring 65 × 54 × 59 mm in size (Figure 1A). Color Doppler study revealed prominent hypervascularization in the tumor, with a resistance index of 0.52. No polyhydramnios, cardiomegaly, tricuspid regurgitation, hydropic changes, or other fetal abnormalities were visualized. 3D ultrasound with a Voluson 730 Expert system (GE Medical Systems, Kretztechnik, Zipf, Austria) equipped with 4–8 MHz motor-driven curvilinear probes demonstrated a lobulated subcutaneous mass over the fetal posterior neck (Figure 1B). The brain parenchyma and spine had no apparent abnormalities. Following counseling, the patient was re-evaluated on a weekly basis. At 36 weeks of gestation, follow-up 2D sonogram revealed that the mass had enlarged slightly. 4D (real-time 3D) ultrasound showed a lumpy and multiloculated appearance inside the mass (Figure 2). At the same time, the fetus was hemodynamically stable and non-stress testing was reassuring.

An elective Cesarean section was performed at 37 weeks of gestation. A male baby weighing 2,998 g was

\*Correspondence to: Dr Jenn-Jhy Tseng, Department of Obstetrics and Gynecology, Taichung Veterans General Hospital, 160, Section 3, Taichung-Kang Road, Taichung 407, Taiwan, R.O.C.  
E-mail: t1018@vghtc.gov.tw • Received: March 19, 2007 • Accepted: August 15, 2007



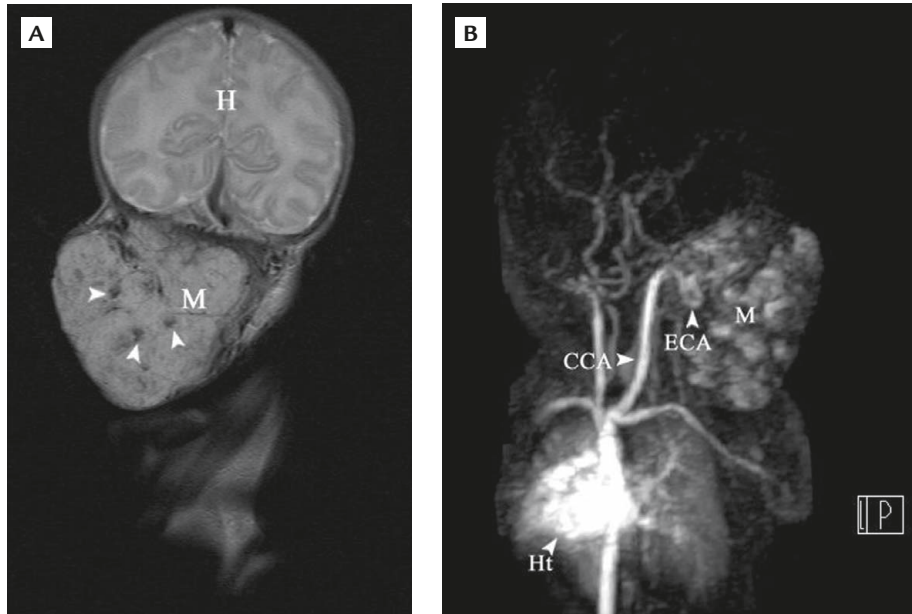
**Figure 1.** Sonograms at 32 weeks of gestation: (A) 2D ultrasound (axial view) shows a soft tissue mass (M) with mixed echogenicity emanating from the fetal posterior neck; (B) 3D ultrasound (sagittal view) reveals a lobulated subcutaneous mass (M) over the posterior neck without involvement of the spine (Sp) and brain tissues. H = head.



**Figure 2.** Four-dimensional ultrasound at 36 weeks of gestation demonstrates a subcutaneous mass (M) in the fetal posterior neck with a lumpy multiloculated appearance inside the mass. H = head.

born, with Apgar scores of 8 and 9 at 1 and 5 minutes, respectively. Neonatal examination showed that the lesion was non-pedunculated with a bluish-purple color. The lesion occupied an intact area of about  $90 \times 80$  mm over the right posterior neck region. The infant's hemoglobin and platelet counts were 12.5 g/dL and  $172 \times 10^3$  cells/ $\mu$ L, respectively. There was no evidence of high-output heart failure, microangiopathic anemia, thrombocytopenia, or consumption coagulopathy after birth. Neonatal MRI, including contrast-enhanced magnetic resonance angiography, demonstrated a multiloculated hypervascular neck mass

with multiple signal voids (i.e. high velocity flows) in the lesion supplied by an engorged occipital branch of the right external carotid artery (Figure 3). The findings were therefore consistent with a diagnosis of hemangioma. As there were no apparent complications (such as obstruction, ulceration, bleeding, infection, associated anomalies, or high-output heart failure), after a detailed discussion with his parents, the infant received monthly follow-up without medical or surgical intervention. The tumor began to regress in size when the infant was 7 months of age. The karyotype was 46,XY.



**Figure 3.** (A) Neonatal coronal T2-weighted magnetic resonance imaging shows a soft tissue mass (M) over the right posterior neck and occipital regions, and multiple foci of signal voids (arrowheads) confirm the presence of fast-moving vascular structures within the mass. H = head. (B) Contrast-enhanced magnetic resonance angiography (oblique coronal plane) in the arterial phase shows a hypervascular and multiloculated lesion with blood supply from an engorged occipital branch of the right external carotid artery (ECA). CCA = common carotid artery; Ht = heart; M = mass.

## Discussion

Hemangiomas, usually capillary and cavernous histologic types, can proliferate *in utero* and manifest as fully grown tumors at birth. They begin to regress during early infancy.<sup>2</sup> In the majority of patients with uncomplicated hemangiomas, natural involution remains a viable treatment option. Surgical excision, cryosurgery, laser therapy, pharmacologic remedies, and strangulation of the feeder vessel are indicated for a subset of patients with complicated hemangioma.<sup>3</sup> Recently, the implication of an association between readily identifiable fetal vascular masses in the first trimester of pregnancy and Down syndrome has been reported.<sup>4</sup>

The presence of sonolucent spaces in the mixed echogenic mass found on prenatal 2D ultrasound, together with the detection of pulsating Doppler flow signals, are reasonably suggestive of a fetal hemangioma.<sup>5</sup> The diverse findings of echogenicity in the mass is frequently encountered and may be attributed to the vascular type, degenerative process, thrombosis formation, calcification, and endothelial cell proliferation.<sup>6</sup> Therefore, it may be difficult to differentiate between hemangiomas and other soft tissue masses by conventional 2D ultrasound alone, and the absence of blood flow signals does not exclude such a diagnosis.<sup>6,7</sup> In the case reported here, 3D and 4D ultrasound reconstruction of the internal structure of the

mass showed a multiloculated and lumpy appearance that was not demonstrated on the conventional 2D ultrasound. This imaging finding was consistent with the appearance on gross section cutting of such a mass.<sup>8</sup> To the best of our knowledge, this case represents a novel report in the literature that includes both 3D and 4D images used for the virtual reality rendition of a giant fetal neck hemangioma. Compared with 3D reconstruction, the usefulness of 4D sonography in prenatal diagnosis lies in being able to obtain a real-time image in a less labor-intensive manner. However, 3D and 4D images might be considered as complementary diagnostic tools in our present case, although the perinatal management of this condition probably could not be altered.

Furthermore, postnatal MRI in our case, including magnetic resonance angiography, showed not only multiple signal voids and the feeding vessel, but the hypervascular and multiloculated structure in the mass, specifically confirming the diagnosis of a hemangioma. Compared with postnatal magnetic resonance angiographic findings, the lumpy multiloculated appearance inside the mass shown on the prenatal 4D ultrasound is compatible with the large dilated vascular channels commonly found in hemangiomas.

A variety of the antenatal appearances of hemangiomas on 2D sonography have been reported.<sup>5-7,9</sup> However, a precise prenatal diagnosis may be uncertain.

Although the superiority of 3D and 4D sonography over 2D ultrasound and color Doppler is unclear, 3D/4D ultrasound techniques could be considered as alternative diagnostic tools and provide a better spatial vision of the surface and anatomic boundary of fetal structures.<sup>10</sup> They have the advantages of being able to provide accurate and inexpensive virtual reality images through more realistic interactions with the virtualized *in utero* condition.

## References

1. Macarthur CJ. Head and neck hemangiomas of infancy. *Curr Opin Otolaryngol Head Neck Surg* 2006;14:397–405.
2. Boon LM, Enjolras O, Mulliken JB. Congenital hemangioma: evidence of accelerated involution. *J Pediatr* 1996;128:329–35.
3. Dinehart SM, Kincannon J, Geronemus R. Hemangiomas: evaluation and treatment. *Dermatol Surg* 2001;27:475–85.
4. Prefumo F, Ierullo AM, Fulcheri E, Venturini PL, De Biasio P, Thilaganathan B. A newly described thoracic vascular malformation in fetuses with Down syndrome. *Ultrasound Obstet Gynecol* 2005;26:218–20.
5. Shiraishi H, Nakamura M, Ichihashi K, Uchida A, Izumi A, Hyodoh H, Momoi MY. Prenatal MRI in a fetus with a giant neck hemangioma: a case report. *Prenat Diagn* 2000;20:1004–7.
6. Tseng JJ, Chou MM, Lee YH, Ho ESC. Prenatal diagnosis of cardiac hemangioma. *Ultrasound Obstet Gynecol* 1999;13:363–5.
7. Yoshida S, Kikuchi A, Naito S, Nakamura H, Hayashi A, Noguchi M, Kondo Y, Nakamura T. Giant hemangioma of the fetal neck, mimicking a teratoma. *J Obstet Gynaecol Res* 2006;32:47–54.
8. Schoen FJ, Cotran RS. Blood vessels. In: Cotran RS, Kumar V, Collins T, eds. *Pathologic Basis of Disease*. Philadelphia: WB Saunders, 1999:493–541.
9. Knox EM, Muamar B, Thompson PJ, Lander A, Chapman S, Kilby MD. The use of high resolution magnetic resonance imaging in the prenatal diagnosis of fetal nuchal tumors. *Ultrasound Obstet Gynecol* 2005;26:672–5.
10. Hung JH. Three-dimensional ultrasound with surface rendering for the study of fetal small parts. *J Chin Med Assoc* 2001;64:1–8.