

# Uveitis with Biopsy-proven Sarcoidosis in Chinese—A Study of 60 Patients in a Uveitis Clinic Over a Period of 20 Years

Yu-Mei Chung<sup>1\*</sup>, Ying-Cheng Lin<sup>1</sup>, Yin-Tzu Liu<sup>1</sup>, Shi-Chuan Chang<sup>2</sup>, Han-Nan Liu<sup>3</sup>, Wen-Hu Hsu<sup>4</sup>  
<sup>1</sup>*Uveitis Service, Department of Ophthalmology, National Yang-Ming University School of Medicine and Taipei Veterans General Hospital;* <sup>2</sup>*Institute of Emergency and Critical Care Medicine, National Yang-Ming University School of Medicine, and Department of Chest Medicine, Taipei Veterans General Hospital;* and <sup>3</sup>*Department of Dermatology, and* <sup>4</sup>*Division of Thoracic Surgery, Department of Surgery, Taipei Veterans General Hospital and National Yang-Ming University School of Medicine, Taipei, Taiwan, R.O.C.*

**Background:** The aim of this study was to assess the clinical features of uveitis with biopsy-proven sarcoidosis in Chinese patients.

**Methods:** This was a retrospective study of uveitis patients with biopsy-proven sarcoidosis who consecutively visited the uveitis clinic of Taipei Veterans General Hospital from 1986 to 2005. Medical records were reviewed to obtain demographic data, initial symptoms, biopsy sites, pulmonary conditions detected by chest X-ray and manifestations of uveitis. From 2002 onwards, patients also received chest computed tomography (CT).

**Results:** A total of 60 uveitis patients with biopsy-proven sarcoidosis were identified. Forty-four patients (73%) were found in the last 4 years. Female predominance with a male-to-female ratio of 1:6.5 was found. The most common initial symptom was uveitis in 41 patients (68%). The most common positive biopsy sites were mediastinal lymph nodes, lung, conjunctiva and skin. Twenty (90.9%) of 22 patients with chest X-ray stage 0 showed  $\geq$  stage 1 on CT. The mean age at uveitis onset was  $47.7 \pm 14.7$  years (range, 21–76 years), with no gender difference ( $p = 0.913$ ). A peak incidence was found in the 6<sup>th</sup> decade of life. There was bilateral eye involvement in 54 patients (90%). Frequency of the manifestations of uveitis showed isolated anterior uveitis in 2 patients (3.3%), isolated posterior uveitis in 8 patients (13.3%), intermediate and posterior uveitis (i.e. anterior uveitis sparing) in 16 patients (26.7%), and panuveitis in 34 patients (56.7%).

**Conclusion:** A marked increase was noted since 2002. One of the causes is the performance of chest CT. Chest CT is useful to discover mediastinal lymphadenopathy and other lesions suggestive of sarcoidosis, as well as to help guide tissue confirmation in patients with peculiar uveitis features indicative of sarcoidosis. Female predominance and peak incidence of uveitis onset in the 6<sup>th</sup> decade of life were found. The posterior segment was the most common localization of uveitis in biopsy-proven sarcoidosis in Chinese. [*J Chin Med Assoc* 2007;70(11):492–496]

**Key Words:** Asia, Chinese, sarcoid uveitis, sarcoidosis, uveitis

## Introduction

Sarcoidosis is a multisystemic granulomatous disease of unknown origin, characterized by widespread non-caseating epithelioid cell granuloma. Major organs involved are the chest, skin, eyes, liver, extrapulmonary lymph nodes and many other places in the body. The course of sarcoidosis ranges from asymptomatic to

severe and even lethal disease. It occurs worldwide but is predominant in certain ethnic and racial groups such as US blacks, Scandinavian and Irish white people. In contrast, the disease is rare in India, Southeast Asia, New Zealand and China.<sup>1,2</sup>

Uveitis is thought to be the most common ocular manifestation in sarcoidosis.<sup>3–5</sup> It may progress to severe visual impairment or even blindness. Uveitis with

\*Correspondence to: Dr Yu-Mei Chung, Uveitis Service, Department of Ophthalmology, Taipei Veterans General Hospital, 201, Section 2, Shih-Pai Road, Taipei 112, Taiwan, R.O.C.  
 E-mail: ym\_chang@vghtpe.gov.tw • Received: April 2, 2007 • Accepted: October 16, 2007

sarcoidosis occurs in more than 10% of uveitis patients in many areas, including some areas of the United States, Japan and the cities of Amsterdam and Rotterdam.<sup>3</sup> But it was absent in a large study that included 1,752 Chinese patients with uveitis.<sup>6</sup> Also, as noted in our previous report,<sup>7</sup> uveitis with sarcoidosis was found in just 1 in 240 cases from 1984 to 1986.

The manifestations of uveitis in sarcoidosis are variable in certain ethnic and racial groups. A high frequency of anterior uveitis is noted mainly in studies where the majority of patients are black.<sup>8,9</sup> In contrast, posterior uveitis is the most common localization of sarcoid uveitis in white patients.<sup>8,10</sup> Panuveitis is thought to be the most common type in Japanese,<sup>11</sup> but there is no information on Chinese patients.

However, there has been a notable increase in the number of patients with uveitis that consequently led to the diagnosis of sarcoidosis recently.<sup>12</sup> The present study aimed to analyze the clinical demographics of uveitis with biopsy-proven sarcoidosis in Chinese patients.

## Methods

Data collection for the purpose of this study was approved by the institutional review board of Taipei Veterans General Hospital, Taipei, Taiwan. All patients included in the study were Chinese who consecutively visited the uveitis clinic at Taipei Veterans General Hospital during a period of 20 years between 1986 and 2005. A retrospective chart review was performed. All patients were observed for at least 6 months. We confined our review to patients seen by 1 author only (Chung YM) for consistency.

Diagnosis of sarcoidosis was made on the basis of the presence of non-caseating granuloma on tissue biopsy together with a compatible picture of uveitis. Other granuloma-forming processes, such as tuberculosis, fungal infection, and various foreign bodies, had been excluded.<sup>4,13</sup>

Each patient referred to this clinic had a special chart that was used to record the detailed data concerning uveitis history, results from complete ophthalmologic examinations and associated systemic conditions. All patients were referred by either a general ophthalmologist or a pulmonologist. When the manifestations of uveitis were highly suggestive of sarcoidosis, a chest radiograph (CXR) was performed. In addition, since 2002, patients also received chest computed tomography (CT). The modified Scadding classification of lung involvement has been widely accepted. Stage 0 means no abnormality; Stage I, lymph node

enlargement; Stage II, lymph node enlargement accompanied by pulmonary infiltration; Stage III, pulmonary infiltration with no lymph node enlargement; and Stage IV, evidence of pulmonary fibrosis with retraction of the hilar areas cephalad, cystic change and bullae.<sup>13</sup>

Histologic proof of the diagnosis was frequently obtained from biopsy of the lung by bronchoscopy or CT-guided examination, mediastinal lymph node by mediastinoscopy, liver or spleen by sonoguided methods. Conjunctival biopsy was by a blind method.<sup>12</sup> Some patients received biopsy at more than 1 site.

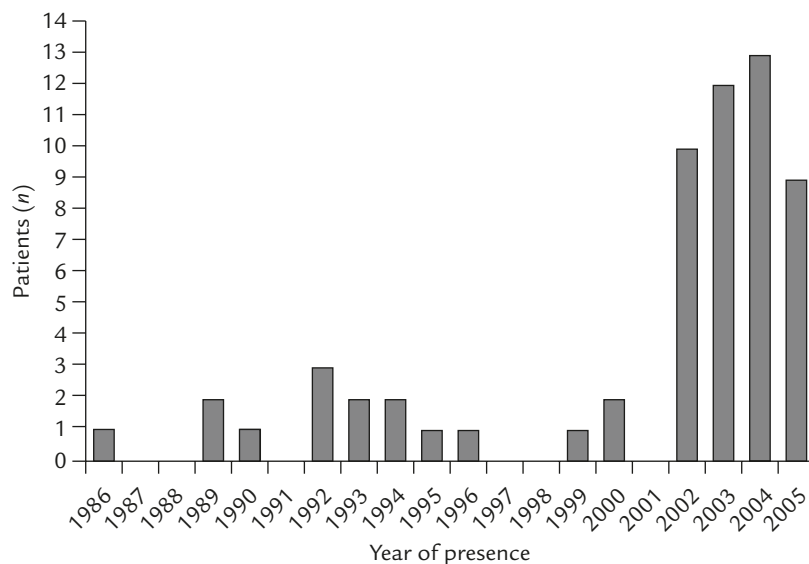
Uveitis was classified as anterior, intermediate, posterior and panuveitis by the Standardization of Uveitis Nomenclature (SUN) working group.<sup>14</sup> Anterior uveitis was defined as inflammation of the anterior segment presenting medium to large mutton-fat-like keratic precipitates, peripheral anterior synechiae, posterior synechiae, iris nodule and so on. Intermediate uveitis was defined as inflammation of the intermediate segment presenting vitreous opacity such as snowballs, snowbank and so on. Posterior uveitis was defined as inflammation of the retina and choroid presenting with periphlebitis, candle-wax drippings along the retinal veins, chorioretinal exudates, choroidal granuloma and so on. Panuveitis was defined as inflammation of all segments.

## Results

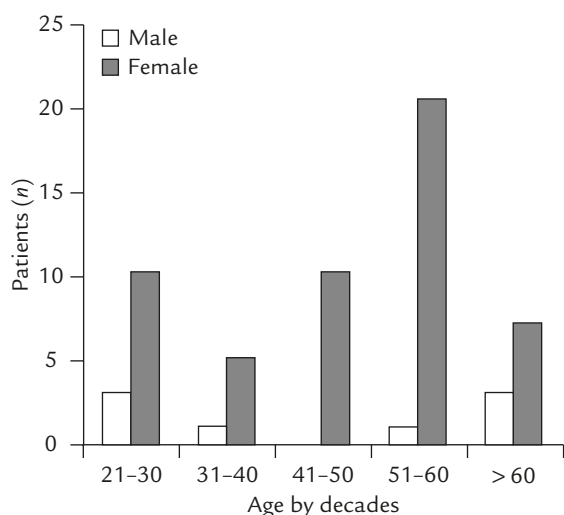
A total of 60 uveitis patients with biopsy-proven sarcoidosis were identified during the 20-year-period from 1986 to 2005. There was a marked female predominance, with a male-to-female ratio of 1:6.5 (male 8, female 52). The distribution of the patients by year is shown in Figure 1. Forty-four patients (73%) were found in the last 4 years.

Age and sex distribution of uveitis onset are shown in Figure 2. The mean age at uveitis onset was  $47.7 \pm 14.7$  years (range, 21–76 years); mean age was  $46.4 \pm 21.3$  in males and  $47.9 \pm 13.7$  in females. There was no gender difference ( $p=0.913$ ). The distribution of age at uveitis onset showed a peak incidence in the 6<sup>th</sup> decade of life (Figure 2).

The initial symptoms of these 60 patients were uveitis in 41 patients (68.3%), accidental finding by a health examination in 5 patients (8.3%), skin lesions in 4 patients (6.7%), constitutional conditions including fever, leukopenia and body weight loss in 4 patients (6.7%), neck mass lesion in 3 patients (5.0%), respiratory problems in 2 patients (3.3%), and neurologic symptom in 1 patient.



**Figure 1.** Distribution of the 60 uveitis patients with biopsy-proven sarcoidosis by year (1986–2005).



**Figure 2.** Age and sex distribution of uveitis onset among 60 patients with biopsy-proven sarcoidosis.

There were 81 positive biopsy sites, including 45 patients with 1 positive site, 9 patients with 2 positive sites, and 6 patients with 3 positive sites. The most common positive biopsy sites were mediastinal lymph nodes in 34 patients (56.7%), followed by lung in 14 patients (23.3%), conjunctiva in 13 patients (21.7%), skin in 10 patients (16.7%), extrathoracic lymph nodes in 6 patients (10.0%), liver in 1, spleen in 1, bone marrow in 1 and parotid gland in 1 patient.

Comparison of stages of CXR and CT in 44 patients who presented since 2002 is shown in Table 1. Twenty (90.9%) of 22 patients with CXR stage 0 showed  $\geq$  stage 1 on CT.

**Table 1.** Comparisons of chest condition in stages of chest X-ray (CXR) and chest computed tomography (CT) ( $n = 44$ )

CXR	CT			
	0	I	II	III
0	2	9	10	1
I	0	6	6	0
II	0	0	2	0
III	0	0	7	1

Frequency of the manifestations of uveitis showing isolated anterior uveitis occurred in 2 patients (3.3%), isolated posterior uveitis in 8 patients (13.3%), intermediate and posterior uveitis (i.e. anterior uveitis sparing) in 16 patients (26.7%) and panuveitis (granulomatous) in 34 patients (56.7%). Of the 60 patients, there was bilateral eye involvement in 54 (90%).

## Discussion

Sarcoidosis is rarely seen among Chinese. The first documented case of sarcoidosis in Chinese was reported by Tsou et al in 1958.<sup>15</sup> In the English literature, the first case report was by Hsing et al in 1964.<sup>16</sup> Up to 1981, there were only 15 published cases, including 4 reported by Nandi et al in a literature review.<sup>17</sup> Among mainland Chinese, where the total population has reached 1.3 billion, only about 300 cases have been reported up to 1982.<sup>18</sup> Even in the past 20 years, there is still a relatively small number of cases with

biopsy-proven sarcoidosis reported in Chinese.<sup>19–24</sup> Taiwan, an island with more than 23,000,000 inhabitants, is situated at the east-southern coast of mainland China. Nearly all of its inhabitants have come from mainland China.

The pattern of uveitis in a given population is strongly influenced by genetic, geographic and environmental factors. Sarcoidosis has come to be the most common type of uveitis rather than Behcet's disease and Vogt-Koyanagi-Harada's disease in Japan.<sup>25,26</sup> Our uveitis clinic, established in 1984, is the first in a Chinese area.<sup>7</sup> The incidence of uveitis with biopsy-proven sarcoidosis was about 0–2% of the total number of uveitis patients per year before 2002, and a marked increase to 4–6% was found since 2002. One of the causes of this increase is the performance of chest CT. Chest CT can be useful to discover mediastinal lymphadenopathy and other lesions suggestive of sarcoidosis, as well as to help guide tissue confirmation.<sup>27</sup> In this study, 20 (90.9%) of 22 patients with CXR stage 0 showed  $\geq$  stage 1 on CT. This means that mediastinal lymphadenopathy and other lesions suggestive of sarcoidosis cannot be revealed solely by CXR. Further examination with CT is necessary in patients with peculiar uveitis features indicative of sarcoidosis.

Generally, an accidental finding by a health examination of CXR films or mass screening CXR program is still thought to be the major way of detecting sarcoidosis. Eye manifestation, especially uveitis, as the initial symptom of sarcoidosis is increasing.<sup>28,29</sup> A survey by the Diffuse Pulmonary Disease Research Committee of Japan showed that the prevalence of cases with ocular lesions has markedly increased in recent years, while the proportion of patients with bilateral hilar lymphadenopathy or pulmonary involvement detected by CXR mass survey has decreased.<sup>30</sup>

A definite diagnosis of sarcoidosis requires demonstration of non-caseating granuloma and other granuloma-forming processes excluded on tissue biopsy. Transbronchial and mediastinal biopsy are both the most common tissue-proved sites in sarcoidosis, because the most common involved area of sarcoidosis is in the chest. The same results were found in this study. On the other hand, conjunctiva was also a common site in this study. A blind and bilateral conjunctival biopsy, due to its ease, safety and specificity, is strongly suggested. The positive rate of patients with pathologic findings suggesting sarcoidosis in conjunctival biopsy was 38–55%.<sup>12,31,32</sup>

Female predominance in uveitis with sarcoidosis is well founded.<sup>4</sup> Our data showed an absolute female predominance, with a female-to-male ratio of 6.5, which was higher than for other ethnicities.<sup>4,5,25</sup> Two peaks

of incidence reported for sarcoid uveitis were at the age of 20–30 years and 50–60 years.<sup>4</sup> In this study, the 6<sup>th</sup> decade was the most common onset age.

The frequency of anatomically classified form of uveitis with sarcoidosis is variable. Anterior uveitis is considered the most common.<sup>5</sup> In contrast, the posterior segment is the most common localization of sarcoid uveitis in white patients, specifically in elderly female patients.<sup>4,8</sup> In this study, the posterior segment was the most commonly involved area. The situation is similar to that in whites.

The spectrum of intraocular inflammation in sarcoidosis is wide.<sup>5,33,34</sup> Mutton-fat keratic precipitates/iris nodules, trabecular meshwork nodules/tent-shaped peripheral anterior synechiae, snowball vitreous opacities, nodular periphlebitis and multiple chorioretinal lesions are considered pathognomonic manifestations in uveitis with sarcoidosis in Japan.<sup>34</sup> Anterior uveitis including granulomatous and non-granulomatous inflammation is considered the most common type of uveitis in biopsy-proven sarcoidosis.<sup>5</sup> In contrast, panuveitis was the most rare type.<sup>5</sup> The situation is much different from the results in our study. Inflammation of the posterior segment is the most common localization of sarcoid uveitis in white patients, specifically in elderly female patients.<sup>4,8</sup> In this study, the posterior segment of the eye ball was also found to be the most commonly involved area. The situation in Chinese is similar to that in whites.

In summary, this study presents the largest reported group of uveitis patients with biopsy-proven sarcoidosis in the Chinese population. The marked increase in the number of patients after 2002 is mostly due to the performance of CT in the normal CXR patients. Female predominance and peak incidence of uveitis onset in the 6<sup>th</sup> decade of life were found. The posterior segment was the most commonly involved area. The situation is similar to that in whites. Our uveitis clinic is the first to be established in a Chinese area.<sup>7</sup> This information on uveitis with biopsy-proven sarcoidosis in the Chinese population is constructive.

## References

1. James DG, Hosoda Y. Epidemiology. In: James DG, ed. *Sarcoidosis and Other Granulomatous Disorders*. New York: Marcel Dekker, 1994:729–43.
2. Rybicki BA, Major M, Popovich J. Racial differences in sarcoidosis incidence: a 5-year study in a health maintenance organization. *Am J Epidemiol* 1995;145:234–41.
3. Chang JH, Wakefield D. Uveitis: a global perspective. *Ocul Immunol Inflamm* 2002;10:263–79.
4. Rothova A. Ocular involvement in sarcoidosis. *Br J Ophthalmol* 2000;84:110–6.

5. Evans M, Sharma O, Labree L, Smith RE, Rao NA. Differences in clinical finding between Caucasians and African Americans with biopsy-proven sarcoidosis. *Ophthalmology* 2007;114:325–33.
6. Yang P, Zhang Z, Zhou H, Li B, Huang X, Gao Y, Zhu L, et al. Clinical patterns and characteristics of uveitis in a tertiary center for uveitis in China. *Curr Eye Res* 2005;30:943–8.
7. Chung YM, Yeh TS, Liu JH. Endogenous uveitis in Chinese: an analysis of 240 cases in a uveitis clinic. *Jpn J Ophthalmol* 1988;32:64–9.
8. Stavrou P, Foster CS. Sarcoidosis. In: Foster CB, Vitale AT, eds. *Diagnosis and Treatment of Uveitis*. New York: WB Saunders, 2002:710–25.
9. Jab DA, Johns CJ. Ocular involvement in chronic sarcoidosis. *Am J Ophthalmol* 1986;102:297–301.
10. Dana MR, Merayo-Llodes J, Schaumberg DA, Foster CS. Prognosticators for visual outcome in sarcoid uveitis. *Ophthalmology* 1996;103:1848–53.
11. Ohara K, Okubo A, Sasaki H, Kamata K. Intraocular manifestations of systemic sarcoidosis. *Jpn J Ophthalmol* 1992;36:452–7.
12. Chung YM, Lin YC, Huang DF, Hwang DK, Ho DM. Conjunctival biopsy in sarcoidosis. *J Chin Med Assoc* 2006; 69:472–7.
13. Judson MA, Baughman RP, Teirstein AS, Terrin ML, Yeager H Jr. Defining organ involvement in sarcoidosis: the ACCESS proposed instrument. *Sarcoidosis Vasc Diffuse Lung Dis* 1999;16: 75–86.
14. Jabs DA, Nussenblatt RB, Rosenbaum JT. Standardization of uveitis nomenclature for reporting clinical data. Results of the first international workshop. *Am J Ophthalmol* 2005;140: 509–16.
15. Tsou GP, Ma YS, Shen IC. A case report of Boeck's sarcoidosis. *Chin J Pediatr* 1958;9:488–91.
16. Hsing CT, Han FC, Liu HC, Chu BY. Sarcoidosis among Chinese. *Am Rev Respir Dis* 1964;89:917–22.
17. Nandi PL, Au MC, Ong GB. Sarcoidosis among Chinese. *Chest* 1981;80:74–9.
18. Bovornkitti S. Sarcoidosis in the Chinese. *Chest* 1982;81:132.
19. Perng RP, Chen JH, Tsai TT, Hsieh WC. Sarcoidosis among Chinese in Taiwan. *J Formos Med Assoc* 1997;96:697–9.
20. Hsieh CW, Chen DY, Lan JL. Late-onset and rare far-advanced pulmonary involvement in patients with sarcoidosis in Taiwan. *J Formos Med Assoc* 2006;105:269–76.
21. Jia YM, Zheng JX, Zhang X. The diagnosis and treatment in 39 cases of sarcoidosis. *Zhonghua Zie He He Hu Xi Za Zhi* 1994;17:27–9.
22. Liu X, Zhang D, Zhang R. Clinical value of mediastinoscopy in the diagnosis of mediastinal mass: an analysis of 60 cases. *Zhonghua Zhong Liu Za Zhi* 2000;22:238–40.
23. Miao JZ, Du DJ, Zeng P. The effect of therapeutic intervention with corticosteroids on outcome and prognosis of sarcoidosis. *Chin J Tuberc Respir Dis* 2003;26:14–7.
24. Chong WS, Tan HH, Tan SH. Cutaneous sarcoidosis in Asians: a report of 25 patients from Singapore. *Clin Exp Dermatol* 2005;30:120–4.
25. Goto H, Mochizuki M, Yamaki K, Kotake S, Usui M, Ohno S. Epidemiological survey of intraocular inflammation in Japan. *Jpn J Ophthalmol* 2007;51:41–4.
26. Kotake S, Furudate N, Sasamoto Y, Yoshikawa K, Goda C, Matsuda H. Characteristics of endogenous uveitis in Hokkaido, Japan. *Graefes Arch Clin Exp Ophthalmol* 1996;234:599–603.
27. Kaiser PK, Lowder CY, Sullivan P, Sanislo SR, Kosmorsky GS, Meziane MA, Rice TW, et al. Chest computerized tomography in the evaluation of uveitis in elderly women. *Am J Ophthalmol* 2002;133:499–505.
28. Matsuo T, Fujiwara N, Nakata Y. First presenting signs or symptoms of sarcoidosis in a Japanese population. *Jpn J Ophthalmol* 2005;49:149–52.
29. Adan A, Baget M, De Llobet JM, Segura A, Marieges MT, Casaroli-Marano R. Uveitis as initial manifestation of sarcoidosis: study of 31 patients. *Med Clin (Barc)* 2004;122:748–52.
30. Kataoka M. Clinical features and diagnostic approach of sarcoidosis. *Nippon Rinsho* 2002;60:1734–40.
31. Leavitt JA, Campbell RJ. Cost-effectiveness in the diagnosis of sarcoidosis: the conjunctival biopsy. *Eye* 1998;12:959–62.
32. Nichols CW, Eagle RC Jr, Yanoff M, Menocal NG. Conjunctival biopsy as an aid in the evaluation of the patient with suspected sarcoidosis. *Ophthalmology* 1980;87:287–91.
33. Lobo A, Barton K, Minassian D, du Bois RM, Lightman S. Visual loss in sarcoid-related uveitis. *Clin Exp Ophthalmol* 2003;31:310–6.
34. Kawaguchi T, Hanada A, Horie S, Sugamoto Y, Sugita S, Mochizuki M. Evaluation of characteristic ocular signs and systemic investigations in ocular sarcoidosis patients. *Jpn J Ophthalmol* 2007;51:121–6.