

Dermatitis Herpetiformis and Vitiligo

Ozlem Karabudak^{1*}, Bilal Dogan¹, Sukru Yildirim², Yavuz Harmaneri¹, Rana Anadolu-Brasie³

Departments of¹Dermatology and²Pathology, GATA Teaching Hospital, Istanbul, and

³Department of Dermatology, Ankara University Medical School, Ankara, Turkey.

Dermatitis herpetiformis (DH) is a rare immunobullous disorder of the skin that is associated with gluten hypersensitivity. Subepidermal IgA-type antibody deposition against tissue transglutaminase leads to dense neutrophilic microabscess and eventually into vesicles in dermal papillae, which may occasionally merge into bullae. Being a subepidermal vesiculobullous disorder, DH is frequently associated with postinflammatory pigmentary changes, particularly hypopigmentation. However, the association of DH with true vitiligo is extremely rare. Here, we report a 21-year-old male with vitiligo and comorbid DH, and review the literature. This new case had severely pruritic, papular and papulovesicular lesions that were localized symmetrically and partly confined to the pre-existing vitiliginous areas. The skin biopsy specimen taken from an erythematous papule on the elbow showed characteristic findings of DH and vitiligo. Direct immunofluorescence microscopy of the perilesional skin revealed granular IgA deposition of dermal papillae. There are only 10 reports in the literature of DH and vitiligo comorbidity. [*J Chin Med Assoc* 2007;70(11):504–506]

Key Words: dermatitis herpetiformis, IgA deposition, vitiligo

Introduction

Dermatitis herpetiformis (DH) is a rare, chronic and pruritic immunobullous skin disorder with symmetrical, polymorphous, and grouped lesions on an erythematous, occasionally urticarial base.¹ DH predominantly affects the extensor surfaces of the elbows, knees, buttocks, back, and scalp. It is a part of a spectrum of gluten-sensitive disorders that include celiac disease and some forms of IgA nephropathy and gluten-sensitive ataxia.²

An association is well established between DH and other autoimmune disorders, in particular, autoimmune thyroid diseases, pernicious anemia, and type 1 diabetes mellitus.³ Furthermore, there are case reports in the literature about DH coexisting with connective tissue disorders such as lupus erythematosus, Sjögren's syndrome, and scleroderma as well as asthma, sarcoidosis, alopecia areata, and psoriasis.^{2,4,5}

Here, we present a patient with vitiligo of 5 years' duration. He subsequently developed symmetrical erythematous papular and papulovesicular lesions on the vitiliginous areas, which were consistent with DH.

Case Report

A 21-year-old male was referred to the outpatient clinic with a history of recurrent pruritic lesions of 9 months' duration, which were initially located on the elbows, periumbilical areas, and subsequently on the back and shoulders. The patient reported that milky-white areas of skin had appeared 4 years previously, and these areas had remained unchanged. He had not sought any treatment for this condition. However, lately, after the development of recurrent itchy lesions, he described a slight enlargement of the discoloration.

Dermatologic examination revealed depigmented macular areas of vitiligo, symmetrically localized on the elbows, ankles and buttocks (Figure 1). There were symmetrical and grouped papulovesicular lesions with some erosions and crusting that were partly confined to the vitiliginous areas (Figure 2). Skin punch biopsy specimen taken from the erythematous papule on the elbow region showed characteristic neutrophilic microabscesses within several concomitant dermal papillae. In association with fibrin deposition, occasional subepidermal separation of the tips of the dermal papillae from the

*Correspondence to: Dr Ozlem Karabudak, Department of Dermatology, GATA Teaching Hospital, Tibbiye Street 81327 Kadikoy, Istanbul, Turkey.

E-mail: okarabudak@yahoo.com • Received: January 19, 2007 • Accepted: October 9, 2007

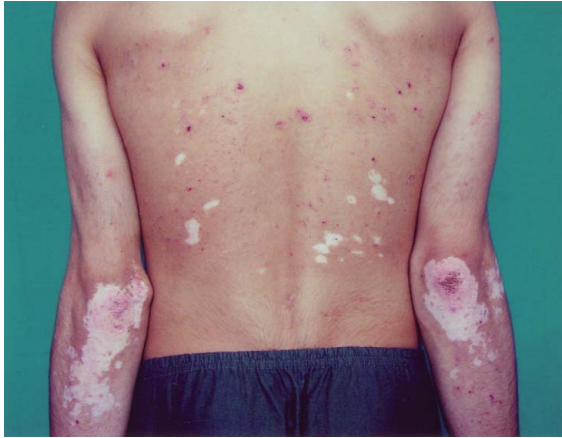

Figure 1. Papulovesicular lesions and vitiliginous plaques on the back.

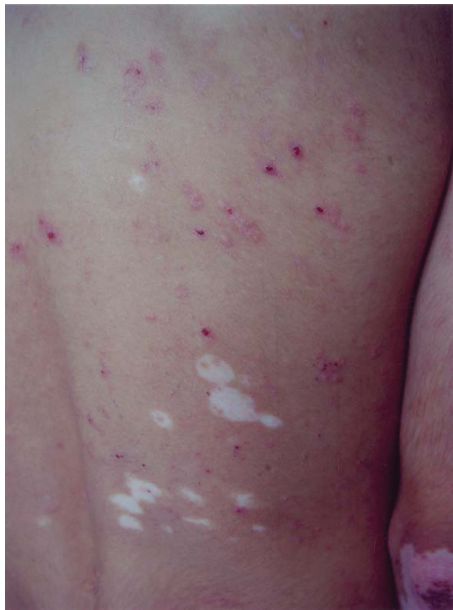

Figure 2. Close-up appearance of the lesions.

overlying epidermis was observed. There were no melanocytes in the basement layer of the epidermis (Figure 3A).

Routine blood count and chemistry tests as well as thyroid functions, namely, free T₃, free T₄, and thyroid-stimulating hormone, and immunologic parameters such as antithyroglobulin, anti-smooth muscle, antimicrosomal fraction autoantibodies, ANA, C3 and C4 were negative or within normal limits.

Direct immunofluorescence (DIF) study was performed on fresh perilesional skin biopsy frozen sections, using fluorescein-labeled anti-human IgA, IgG, IgM and C3 Abs. DIF revealed subepidermal, granular IgA deposition on the dermal papillae (Figure 3B). Therefore, the diagnosis of DH and vitiligo was made on

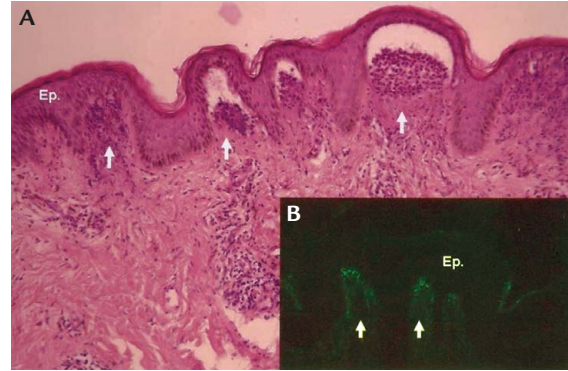


Figure 3. (A) Dermal papillary microabscesses composed of neutrophils are characteristic of dermatitis herpetiformis (original magnification, 20×). (B) Direct immunofluorescence: there is granular IgA deposition predominantly at the tips of dermal papillae (original magnification, 40×). Ep = epidermis; arrows = papillary dermis.

the basis of clinical, histopathologic and DIF findings. Endoscopic biopsy specimen taken from small intestinal mucosa showed villous atrophy. The patient was put on a strict gluten-free diet, and on topical steroid recommended for the skin lesions, and has since reported significant improvement in DH lesions. His vitiligo lesions have remained stationary, without prominent activation or regression.

Discussion

It is well known that autoimmunity in an organ increases the likelihood of other autoimmune disorder(s) in other organs. In our case, a similar mechanism seemed to be operating, by which 2 different diseases occurred in the same organ.

The comorbidity of DH and vitiligo is extremely rare. In 1964, this association was described in a 40-year-old male who developed DH lesions in depigmented macular areas of vitiligo, similar to our case.⁶ Table 1 shows the features of the previously reported patients and our patient.^{4,6-10} The onset of DH preceded vitiligo in only 2 of the patients.^{4,8} However, the order in which DH and vitiligo appeared was unclear in the rest of the cases. Our case is particularly interesting in 2 clinical aspects: first, vitiligo clearly preceded DH by 4 years; second, after the onset of DH, the vitiligo lesions became active and enlarged. In the literature review of this comorbidity, apart from DH and vitiligo, other pathologies such as leukopenia, membranous glomerulonephritis and thyroiditis have also been reported in some cases, which was not the case in our patient.^{6,9,10} Vitiligo has been interpreted as a kind of Koebner reaction which develops as a result of the inflammation yielded by DH, while other authors have suggested that these diseases

Table 1. Reported cases of dermatitis herpetiformis associated with vitiligo to date

Case	First author	Gender	Age (yr)	First pathology that appeared	Associated pathologies
1	Allende (1964) ⁶	M	40	Vitiligo	None
2	Ortonne et al ⁷ (1976)	–	–	Not reported	None
3	Olholm-Larsen & Kavli ⁸ (1980)	F	36	Dermatitis herpetiformis	None
4	Hogan & Lane ⁹ (1986)	F	46	Vitiligo	Leukopenia
5	Hazelrigg ¹⁰ (1987)	–	–	Vitiligo	Membranous glomerulonephritis
6	Reunala & Collin ⁴ (1997)	M	–	Dermatitis herpetiformis	None
7	Reunala & Collin ⁴ (1997)	M	–	Not reported	None
8	Reunala & Collin ⁴ (1997)	M	–	Not reported	None
9	Reunala & Collin ⁴ (1997)	F	–	Not reported	None
10	Amato et al ⁶ (2000)	F	–	Vitiligo	Thyroiditis
11	Present case (2007)	M	21	Vitiligo	None

have a pathogenetic correlation which can be explained by circulating immunocomplexes.^{8,10} Because vitiligo clearly preceded DH in our case, the abovementioned hypothesis of Hazelrigg is not valid.¹⁰ In the current case, DH itself or itching and scratching associated with it appears to be a Koebnerizing factor, subsequently leading to vitiligo activation.

It is well known that vitiligo is associated with a number of other autoimmune disorders, such as autoimmune thyroid disease, pernicious anemia, Addison's disease, type 1 diabetes mellitus, hypoparathyroidism, myasthenia gravis, alopecia areata, morphea, and lichen sclerosus.¹¹ A similar association also exists between DH and a number of autoimmune conditions such as insulin-dependent diabetes mellitus, thyroid disorders, Sjögren's syndrome, and systemic lupus erythematosus.²⁻⁵ Familial occurrence has been reported in 10.5% of DH cases and 30–40% of vitiligo cases, as well as simultaneous occurrence in monozygous twins.^{3,11}

Reviewing the literature on comorbidity of DH and vitiligo, the duration of the preceding dermatologic pathology (either vitiligo or DH) at the time of the diagnosis of the latter disease was not always detailed in the reports. The ages of the previously reported cases were ≥ 36 years at the time of diagnosis.⁶ Our current case is interesting as not only was the patient relatively younger than the previously reported patients, but DH developed 4 years after the onset of vitiligo as well.

Symmetrical co-involvement of 2 different skin diseases and Koebnerization of vitiligo by DH are 2 other

interesting features that still need to be further elaborated. This observation highlights the possibility of existing or future comorbidity in DH and vitiligo patients.

References

1. Odom R, James WD, Berger TG. Chronic blistering dermatosis. In: *Andrews' Diseases of the Skin: Clinical Dermatology*, 9th edition. Philadelphia: WB Saunders, 2000:599–601.
2. Nicolas ME, Krause PK, Gibson LE, Murray JA. Dermatitis herpetiformis. *Int J Dermatol* 2003;42:588–600.
3. Wojnarowski F, Venning VA, Burge SM. Immunobullous diseases. In: Burns T, Breathnach S, Cox N, Griffiths C, eds. *Rook's Textbook of Dermatology*, 7th edition. Oxford: Blackwell Publishing, 2004:54–9.
4. Reunala T, Collin P. Diseases associated with dermatitis herpetiformis. *Br J Dermatol* 1997;136:315–8.
5. Timo L, Reunala T. Dermatitis herpetiformis. *Clin Dermatol* 2001;19:728–36.
6. Amato L, Gallerani I, Fuligni A, Mei S, Fabbri P. Dermatitis herpetiformis and vitiligo: report of a case and review of the literature. *J Dermatol* 2000;27:462–6.
7. Ortonne JP, Perrot H, Thivolet J. Clinical and statistical study of 100 patients with vitiligo: II. associated lesions. *Sem Hop* 1976;52:679–86.
8. Olholm-Larsen P, Kavli G. Dermatitis herpetiformis and vitiligo. *Dermatologica* 1980;160:41–4.
9. Hogan DJ, Lane PR. Dermatitis herpetiformis and vitiligo. *Cutis* 1986;38:195–7.
10. Hazelrigg DE. Dermatitis herpetiformis and vitiligo. *Cutis* 1987;39:232.
11. Bleehen SS, Anstey AV. Disorder of skin colour. In: Burns T, Breathnach S, Cox N, Griffiths C, eds. *Rook's Textbook of Dermatology*, 7th edition. Oxford: Blackwell Publishing, 2004:3953–7.