

Prospective Comparison of Unenhanced Spiral Computed Tomography and Intravenous Urography in the Evaluation of Acute Renal Colic

Jia-Hwia Wang^{1,2}, Shu-Huei Shen^{1,2*}, Shan-Su Huang^{1,3}, Cheng-Yen Chang^{1,2}

¹Department of Radiology, Taipei Veterans General Hospital and ²National Yang-Ming University School of Medicine, Taipei, and ³Department of Radiological Technology, Yuan-Pei University of Science and Technology, Hsinchu, Taiwan, R.O.C.

Background: The purpose of this prospective study was to evaluate the feasibility of replacing intravenous urography (IVU) with unenhanced computed tomography (CT) as the first line diagnostic modality for acute renal colic in the emergency department.

Methods: In the 1-year study period, 82 patients who presented themselves to the emergency room with acute renal colic and who were suspected to have ureteral stones were included. They received both IVU and unenhanced CT on the same day.

Results: Sixty-six patients were proven to have ureteral stone. Four had other urologic pathology (acute pyelonephritis, angiomyolipoma with hemorrhage, ureteropelvic junction stenosis). The remaining 12 had no definite urologic problem. Among the 66 patients with ureteral stone, the sensitivity for detecting ureteral stone was 98.5% for unenhanced CT and 59.1% for IVU. Correct diagnosis could be obtained in most of the patients receiving unenhanced CT, while IVU could provide only limited information about the intra-abdominal pathology other than urologic system, and as many as 31.7% of the patients needed further imaging examination (sonography, CT, magnetic resonance imaging). In 5 patients, the relationship of the calcified spot and ureter were unclear on axial images. With curved multiplanar reformatted reconstruction, the diagnosis of ureter stone could be confidently made. No side effect (renal toxicity, allergic reaction) from intravenous administration of iodine-containing contrast medium should be taken into consideration in CT. Besides, the average examination time was 108 minutes for IVU, which was significantly more than the 30 minutes for CT, including the time for curved multiplanar reformatted reconstruction.

Conclusion: We consider that unenhanced CT is more effective and efficient than IVU and should replace IVU as the first-line diagnostic tool for ureteral stone in the emergency department. [*J Chin Med Assoc* 2008;71(1):30–36]

Key Words: computed tomography, intravenous urography, ureteral stone

Introduction

Renal colic is a common presentation of patients in the emergency department. They often have symptoms of acute flank pain, hematuria or even sepsis secondary to urinary tract infection. The most common cause of renal colic is ureteral stone. However, various intra-abdominal pathologies may cause the same symptom, including appendicitis, diverticulitis, ovarian torsion, ovarian cyst hemorrhage, vascular

aneurysm, pancreatitis, or intra-abdominal tumor. For detailed evaluation of these patients in the emergency department, intravenous urography (IVU) has been widely used. It can provide information about the existence, etiology, location and severity of obstruction. However, the diagnostic accuracy of IVU has been suboptimal. IVU may fail to detect stones due to radiolucent stone, small stone size, or poor opacification of the renal collecting system due to severe obstruction. According to previous studies,



ELSEVIER

*Correspondence to: Dr Shu-Huei Shen, Department of Radiology, Taipei Veterans General Hospital, 201, Section 2, Shih-Pai Road, Taipei 112, Taiwan, R.O.C.

E-mail: shshen@vghtpe.gov.tw • Received: May 9, 2007 • Accepted: October 29, 2007

the sensitivity of IVU for the diagnosis of ureter stone is only around 60%.¹⁻³ IVU also has difficulty in detecting the non-urolithic pathologies listed above.

Computed tomography (CT) is another imaging modality for the detection of ureteral stones. CT provides axial cross-section images without the problem of overlap and has better sensitivity for detecting calcification than plain radiographs. In previous reports, the sensitivity of unenhanced CT for detecting urolithiasis was greater than 95%.^{2,4} However, CT has its limitations. First, the interpretation of axial images requires experience. For those who are unfamiliar with axial imaging, it could be difficult to differentiate a ureter stone from phleboliths or calcification on vascular wall. Second, the precise location of the stone on plain radiograph was usually indeterminate by viewing axial CT scan only.⁵ With the evolution of imaging technology, multidetector row spiral CT (MDCT) has been introduced, which brought shorter scanning time and volumetric acquisition techniques. We can reconstruct the axial images into curved multiplanar reformatted (MPR) images and demonstrate the whole course of the ureter. It combines the advantages of IVU and CT—easily showing the presence of stone in the axial image, evaluating concurrent intra-abdominal pathology, and providing coronal images that are more familiar to clinical physicians.^{6,7}

The goal of this study was to prospectively compare the efficacy of unenhanced CT and IVU as the first-line imaging modality for patients with acute renal colic in the emergency department.

Methods

Patient recruitment

From August 2002 to July 2003, patients who came to the emergency department of our hospital with the presentation of renal colic and who were highly suspected to have ureteral stone were included. After getting their informed consent, they underwent unenhanced CT and curved MPR images were reconstructed immediately on the workstation. On the same day, patients also underwent conventional IVU after completion of unenhanced CT. Written informed consent was obtained from all patients before examinations. Patients who were pregnant or who had renal function impairment or previous allergic reaction to contrast medium were excluded from this study.

Imaging protocols

Unenhanced CT: In all patients, unenhanced CT was performed with a multidetector row helical scanner

(Somatom Sensation 16[®]; Siemens Co., Erlangen, Germany) from the level of the kidney to the pubis symphysis in breath-hold status, with the following parameters: beam collimation, 5 × 1.25 mm; pitch, 6; scan time, about 20 seconds. Subsequent curved MPR 3-dimensional reformation technique focusing on the ureter of the symptomatic side was made on a compatible workstation (Leonardo VB30B; Siemens Co.) by an experienced CT technologist. By manually selecting a point within the center of the ureteral lumen on sequential axial images, the renal collecting system could be demonstrated completely from the level of the renal pelvis to the urinary bladder.

IVU: A plain abdominal film was taken at the beginning of the examination. After intravenous administration of 50 mL of non-ionic contrast medium (Iopamiro[®]; Bracco S.p.A., Milan, Italy), 5 minutes anteroposterior view, 15 minutes anteroposterior and bilateral oblique views, 30 minutes anteroposterior view and post voiding view were taken. Further delayed images were taken if necessary.

Analysis

The images of unenhanced CT and IVU were reviewed separately by 2 experienced urologists who were blinded to the clinical history, final diagnosis and the results of other imaging modalities. The final diagnosis was confirmed according to the endoscopic evaluation, operative findings, pathology report and follow-up course for at least 6 months, which were compared with the 2 imaging results.

For patients who had ureteral stone confirmed by surgery, endoscopy or that spontaneously passed out, the results of CT and IVU were evaluated in the following aspects: (1) the sensitivity of stone detection; (2) the average examination time for each modality (including the time for image reformation); (3) the coexistence of other intra-abdominal pathology; and (4) the diagnostic rate of each imaging modality.

Results

A total of 82 patients (56 males, 26 females) suspected to have ureteral stone were referred from the emergency department and underwent unenhanced CT and IVU studies. The mean age of these patients was 50.7 years (range, 24–80 years); 25 (30.5%) were younger than 40 years and 45 (54.9%) younger than 50 years. Ureteral stone was confirmed in 66 (80.5%) patients, 1 of whom had coexisting transitional cell carcinoma and another had renal cell carcinoma. Among the 16 (19.5%) patients without ureteral

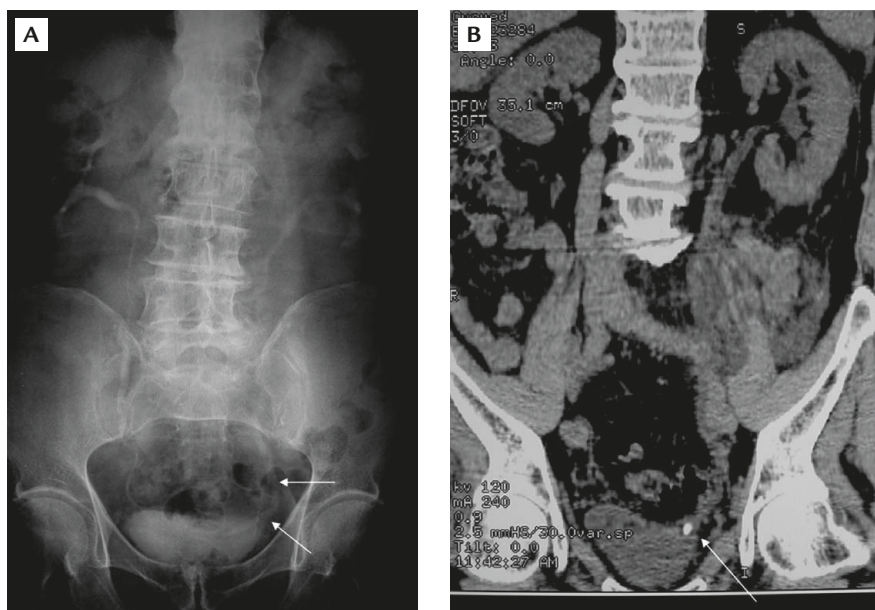


Figure 1. An 80-year-old male patient with left acute renal colic. (A) Intravenous urography shows mild dilatation of the left ureter (arrows) of unknown cause. (B) Unenhanced computed tomography with curved multiplanar reformatted reconstruction shows a small stone at the left ureterovesicle junction (arrow).

stone, 12 had no definite urologic abnormality and the other 4 were confirmed to have acute pyelonephritis ($n=1$), angiomyolipoma with hemorrhage ($n=1$), and ureteropelvic junction stenosis ($n=2$).

In 66 patients with ureteral stone, the sensitivity of IVU was 59.1% (39/66). The causes of inability to detect stone included small stone diameter (Figure 1), radiolucent stone, or severe obstruction with poor contrast excretion (Figure 2). Meanwhile, the sensitivity of unenhanced CT was 98.5% (65/66). Only in 1 patient was a lower third ureteral stone missed due to severe metal artifacts in the pelvis projecting from a hip joint arthroplasty. In 5 patients with ureteral stone (5/66, 7.6%), the ureter was not dilated and it was difficult to determine whether the calcification spot was ureter stone, calcification on vascular wall or phlebolith in gonadal vein. By curved MPR technique, the course of the ureter could be confirmed and we were able to confidently make the diagnosis of ureter stone (Figure 3).

In 1 patient who had ureteral stone combined with urothelial carcinoma in the distal ureter, IVU failed to detect the tumor because the excreted contrast was obstructed by the stone and could not reach the level of the tumor. In our study, unenhanced CT also failed to identify the tumor due to absence of soft tissue enhancement. In 1 patient, a coexisting renal cell carcinoma at the lower pole of the kidney was found, which was a Stage I lesion without involvement of the renal collecting system and was not visible on

IVU. On unenhanced CT, the tumor was invisible on axial imaging and could only be identified on the reformatted curved MPR image.

By IVU study, as many as 31.7% of the patients had inconclusive results and needed to undergo further imaging examination. In the patients with acute pyelonephritis, there were no significant findings on IVU, but the typical inflammatory changes such as unilateral renal enlargement and adjacent peri- and pararenal fat stranding were well demonstrated on CT images. In the patients who suffered from acute flank pain due to hemorrhage of angiomyolipoma rather than ureteral stone, IVU could not lead to a definite diagnosis, while CT could detect the fat content of the renal tumor (most commonly angiomyolipoma) and evaluate the amount and extent of hemorrhage (Figure 4). Among the patients with ureteral stone, 57.6% (38/66) of them were found to have coexisting intra-abdominal pathology according to CT study, including adrenal gland tumor ($n=1$), gallstones ($n=1$), lymphocele ($n=1$), renal stones ($n=25$), hydronephrosis ($n=7$), inguinal hernia ($n=1$), psoas muscle abscess ($n=1$) and abdominal aorta aneurysm ($n=1$). Statistically, the sensitivity of IVU for detecting ureteral stone was 59.1%, specificity was 100%, false-positive rate was 0%, false-negative rate was 40.9%, positive predictive value (PPV) was 100%, and negative predictive value (NPV) was 37.2%. The sensitivity of non-contrast enhanced CT was 98.5%, specificity was 100%, false-positive

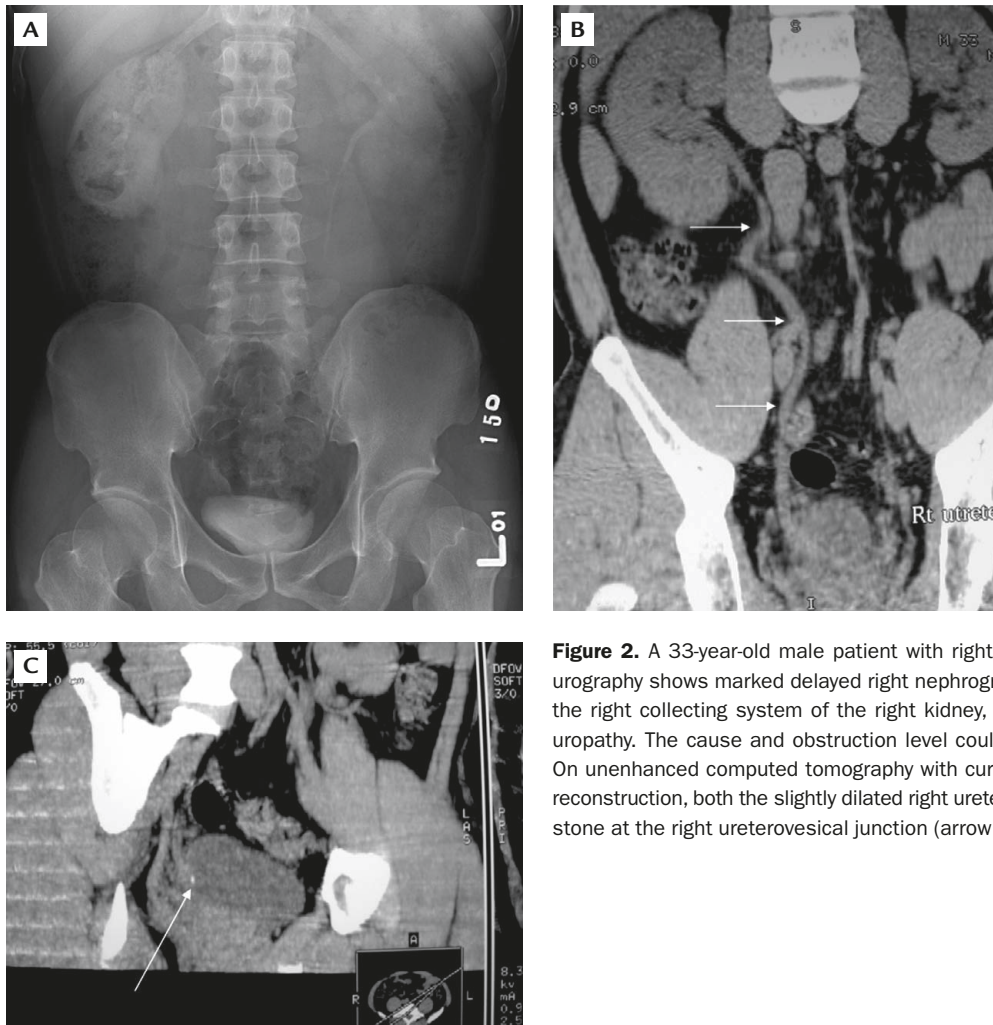


Figure 2. A 33-year-old male patient with right renal colic. (A) Intravenous urography shows marked delayed right nephrogram and non-opacification of the right collecting system of the right kidney, indicating acute obstructive uropathy. The cause and obstruction level could not be determined. (B, C) On unenhanced computed tomography with curved multiplanar reformatted reconstruction, both the slightly dilated right ureter (arrows in B) and the small stone at the right ureterovesical junction (arrow in C) were demonstrated.

rate was 0%, false-negative rate was 1.5%, PPV was 100% and NPV was 94.1% (Table 1). The average examination time for conventional IVU was 108 minutes, while unenhanced CT required 30 minutes (which included the time needed for the scan and reformatting).

Discussion

IVU has been the major imaging modality for the evaluation of the urinary system in past decades. Its protocol has been well established and clinical physicians are all familiar with its images. With intravenous contrast medium administration, IVU can demonstrate the whole urinary tract well, with great spatial resolution. However, like plain abdominal radiographs, part of the urinary tract may be overlapped and obscured by adjacent abdominal organs. Thus, tiny stones might be superimposed with bone, bowel gas,

or other intra-abdominal calcified tissue and be difficult to visualize. The sensitivity of IVU for the diagnosis of urolithiasis has been shown to be suboptimal.¹⁻³ We found in this study that the sensitivity of IVU was less than 60%. About a third of patients had inconclusive results from IVU study alone and further imaging examinations were required.

CT provides axial cross-section images without the problem of overlap and thus has better diagnostic sensitivity for ureteral stones. With the implementation of multislice helical CT, the following advantages are achieved: (1) the rapid speed allows the whole urinary tract to be imaged within a single breath hold; (2) with a few exceptions of pure matrix stone, both radiolucent and radio-opaque stones can be identified on CT;⁸ (3) the risks of contrast reaction are eliminated; (4) it has the potential to aid in the diagnosis of extra-urinary causes of acute flank pain. In our previous study in 2002, 107 patients suspected of having urinary tract lesions were evaluated with CT, which

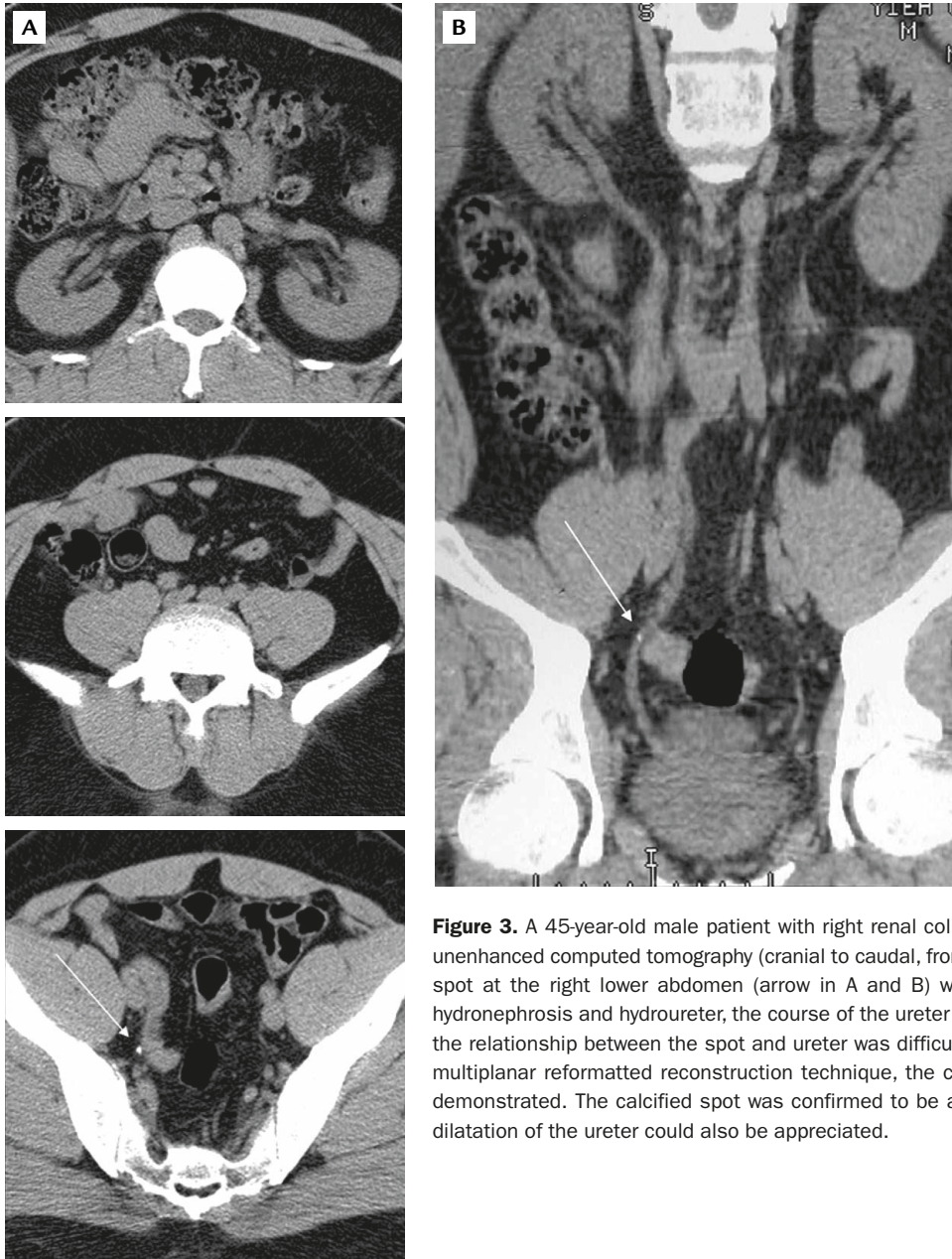


Figure 3. A 45-year-old male patient with right renal colic. (A) On serial axial images of unenhanced computed tomography (cranial to caudal, from top to bottom), a tiny calcified spot at the right lower abdomen (arrow in A and B) was identified. However, without hydronephrosis and hydroureter, the course of the ureter could not be demonstrated and the relationship between the spot and ureter was difficult to define. (B) With the curved multiplanar reformatted reconstruction technique, the course of the ureter was clearly demonstrated. The calcified spot was confirmed to be a ureter stone, and the minimal dilatation of the ureter could also be appreciated.

showed excellent accuracy for the detection of urolithiasis, neogrowth, and congenital anomalies (97.5%, 97.4% and 100%, respectively).⁹ Because CT had much better sensitivity for detecting calcification than plain radiographs,⁸ and the urine in the urinary system (especially in case of hydroureter and hydronephrosis due to obstruction) could be an ideal contrast agent for stones, we decided to prospectively evaluate the possibility of applying unenhanced CT in patients from the emergency department who were suspected to have ureteral stone. According to the results of this study, there was a great difference in the sensitivity of

detecting ureteral stones between IVU (59.1%, 39/66) and unenhanced CT (98.5%, 65/66), while there was no significant difference with regard to specificity. In this study, we also found that about a third of patients had inconclusive results from IVU study alone and required further imaging examinations. In unenhanced CT study, more than half of the patients (57.6%) were found to have coexisting intra-abdominal lesions, including neogrowth and inflammatory process, all of which cannot be detected by IVU. In addition, there was significant difference in the examination time between IVU (mean, 108 minutes) and CT (mean,

30 minutes, including reformatting process). Taking all these advantages into consideration, unenhanced CT is indeed a more cost-effective examination compared to IVU in the diagnosis of ureteral stones.

With the volumetric manner of data acquisition by multislice spiral CT, advanced 3-dimensional reconstruction techniques, such as the curved MPR technique we applied in this study, provide images that are more comprehensive for clinicians. They also offer useful information for the diagnosis of ureter stones. When the ureter was not dilated and it was difficult to determine whether the calcification spot was ureter stone, calcification on vascular wall or phlebolith in gonadal vein, the course of the ureter could be demonstrated by curved the MPR technique and thus the relationship between the calcified spot and ureter could be clarified, as demonstrated in Figure 3. In addition, curved MPR images may provide additional information for unexpected intra-abdominal pathology. In 1 case with ureteral stone, unenhanced CT

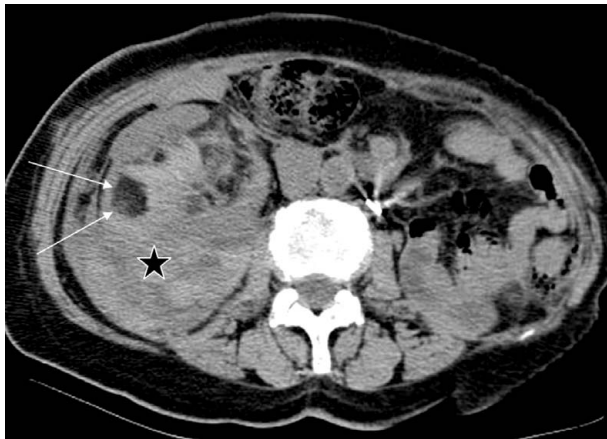

Figure 4. A 65-year-old male patient with acute right renal colic. Unenhanced computed tomography shows a fat-containing tumor in the right kidney with intra- and extrarenal hemorrhage (star). Note the area of fat density within the tumor (arrows), indicating its nature as an angiomyolipoma.

incidentally revealed a renal cell carcinoma arising from the lower pole of the kidney, which was not easily visible in the axial images and could only be identified in the curved MPR images.

Radiation dose is the issue that needs to be discussed when considering replacing IVU with unenhanced CT. In our study, about 1 third of patients were younger than 40 years and half were younger than 50 years. According to previous literature, the risk of developing malignancy after radiation exposure is much higher in individuals younger than 40 years than those older. According to the European Commission Radiation Protection Report 118, the effective dose of IVU is 2.5 mSv and that of CT is 10 mSv. However, more films are usually taken to complete the IVU examination in cases with obstructive uropathy. By modifying some scanning parameters of CT (such as lower Kv or higher pitch ratio), the radiation dose may be reduced to a reasonable level without compromising the diagnostic rate and the difference between the 2 imaging modalities might not be significant.^{10,11}

According to this study, unenhanced CT could efficiently provide necessary information about patients who present with acute renal colic in the emergency department. The diagnostic rate of CT for ureteral stone is significantly higher than that with IVU, and CT also avoids the nephrotoxicity and adverse reaction caused by contrast agents. Therefore, we suggest that unenhanced CT could be used to replace conventional IVU as the first-line imaging modality for detecting ureteral stones in the emergency department.

Acknowledgments

This study was supported in part by a research grant (NSC 91-2314-B-075-125) from the National Science Council of Taiwan.

Table 1. Comparison of the results of intravenous urography (IVU), computed tomography (CT) and final diagnosis

	IVU		CT		Total
	Positive	Negative	Positive	Negative	
Final diagnosis					
Positive	39	27	65	1	66
Negative	0	16	0	16	16
Total	39	43	65	17	82

Positive = positive for ureteral stone; Negative = negative for ureteral stone.

References

1. Handrigan MT, Thompson I, Foster M. Diagnostic procedures for the urogenital system. *Emerg Med Clin North Am* 2001;19:745–61.
2. Miller OF, Rineer SK, Reichard SR, Buckley RG, Donovan MS, Graham IR, Goff WB, et al. Prospective comparison of unenhanced spiral computed tomography and intravenous urogram in the evaluation of acute flank pain. *Urology* 1998;52:982–7.
3. Heneghan JP, Kim DH, Leder RA, DeLong D, Nelson RC. Compression CT urography: a comparison with IVU in the opacification of the collecting system and ureters. *J Comput Assist Tomogr* 2001;25:343–7.
4. Niall O, Russell J, MacGregor R, Duncan H, Mullins J. A comparison of noncontrast computerized tomography with excretory urography in the assessment of acute flank pain. *J Urol* 1999;161:534–7.
5. Van Beers BE, Dechambre S, Hulcelle P, Materne R, Jamart J. Value of multislice helical CT scans and maximum-intensity-projection images to improve detection of ureteral stones at abdominal radiography. *AJR Am J Roentgenol* 2001;177:1117–21.
6. McNicholas MM, Raptopoulos VD, Schwartz RK, Sheiman RG, Zormpala A, Prassopoulos PK, Ernst RD, et al. Excretory phase CT urography for opacification of the urinary collecting system. *AJR Am J Roentgenol* 1998;170:1261–7.
7. Perlman ES, Rosenfield AT, Wexler JS, Glickman MG. CT urography in the evaluation of urinary tract disease. *J Comput Assist Tomogr* 1996;20:620–6.
8. Mostafavi MR, Ernst RD, Saltzman B. Accurate determination of chemical composition of urinary calculi by spiral computerized tomography. *J Urol* 1998;159:673–5.
9. Lin WC, Wang JH, Wei CJ, Chang CY. Assessment of CT urography in the diagnosis of urinary tract abnormalities. *J Chin Med Assoc* 2004;67:73–8.
10. Lang EK, Macchia RJ, Thomas R, Watson RA, Marberger M, Lechner G, Gayle B, et al. Improved detection of renal pathologic features on multiphasic helical CT compared with IVU in patients presenting with microscopic hematuria. *Urology* 2003;61:528–32.
11. Etemad A, Brems-Dalgaard E, Thomsen HS. Outcome of intravenous urography in the year 2000. *Abdom Imaging* 2003;28:226–9.