

Comparison of Multiple Reduced-dose and Standard Light Application in Photodynamic Therapy in an Animal Model of Choroidal Neovascularization

Shwu-Jiuan Sheu^{1,2*}, Youn-Shen Bee², Hsiu-Chen Lin², Wan-Ling Ho², Tsung-Tien Wu^{1,2}
¹Department of Ophthalmology, National Yang-Ming University School of Medicine, Taipei, and
²Department of Ophthalmology, Kaohsiung Veterans General Hospital,
 Kaohsiung, Taiwan, R.O.C.

Background: Current photodynamic therapy (PDT) for choroidal neovascularization (CNV) uses a standard radiant exposure of 50 J/cm² at an irradiance of 600 mW/cm². However, low-intensity PDT with verteporfin for neovascular tissue has been shown to be more effective than regular high-intensity PDT in an animal model of healthy choroids and corneal neovascularization. Low-intensity PDT also supposedly induces less retinal damage. In this study, we compared the effect of reduced-dose and standard light application PDT in an animal model of CNV.

Methods: A laser injury model was used to induce CNV 3 weeks prior to PDT in brown Norway rats. The CNV lesions were then treated with verteporfin PDT with a dose of verteporfin 6.0 mg/m² and 5 activating doses of light energy (43, 53, 63, 73 and 83 seconds). Closure of CNV was assessed by fundus fluorescein angiography (FAG). Histopathologic study was done after the last FAG.

Results: PDT with verteporfin significantly reduced the CNV area compared with control non-treated groups 1 week after PDT ($p < 0.05$). Only those lesions treated for 63 seconds or longer retained their significantly attenuating effect on CNV up to 3 weeks after PDT. There was no significant difference between the inhibition effects induced by reduced-intensity light application for 63 or 73 seconds compared to the standard radiant exposure (83 seconds). Histopathologic study showed that eyes treated with PDT showed significantly less extent and vascularity of CNV lesion than control lesions.

Conclusion: Reduced-intensity PDT with 63-second duration seemed to be as effective as standard dose for CNV suppression. Considering the possible retinal damage following standard PDT, the PDT dose might be adjusted to reduce side effects. Further preclinical study will provide more data on what constitutes appropriate dosimetry for effective and safe PDT in CNV. [*J Chin Med Assoc* 2008;71(3):135–142]

Key Words: age-related macular degeneration, choroidal neovascularization, dose, photodynamic therapy

Introduction

Age-related macular degeneration (AMD) is one of the primary causes of adult visual impairment and blindness in developed countries. Most visual loss occurs in exudative AMD. Vision loss in patients with the exudative form of AMD (wet AMD) is caused by the formation of choroidal neovascularization during the late stage of the disease. Various modalities of treatment have

been tried in the treatment of CNV, including laser photocoagulation, transpupillary thermotherapy (TTT), radiation therapy, surgical removal, interferon, retinal pigment epithelial (RPE) cell or photoreceptor transplantation, and photodynamic therapy (PDT).^{1,2} Currently, use of antiangiogenic agents, such as bevacizumab (Avastin), pegaptanib (Macugen) and ranibizumab (Lucentis), has gained much attention as it addresses underlying angiogenic stimuli for blood vessel



*Correspondence to: Dr Shwu-Jiuan Sheu, Department of Ophthalmology, Kaohsiung Veterans General Hospital, 386, Ta-Chung 1st Road, Kaohsiung 813, Taiwan, R.O.C.
 E-mail: sjsheu@vghks.gov.tw • Received: May 4, 2007 • Accepted: February 13, 2008

growth.³⁻⁵ Treatments for CNV due to AMD can be directed at either the vascular component of CNV (the new vessels that proliferate and leak blood and fluid) or the angiogenic component that leads to the development of the condition.⁶⁻¹¹ Verteporfin targets the vascular component, whereas antiangiogenic agents (such as pegaptanib and ranibizumab) target key mediators of the angiogenic cascade. The different mechanisms of action of these approaches offer the potential for additive or synergistic effects with combination therapy.

Visudyne is claimed to accumulate in neovascular tissue and thus be more selective in terms of “bystander damage on RPE and photoreceptors”. However, we saw severe RPE damage after uneventful PDT in some cases. Occlusion of normal choriocapillaries after PDT treatment, potential for cumulative damage to retinal structures, and severe pigment epithelial alteration in the treatment area following PDT have been reported.^{12,13} Reduced frequency has been tried. The 2-year results in minimally classic CNV demonstrated no inferior, or even better, effect compared to standard dose PDT treatment.¹⁴ Histologic study in animal model also supports the use of reduced light application. Framme et al’s report showed more selective vessel occlusion without RPE and photoreceptor damage for 100 mW/cm² rather than 600 mW/cm² intensity at threshold irradiation on healthy choroids and experimental induced corneal neovascularization.¹⁵ In this study, we tried to compare the effect of reduced-dose and standard light application PDT in an animal model of CNV.

Methods

Animals

Brown Norway pigmented rats (weighing 200–250 g; National Animal Center, Taipei, Taiwan) were used. The animals were handled in accordance with the ARVO Statement for the Use of Animals in Ophthalmic and Vision Research. Rats were anesthetized with intramuscular injection of 0.15 mL/kg of an equal-volume mixture of 2% lidocaine (Xylocaine; Astra, Astra Södertälje, Sweden) and 50 mg/mL ketamine (Ketalar; Parke-Davis, Morris Plains, NJ, USA).

Laser-induced CNV

Rats were anesthetized and pupils dilated with 1% tropicamide (1% Mydracil; Alcon Laboratories, Fort Worth, TX, USA). A piece of cover glass was used as a contact lens. Argon laser (Novus Omni; Coherent Medical Laser, Palo Alto, CA, USA) irradiation was delivered through a slit lamp (Carl Zeiss, Oberkochen, Germany). The laser parameters used were as follows: spot size of

50 μ m, power of 400 mW, and exposure duration of 0.05 seconds. An attempt was made to break Bruch’s membrane, as clinically evidenced by central bubble formation, with or without intraretinal or choroidal hemorrhage. Three lesions were created between the major retinal vessels in each fundus.

Fundus fluorescein angiography

At different time intervals after laser photocoagulation, the CNV lesions were studied by fundus fluorescein angiography (FAG) using digital fundus camera Visupac 450, Zeiss FF450 (Carl Zeiss). Fluorescein sodium, 10%, 0.1 mL/kg (Fluorescite; Alcon Laboratories), was injected intravenously into the anesthetized rats. Late-phase angiograms were obtained 8 minutes after injection, and digital fundus pictures of bilateral eyes were taken within 1 minute. The mean CNV area was derived from measurement of all the CNV lesions by an ophthalmologist who was masked to the treatment of the eyes. In each eye, the areas of CNV on FAG were measured with image analysis software. The areas were outlined with the computer mouse, using the option provided by the software, and the results were expressed in millimeters squared. The software was developed for the estimation of lesion sizes in human eyes. Although the estimated lesion sizes in the rat eye were not the actual sizes, the estimated sizes were proportional to the actual sizes, and thus good for comparing the lesion size in different groups.

PDT

Three weeks after laser induction of choroidal neovascularization, PDT was performed on experimental CNV as follows: photosensitizer (verteporfin, Visudyne; Novartis Pharma AG, Basel, Switzerland) doses were given via tail-vein injection at a dose of 12 mg/m². Conversion to body surface area (in meters squared) from weight (in kilograms) was made using a nomogram developed by Gilpin.¹⁶ Laser light of 689 nm was administered using a diode laser (Coherent Medical Laser) delivered via slit adapter (LaserLink; Coherent Medical Laser). Laser power at the focal plane was measured with a power meter (Coherent Fieldmaster, Coherent, Auburn, CA, USA). The laser spot size was set at 1,000 μ m, and the irradiance used was 600 mW/cm², which was delivered for 43, 53, 63, 73 or 83 (standard dose) seconds ($n=14$ in each group).

Histopathologic study

The rats were sacrificed after the last FAG (42 days after laser treatment) and subjected to histologic examination. The eyes were enucleated, and immediately placed in 2.5% glutaraldehyde and 2% formaldehyde in 0.1 M

phosphate-buffered saline, pH 7.4, for 15 minutes. Each specimen was embedded in paraffin. Sections of 2–3 μm were made and stained with hematoxylin and eosin (H&E) for light microscopy.

Statistical analysis

All data are mean \pm SEM from at least 3 experiments with 3–6 determinations. Statistical analysis was performed with SPSS version 12.0 (SPSS Inc., Chicago, IL, USA). For multiple comparisons, 1-way analysis of variance was used, with subsequent *post hoc* analysis by Duncan test.

Results

Attenuation of CNV lesion by PDT of different durations

The therapeutic potential of verteporfin PDT for CNV was investigated with laser photocoagulation-induced CNV model in Brown Norway rats, as shown in the experimental scheme (Figure 1). The 14 rats received 3 laser spots in each eye separately. All laser-induced breaks in Bruch's membrane resulted in CNV. Three weeks later, PDT was done in the 14 rats. To test the potential of verteporfin for CNV attenuation, we performed PDT for different durations in each laser-induced CNV: 83 seconds, 73 seconds, 63 seconds in the right eye, and 53 seconds, 43 seconds, 0 seconds in the left eye. The CNV incidences and area were evaluated by FAG analysis at weeks 1, 2, 3 and 4 after PDT treatment (Figure 2).

Rats receiving PDT exhibited significantly reduced CNV area compared to CNV without PDT at weeks 1, 2 and 3 after PDT treatment. At week 1 after PDT, FAG examination revealed that the CNV area was significantly lower in the eyes of PDT-treated lesions compared with control lesions ($1.53 \pm 0.12 \text{ mm}^2$ in 0-second treated lesions *vs.* $0.34 \pm 0.16 \text{ mm}^2$ in 83-second treated lesions, $p < 0.001$; $0.57 \pm 0.19 \text{ mm}^2$ in 73-second treated lesions, $p = 0.003$; $0.60 \pm 0.22 \text{ mm}^2$ in 63-second treated lesions, $p = 0.004$; $0.81 \pm 0.19 \text{ mm}^2$ in 53-second treated lesions, $p = 0.034$; and $0.77 \pm 0.23 \text{ mm}^2$ in 43-second treated lesions, $p = 0.022$) (Figure 3A). At week 2 after PDT, FAG examination revealed that CNV area was significantly lower in the eyes of PDT-treated lesions compared with control lesions, except in the 53-second group ($1.83 \pm 0.11 \text{ mm}^2$ in 0-second treated lesions *vs.* $0.81 \pm 0.20 \text{ mm}^2$ in 83-second treated lesions, $p < 0.001$; $0.85 \pm 0.20 \text{ mm}^2$ in 73-second treated lesions, $p < 0.001$; $0.81 \pm 0.18 \text{ mm}^2$ in 63-second treated lesions, $p < 0.001$; $1.28 \pm 0.14 \text{ mm}^2$ in 53-second treated lesions, $p = 0.092$; and

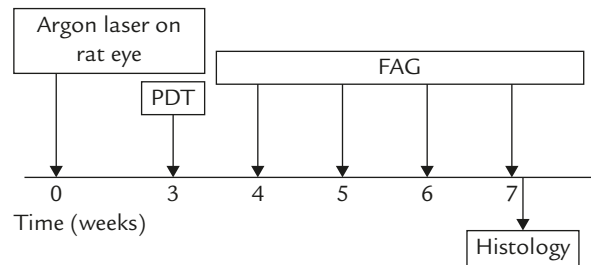


Figure 1. Treatment scheme of photodynamic therapy (PDT) for choroidal neovascularization (CNV) in rats. CNV was induced by laser photocoagulation on day 0. PDT was performed in week 3. Fundus fluorescein angiography (FAG) examinations were performed at weeks 4, 5, 6 and 7 after laser photocoagulation. After the last FAG, rats were sacrificed for histopathologic study.

$1.145 \pm 0.17 \text{ mm}^2$ in 43-second treated lesions, $p = 0.022$) (Figure 3B).

At week 3 after PDT, FAG examination revealed that CNV area was significantly lower in the eyes of PDT-treated lesions, with durations of 63, 73 and 83 seconds, compared with control lesions ($1.81 \pm 0.17 \text{ mm}^2$ in 0-second treated lesions *vs.* $1.04 \pm 0.18 \text{ mm}^2$ in 83-second treated lesions, $p = 0.049$; $1.02 \pm 0.26 \text{ mm}^2$ in 73-second treated lesions, $p = 0.043$; $0.93 \pm 0.24 \text{ mm}^2$ in 63-second treated lesions, $p = 0.019$; $1.42 \pm 0.20 \text{ mm}^2$ in 53-second treated lesions, $p = 0.564$; and $1.11 \pm 0.20 \text{ mm}^2$ in 43-second treated lesions, $p = 0.086$) (Figure 3C). At week 4 after PDT, FAG examination revealed that CNV area was lower in the eyes of PDT-treated lesions, but without significant difference compared with that in control lesions ($1.28 \pm 0.23 \text{ mm}^2$ in 83-second treated lesions, $1.29 \pm 0.22 \text{ mm}^2$ in 73-second treated lesions, $1.23 \pm 0.24 \text{ mm}^2$ in 63-second treated lesions, $1.33 \pm 0.21 \text{ mm}^2$ in 53-second treated lesions, and $1.27 \pm 0.22 \text{ mm}^2$ in 43-second treated lesions *vs.* $1.91 \pm 0.10 \text{ mm}^2$ in 0-second treated lesions) (Figure 3D).

These results indicated that PDT with 83-, 73-, 63-, 53- and 43-second laser exposure prominently attenuated CNV area in rats 1 week after laser photocoagulation. Although only those treated with 63 seconds or longer retained their significant attenuating effect on CNV up to 3 weeks after PDT, the CNV areas were smaller in the treated groups. The effect of reduced light groups with 63, 73 or 83 seconds did not show any significant differences (p value for 63 seconds *vs.* 73 seconds/73 seconds *vs.* 83 seconds/63 seconds *vs.* 83 seconds: 1st week—1.0/0.981/0.967, 2nd week—1.0/1.0/1.0, 3rd week—1.0/1.0/1.0, 4th week—1.0/1.0/1.0). Reduced-dose PDT, as low as 63 seconds, could effectively attenuate CNV in this experimental animal model (Figure 4).

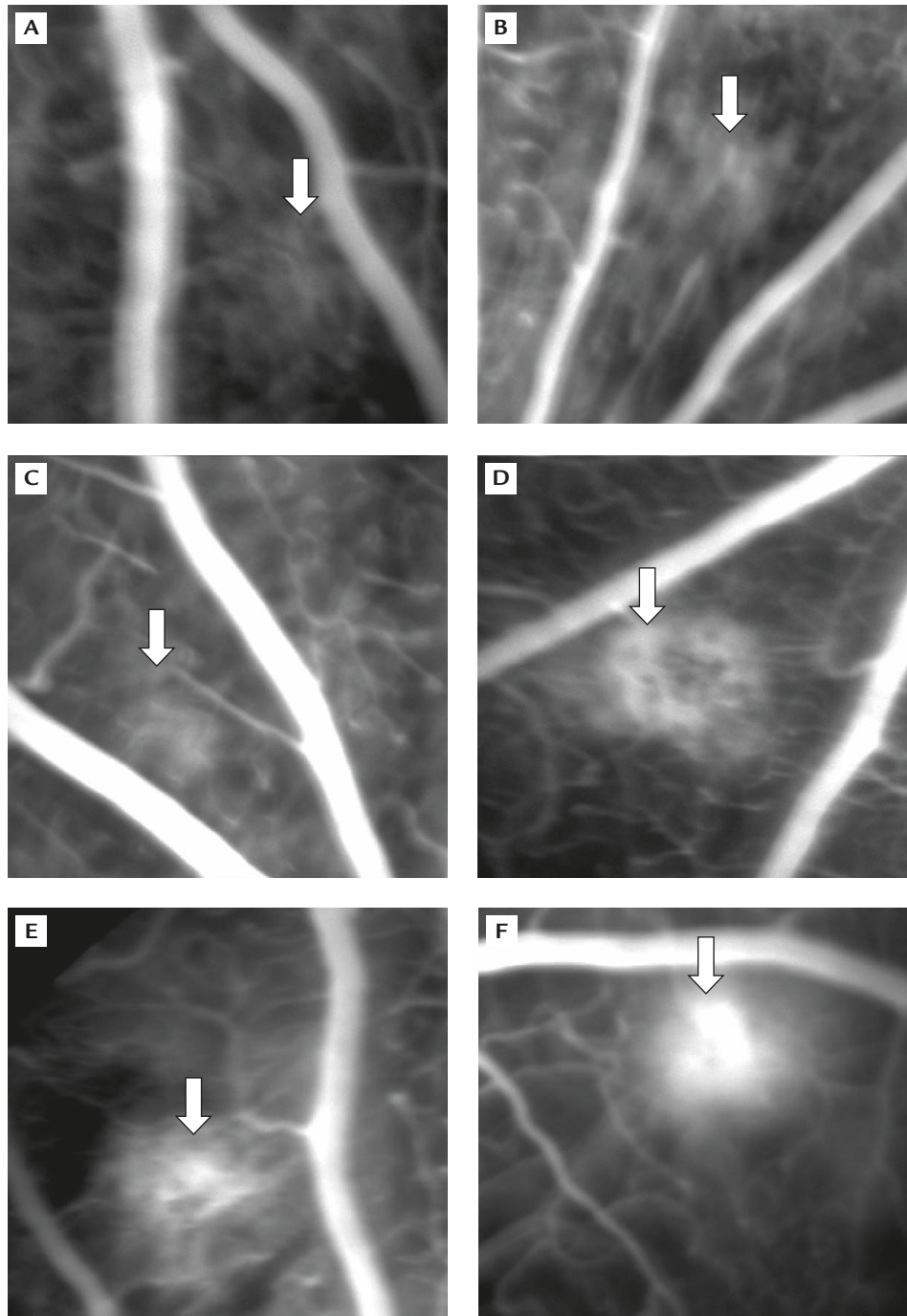


Figure 2. Attenuation of laser photocoagulation-induced choroidal neovascularization (CNV) 2 weeks after photodynamic therapy (PDT). Fundus fluorescein angiography (FAG) showed that CNV area was significantly smaller for PDT-treated lesions compared with control lesions, except in the 53-second group. CNV after: (A) 83-second PDT; (B) 73-second PDT; (C) 63-second PDT; (D) 53-second PDT; (E) 43-second PDT; (F) 0-second PDT.

PDT attenuated CNV lesions in histologic analysis

After the last FAG (7 weeks after laser photocoagulation), the rats were sacrificed and eyes were enucleated for H&E analysis. The eyes treated by PDT showed

significantly less extent and vascularity of CNV lesions than control lesions. Figure 5 shows a light microscopic picture of CNV stained with H&E after PDT in different groups. There were no adverse ocular changes throughout the experiment.

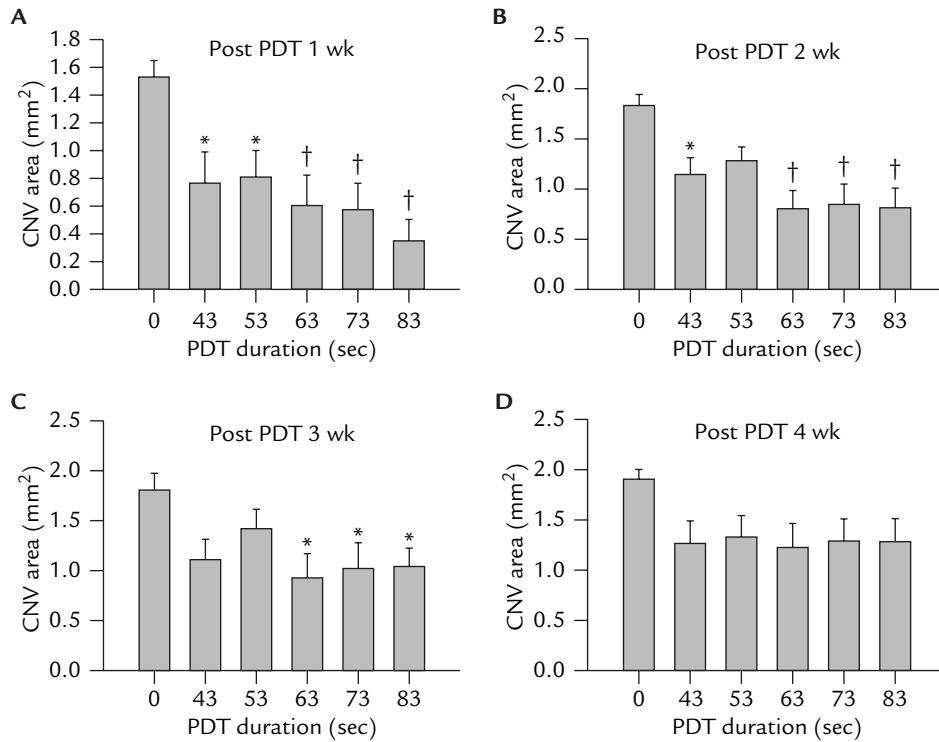


Figure 3. (A) Effect of choroidal neovascularization (CNV) attenuation 1 week after photodynamic therapy (PDT) in rats. Fundus fluorescein angiography (FAG) examinations were performed 1 week after PDT. CNV lesion areas were prominently reduced in eyes that received PDT compared with untreated lesions. (B) Effect of CNV attenuation 2 weeks after PDT in rats. FAG examinations were performed 2 weeks after PDT. CNV lesion areas were prominently reduced in eyes that received PDT compared with untreated lesions, except in the 53-second group. (C) Effect of CNV attenuation 3 weeks after PDT in rats. FAG examinations were performed 3 weeks after PDT. CNV lesion areas were prominently reduced in eyes that received PDT of 63-, 73- or 83-second duration, compared with untreated lesions. (D) Effect of CNV attenuation 4 weeks after PDT in rats. FAG examinations were performed 4 weeks after PDT. CNV lesion areas were smaller in eyes that received PDT, but not significantly, compared with untreated lesions. * $p < 0.05$; † $p < 0.01$.

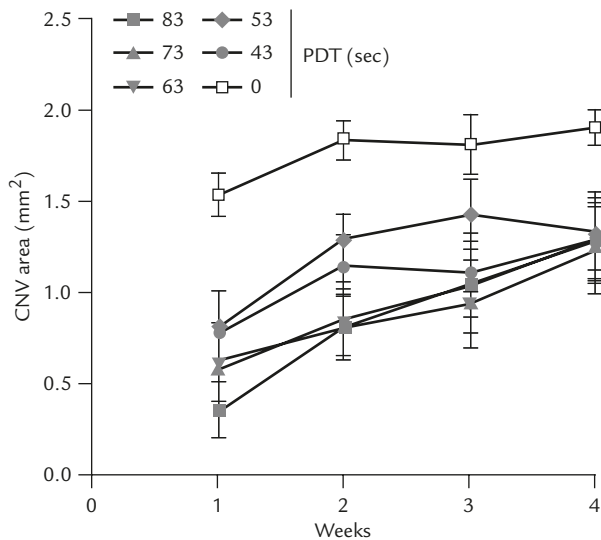


Figure 4. Effect of choroidal neovascularization (CNV) attenuation after different time courses of photodynamic therapy (PDT) in rats. Fundus fluorescein angiography (FAG) examinations were performed 1, 2, 3 and 4 weeks after PDT. CNV lesion areas were prominently reduced in eyes that received PDT compared with untreated lesions.

Discussion

Our results demonstrated that PDT could effectively attenuate CNV in an experimental animal model, and reduced doses, as low as 63 seconds, worked just as well as the standard dose. The standard radiant exposure for current PDT in AMD treatment is 50 J/cm² at an irradiance of 600 mW/cm², using verteporfin 2 mg/kg. The parameter for standard PDT is 83-second treatment with an irradiance of 600 mW/cm². The effect of PDT involves complex interactions among the photosensitizer, light, oxygen and various biological targets within the tissue, which might change during irradiation.¹⁷⁻¹⁹ Cytotoxicity in PDT mainly results from the production of highly reactive singlet oxygen (¹O₂), which is generated through the reaction of the excited photosensitizer with endogenous ground-state tissue oxygen (³O₂). With the relatively high irradiance used in AMD treatment, acute tissue hypoxia may deplete ³O₂, and thus limit further ¹O₂ generation and PDT effect.²⁰ With this consideration and the

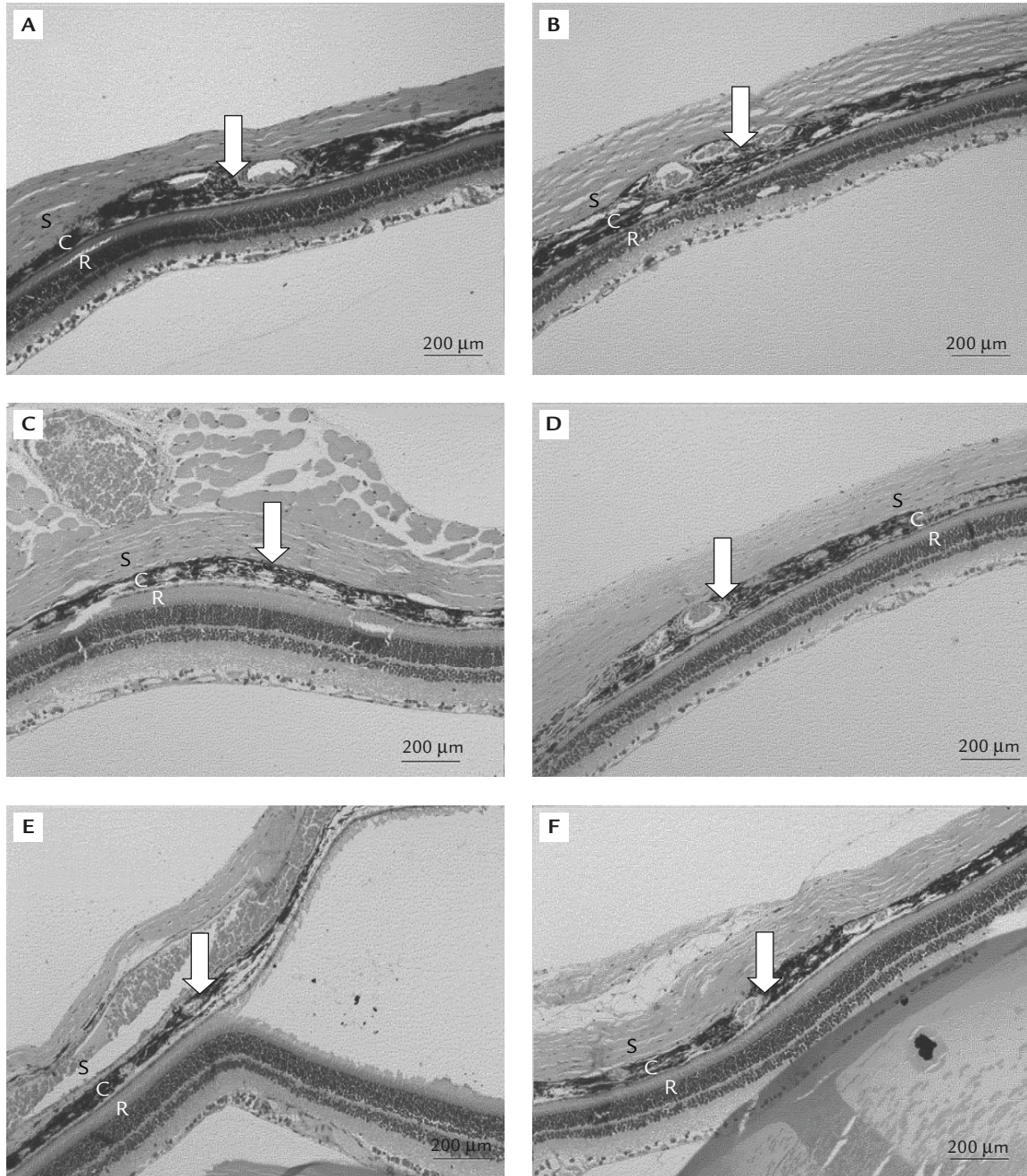


Figure 5. Histology of photodynamic therapy (PDT)-treated retina and choroid tissue. After the last fundus fluorescein angiography (7 weeks after laser photocoagulation), animals were killed and eyes enucleated. Histology of the choroidal neovascularization (CNV) lesion after: (A) 0-second exposure; (B) 43-second exposure; (C) 53-second exposure; (D) 63-second exposure; (E) 73-second exposure; (F) 83-second exposure. Arrows indicate the laser-induced CNV lesions. The eyes treated with PDT showed less extent and vascularity than control lesions. S = sclera; C = choroid; R = retina.

several reported cases of RPE damage after uneventful PDT, it became an important issue that PDT treatment for AMD would be more effective and selective in terms of sparing photoreceptors using lower laser intensity. Framme et al's study on healthy choroids and experimentally-induced corneal neovascularization showed more selective vessel occlusion without RPE

and photoreceptor damage for 100 mW/cm^2 rather than 600 mW/cm^2 intensity at threshold irradiation.¹⁵ The 2-year results in minimally classic CNV also demonstrated no inferior, or even better, effect compared to standard dose PDT.¹⁴

We tested the effect of reduced-dose PDT at different gradients, 83 (standard dose), 73, 63, 53 and

43 seconds. Our results showed that all doses initially attenuated the experimental CNV to some extent as compared with the standard dose. Although only those treated with 63, 73 or 83 seconds retained their significant attenuating effect on CNV up to 3 weeks after PDT, the CNV areas were smaller in all treated groups; there were no significant differences between the 63-, 73- or 83-second groups. Our results support the possible benefit of reduced-dose PDT in the treatment of CNV. The discrepancy from the previous report, which showed that half dose was as effective as standard dose, might be due to the difference in animal species or different model used.¹⁵ Since PDT cannot induce permanent occlusion of CNV, PDT guidelines suggest repeated treatment every season.²¹ Recent reports revealed that the effectiveness of PDT, however, seems to be jeopardized by a rebound effect initiated by an enhanced vascular endothelial growth factor (VEGF) and reduced pigment epithelium derived factor expression in CNV.^{22,23} The surge of VEGF was speculated to cause the recurrence or recanalization of CNV after PDT. Our results showed gradual increase in CNV size 2 weeks post PDT, which was compatible with clinical observation. Verteporfin targets the vascular component, whereas antiangiogenic agents (such as pegaptanib and ranibizumab) target key mediators of the angiogenic cascade. The different mechanisms of action of these approaches offer the potential for additive or synergistic effects with combination therapy. Our results offer the choice for optimal combined therapy with reduced PDT and antiangiogenic agents.

We tested the effect on an established CNV model that is closer to the real situation in our clinical practice. The results showed that reduced light, as low as 63 seconds, could be as effective as the standard regimen. Our results were compatible to the clinical reports of PDT on minimally classic subfoveal CNV.¹³ Since our previous study of a CNV model had shown that the rat model of CNV could not last longer than 3 months, which is different from human AMD,²⁴ we could not test the effect of retreatment with low-dose PDT. Besides, standard PDT guidelines suggest the laser treatment parameter to be determined as greatest linear diameter plus 1,000 microns. This takes into account the hand tremor of the surgeon and the body tremor of patients. With the possible reduced light application, we could also decrease the treatment diameter of PDT, and further reduce treatment-related retina damage. In the era of combined treatment, reduced-light PDT will give us more benefit and less damage. Further preclinical and clinical studies will answer the question of selectivity in low-dose PDT and determine the most suitable treatment parameters.

Acknowledgments

This work was supported in part by grants from the National Science Council (NSC 95-2314-B-075B-005) and Kaohsiung Veterans General Hospital (VGHKS 96-076), Taiwan, R.O.C.

References

1. Chakravarthy U, Soubrane G, Bandello F, Chong V, Creuzot-Garcher C, Dimitrakos SA, Korobelnik JF, et al. Evolving European guidance on the medical management of neovascular age related macular degeneration. *Br J Ophthalmol* 2006;90:1188-96.
2. Shyong MP, Lee FL, Chen SJ, Tung TH, Tsai DC, Hsu WM. Photodynamic therapy for subfoveal choroidal neovascularization secondary to age-related macular degeneration. *J Chin Med Assoc* 2005;68:419-24.
3. Avery RL, Pieramici DJ, Rabena MD, Castellarin AA, Nasir MA, Giust MJ. Intravitreal bevacizumab (Avastin) for neovascular age-related macular degeneration. *Ophthalmology* 2006;113:363-72.
4. Rosenfeld PJ, Schwartz SD, Blumenkranz MS, Miller JW, Haller JA, Reimann JD, Greene WL, et al. Maximum tolerated dose of a humanized anti-vascular endothelial growth factor antibody fragment for treating neovascular age-related macular degeneration. *Ophthalmology* 2005;112:1048-53.
5. Rich RM, Rosenfeld PJ, Puliafito CA, Dubovy SR, Davis JL, Flynn HW, Gonzalez S. Short-term safety and efficacy of intravitreal bevacizumab (Avastin) for neovascular age-related macular degeneration. *Retina* 2006;26:495-511.
6. Aiello LP, Pierce EA, Foley ED, Takagi H, Chen H, Riddle L, Ferrara N, et al. Suppression of retinal neovascularization *in vivo* by inhibition of vascular endothelial growth factor (VEGF) using soluble VEGF-receptor chimeric proteins. *Proc Natl Acad Sci USA* 1995;93:10457-61.
7. Adamis AP, Shima DT, Tolentino MJ, Gragoudas ES, Ferrara N, Folkman J, D'Amore PA, et al. Inhibition of vascular endothelial growth factor prevents retinal ischemia-associated iris neovascularization. *Arch Ophthalmol* 1996;114:66-71.
8. Alon T, Hemo I, Itin A, Pe'er J, Stone J, Keshet E. Vascular endothelial growth factor acts as a survival factor for newly formed retinal vessels and has implications for retinopathy of prematurity. *Nat Med* 1995;1:1024-8.
9. Castellarin AA, Nasir MA, Sugino IK, Zarbin MA. Clinicopathological correlation of primary and recurrent choroidal neovascularisation following surgical excision in age-related macular degeneration. *Br J Ophthalmol* 1998;82:480-7.
10. Gragoudas ES, Adamis AP, Cunningham ET Jr, Feinsod M, Guyer DR; VEGF Inhibition Study in Ocular Neovascularization Clinical Trial Group. Pegaptanib for neovascular age-related macular degeneration. *N Engl J Med* 2004;351:2805-16.
11. Zacks DN, Ezra E, Terada Y, Michaud N, Connolly E, Gragoudas ES, Miller JW. Verteporfin photodynamic therapy in the rat model of choroidal neovascularization: angiogenic and histologic characterization. *Invest Ophthalmol Vis Sci* 2002;43:2384-91.
12. Postelmans L, Pasteels B, Coquelet P, El Ouardighi H, Verougstraete C, Schmidt-Erfurth U. Severe pigment epithelial alterations in the treatment area following photodynamic therapy

- for classic choroidal neovascularization in young females. *Am J Ophthalmol* 2004;138:803–8.
13. Parodi MB, Pozzo SD, Ravalico G. Retinal pigment epithelium changes after photodynamic therapy for choroidal neovascularization in pathological myopia. *Acta Ophthalmol Scand* 2007;85:50–4.
 14. Azab M, Boyer DS, Bressler NM, Bressler SB, Cihelkova I, Hao Y, Immonen I, et al. Verteporfin therapy of subfoveal minimally classic choroidal neovascularization in age-related macular degeneration: 2-year results of a randomized clinical trial. *Arch Ophthalmol* 2005;123:448–57.
 15. Framme C, Flucke B, Birngruber R. Comparison of reduced and standard light application in photodynamic therapy of the eye in two rabbit models. *Graefes Arch Clin Exp Ophthalmol* 2004;244:773–81.
 16. Gilpin D. Calculation of a new Meeh constant and experimental determination of burn size. *Burns* 1996;22:607–11.
 17. Gergakoudi I, Nichols MG, Foster TH. The mechanism of Photofrin photobleaching and its consequences for photodynamic dosimetry. *Photochem Photobiol* 1997;65:135–44.
 18. Henderson BW, Waldow SM, Mang TS, Potter WR, Malone PB, Dougherty TJ. Tumor destruction and kinetics of tumor cell death in two experimental mouse tumors following photodynamic therapy. *Cancer Res* 1985;45:572–6.
 19. Sitnik TM, Henderson BW. The effect of fluence rate on tumor and normal tissue responses to photodynamic therapy. *Photochem Photobiol* 1998;67:462–6.
 20. Henderson BW, Fingar VH. Relationships of tumor hypoxia and response to photodynamic treatment in an experimental mouse tumor. *Cancer Res* 1987;47:3110–4.
 21. Treatment of age-related macular degeneration with photodynamic therapy (TAP) study group. Photodynamic therapy of subfoveal choroidal neovascularization in age-related macular degeneration with verteporfin—one-year results of 2 randomized clinical trials: TAP report 1. *Arch Ophthalmol* 1999;117:1329–45.
 22. Tatar O, Adam A, Shinoda K, Stalmans P, Eckardt C, Luke M, Bartz-Schmidt KU, et al. Expression of VEGF and PEDF in choroidal neovascular membranes following verteporfin photodynamic therapy. *Am J Ophthalmol* 2006;142:95–104.
 23. Lazic R, Gabric N. Intravitreal bevacizumab (Avastin) in minimally classic and occult choroidal neovascularization secondary to age-related macular degeneration. *Graefes Arch Clin Exp Ophthalmol* 2007;245:68–73.
 24. Sheu SJ, Chou LC, Bee YS, Chen JF, Lin HC, Lin PR, Lam HC, et al. Suppression of choroidal neovascularization by intramuscular polymer-based gene delivery of vasostatin. *Exp Eye Res* 2005;81:673–9.