

Bladder Perforation Related to Intrauterine Device

Mustafa Okan Istanbuluoglu¹, Emel Ebru Ozcimen², Bulent Ozturk^{1*}, Ayla Uckuyu²,
Tufan Cicek¹, Murat Gonen¹

Departments of ¹Urology, and ²Gynecology and Obstetrics, Baskent University School of Medicine, Turkey.

Intrauterine devices (IUDs) are currently one of the most popular reversible contraception methods used world wide. Uterine perforation is a rarely observed complication. The bladder is one of the organs that an IUD can migrate to because of its close proximity to the uterus. There are about 70 cases in the literature of IUDs that have migrated into the bladder. The resulting bladder perforation can be complete or partial. Here, we report 2 cases, 1 of complete migration and the other of partial migration. [*J Chin Med Assoc* 2008;71(4):207–209]

Key Words: intrauterine device, urinary bladder calculi, uterine perforation

Introduction

To date, there are about 70 cases in the literature of IUDs that have migrated into the bladder. The incidence of IUD perforation ranges from 0.05/1,000 to 13/1,000. Complications like stone formation within the bladder or infection related to IUD migration to the bladder have also been reported. Such patients mostly present with urinary symptoms.^{1–10} Here, we describe 2 patients who presented with different symptoms related to the migration of IUD to the bladder.

Case Reports

Case 1

A 32-year-old, gravida 2, para 2, woman presented to our outpatient clinic with turbid urine and frequently recurring infections. Her history revealed that the complaints had been present for 2 years, and she had been going to different centers for these 2 years, where multiple antibiotics had been prescribed. She had a T-type IUD (Pregna™ Copper T 380 A) that had been placed by a gynecologist 6 years previously, and she had had a normal vaginal delivery 4 years later with the IUD in place. Her complaints had begun soon after delivery.

Routine biochemical tests and complete blood count were normal. There were plenty of leukocytes

and pyuria in the urine. Urine culture was negative. A T-type IUD on the right side of the pelvis was observed on plain abdominal X-ray, as was an opaque stone measuring 2.5 × 1 cm in size (Figure 1). Ultrasound revealed a stationary stone within the bladder on the right wall.

Endoscopic intervention was planned, and the stone formation within the bladder was broken up with mechanical lithotripter. It was observed that the IUD was within the bladder. Grasper forceps were used to grab the embedded portion of the IUD, and the IUD was removed as a whole unit. The urinary catheter was removed on postoperative day 1. No fistula or adhesion formation was observed.

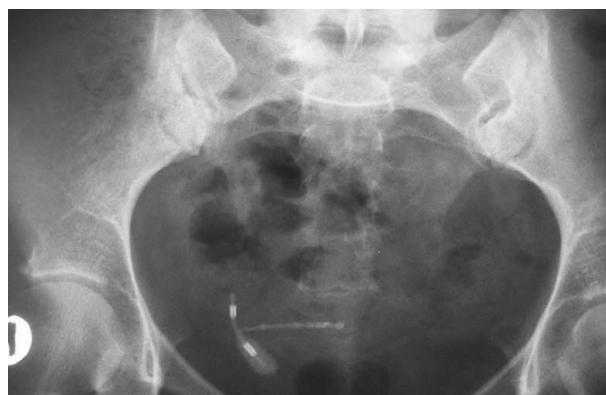

Figure 1. Migrated intrauterine device and stone seen on pelvic plain radiography.



*Correspondence to: Dr Bulent Ozturk, Department of Urology, Baskent University School of Medicine, Hoca Cihan Mah, Saray cad. No. 1 Konya/Turkey.

E-mail: bulentoz@yahoo.com • Received: June 20, 2007 • Accepted: February 21, 2008

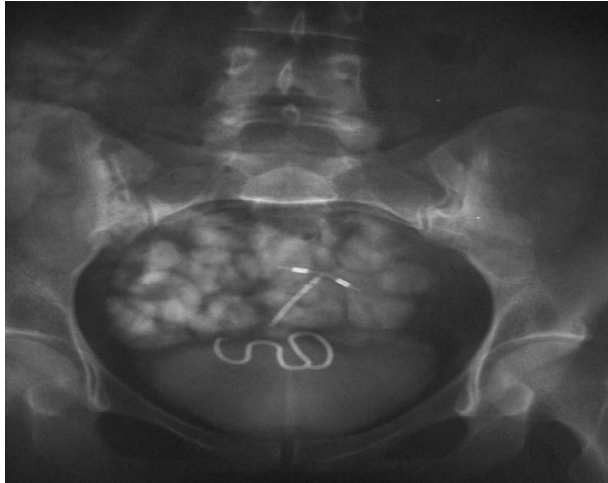


Figure 2. Two intrauterine devices seen on pelvic plain radiography.

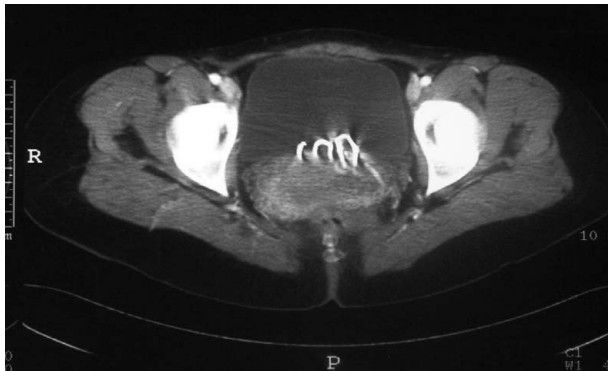


Figure 3. Computed tomography shows perforation of the uterus and migration of the intrauterine device into the bladder.

At the 1- and 6-month follow-up visits, the patient had no complaints and her urinalysis was normal.

Case 2

A 35-year-old, gravida 4, para 4, woman presented to the gynecology outpatient clinic with pain, dyspareunia and vaginal discharge. Her history revealed that a spiral-type IUD had been placed 14 years previously, and she had had a normal vaginal delivery 1 year after the placing of the IUD. Apart from the delivery, she had not undergone any uterine operations. She was told that her IUD had “fallen”, and another T-type IUD had been placed. Before placement of the T-shaped IUD, no pelvic examination had been performed.

Her blood tests were normal, culture of the discharge was negative, and there were inflammatory cells on the vaginal smear. Plain X-ray of the urinary system showed 2 IUDs in the pelvis (Figure 2). Vaginal ultrasound revealed that the spiral IUD was embedded in the uterine wall, while the T-type IUD was in its normal localization. The T-type IUD was removed

easily by pulling its string. Pelvic computed tomography showed that the spiral IUD had perforated the uterus and migrated to the bladder (Figure 3).

Cystoscopy was scheduled, during which it was observed that the IUD had not penetrated the bladder mucosa, and the mucosa was intact (partial bladder perforation). Pressure of the IUD was observed during cystoscopy. A clamp was used to grab and remove the IUD via the vagina. No complications such as perforation of the uterus or bleeding developed.

At the 2-month follow-up visit, the patient had no complaints and her tests were normal.

Discussion

IUDs are currently the most favored contraception method world wide. They can, however, lead to complications such as uterine perforation (which is rare) and pregnancy or infection (which are more frequent).^{2,4,5} The rare complication of perforation has been attributed to various causes in the literature, the number 1 cause being placement of the IUD by persons other than specialists. Most authors believe that IUD placement by specialists is very important in preventing perforation. However, migration of IUD placed by gynecologists, as in our case, has also been reported.^{2,4,10} In addition, infection and tissue damage caused by the vaginal speculum used during IUD placement can lead to adhesions and thus facilitate the perforation of the uterus.^{6,7}

As is well known, *Actinomyces* infections also facilitate the perforation of the uterus. *Actinomyces* infection can develop frequently in the presence of an IUD.^{6,8} Another notable issue is that IUD migration is more frequent in women who undergo labor with their IUD in place. Due to the reduction in the size of the uterus and thinning of the uterine walls in the postpartum and lactation periods as a result of hypoestrogenemia, the uterus becomes more susceptible to perforation.^{4,5,10} We believe that the cause of migration of the IUDs in our 2 cases was the delivery by the patients in the presence of their IUDs.

Symptoms such as chronic pelvic pain, vaginal discharge and irritation on voiding are seen when IUD has migrated into the bladder.^{2,3,9} While extraurinary system symptoms like chronic pelvic pain and dyspareunia were seen in our case without complete migration inside the bladder, we observed the symptoms of pyuria and irritation on voiding in the case with the complete migration of the IUD. Stones can form as a result of complete migration of the IUD. To date, approximately 70 cases of IUD migration to

the bladder have been reported in the literature, and about half of them resulted in stone formation, with established stone sizes varying from 1 cm to 8 cm.^{1,10} The foreign materials within the bladder acts as a nidus for stone formation, and infections constitute a separate predisposing factor.¹⁰

The most accurate method for imaging of lost IUD is computed tomography. Partial perforation can also be shown rather well with vaginal ultrasound.⁶ In addition, radiography is also useful, especially for finding the stone-forming IUDs.^{3,10} We were able to show very clearly in Case 2 that the S-type IUD had not completely migrated to the bladder, and that the migration was only partial. In Case 1, however, we did not need to use computed tomography since 1 arm of the IUD had petrified, and we directly planned cystoscopy.

Another controversial issue is treatment for cases of lost IUD. Many authors have stated that lost IUD should be treated since it can cause pain, infection, injury of neighboring organs, intra-abdominal adhesion, and even fatal complications like sepsis or intestinal obstruction.^{2-4,9,10} Minimally invasive methods such as laparoscopy or endoscopy are frequently preferred. However, Markovitch et al advocated in an article on a series of 3 patients that not all such patients required surgical treatment.⁶ The situation is different for the bladder; foreign material in the urothelium always leads to the risk of stone formation, and they must be treated.^{3,10} We treated the case with endoscopy, which had a stone within the bladder, and were able to remove the IUD causing partial perforation through the vagina.

Observation of bladder stones, particularly in women who have delivered babies in the presence of an IUD, and presence of urinary tract infections

resistant to treatment and symptoms such as dyspareunia and vaginal discharge should suggest the migration of IUD to the bladder. Endoscopic methods are efficient and safe for the treatment of such cases.

References

1. Grimaldi L, De Giorgio F, Andreotta P, D'Alessio MC, Piscicelli C, Pascalia VL. Medicolegal aspects of an unusual uterine perforation with multiload-Cu 375R. *Am J Forensic Med Pathol* 2005;26:365-6.
2. Ozcelik B, Serin IS, Basbug M, Aygen E, Ekmekcioglu O. Differential diagnosis of intra-uterine device migrating to bladder using radiographic image of calculus formation and review of literature. *Eur J Obstet Gynecol Reprod Biol* 2003;108:94-6.
3. Ozgur A, Sismanoglu A, Yazici C, Cosar E, Tezen D, Ilker Y. Intravesical stone formation on intrauterine contraceptive device. *Int Urol Nephrol* 2004;36:345-8.
4. Hoscan MB, Kosar A, Gumustas U, Guney M. Intravesical migration of intrauterine device resulting in pregnancy. *Int J Urol* 2006;13:301-2.
5. Guvel S, Tekin MI, Kilinc F, Peskircioglu L, Ozkardes H. Bladder stones around a migrated and missed intrauterine contraceptive device. *Int J Urol* 2001;8:78-9.
6. Markovitch O, Klein Z, Gidoni Y, Holzinger M, Beyth Y. Extrauterine mislocated IUD: is surgical removal mandatory? *Contraception* 2002;66:105-8.
7. Harrison-Woolrych M, Ashton J. Uterine perforation on intrauterine device insertion: is the incidence higher than previously reported? *Contraception* 2003;67:53-6.
8. Phupong V, Sueblinvong T, Pruksananonda K, Taneapanichskul S, Triratanachat S. Uterine perforation with Lippes loop intrauterine device-associated actinomycosis: a case report and review of the literature. *Contraception* 2000;61:347-50.
9. Hick EJ, Hernandez J, Yordan R, Morey AF, Avilés R, García CR. Bladder calculus resulting from the migration of an intrauterine contraceptive device. *J Urol* 2004;172:1903.
10. Atakan H, Kaplan M, Erturk E. Intravesical migration of intrauterine device resulting in stone formation. *Urology* 2002;60:911.