

Prenatal Diagnosis of Tetralogy of Fallot with Pulmonary Atresia

Jeng-Hsiu Hung^{1,5*}, Jen-Her Lu^{2,5}, Zen-Chung Weng^{3,5}, Chih-Yao Chen^{4,5}, Kuan-Chong Chao^{4,5},
Chia-Yi Selena Hung^{4,5}

¹Department of Obstetrics and Gynecology, Buddhist Tzu Chi General Hospital, Taipei Branch,
Departments of ²Pediatrics, ³Surgery and ⁴Obstetrics and Gynecology, Taipei Veterans General Hospital, and
⁵National Yang-Ming University School of Medicine, Taipei, Taiwan, R.O.C.

Tetralogy of Fallot involves an abnormal embryological development in which an unequal conotruncal division results in a small pulmonary artery and a great aortic artery. In its most severe form, the infundibulum of the right ventricle and the pulmonary artery can be atretic with the anomaly commonly referred to as pulmonary atresia with ventricular septal defect. Reported here is a case of prenatal diagnosis of tetralogy of Fallot with pulmonary atresia. The characteristic ultrasonographic findings included a small pulmonary artery, a large aorta, and a ventricular septal defect. The search for an atretic pulmonary valve and a ductus arteriosus with reversed blood flow was emphasized in the presence of asymmetrically dilated fetal heart. After birth, the newborn received single-stage total correction for the tetralogy of Fallot and was discharged a month later in stable condition. In this case report, the neonatal angiogram is added for confirming the prenatal diagnosis, which is of value in teaching fetal echocardiography to novice practitioners. We believe a prenatal diagnosis of tetralogy of Fallot can improve neonatal outcome. [*J Chin Med Assoc* 2008;71(5):262–266]

Key Words: prenatal diagnosis, pulmonary atresia, tetralogy of Fallot

Introduction

Tetralogy of Fallot (TOF) is not rare, but the correlation between prenatal ultrasonographic findings and its neonatal angiograms have rarely been published.^{1,2} Reported here is a case of prenatal diagnosis of tetralogy of Fallot with pulmonary atresia. The characteristic ultrasonographic findings included a small pulmonary artery, a large aorta, and a ventricular septal defect. The search for an atretic pulmonary trunk and a ductus arteriosus with reversed blood flow was emphasized in the presence of asymmetrically dilated fetal heart. After birth, the newborn received single-stage total correction for the tetralogy of Fallot and was discharged a month later in stable condition.

Case Report

A 25-year-old gravida was referred to our fetal diagnosis unit at 29⁺¹ gestational weeks because of suspected

fetal cardiac anomalies. Initial findings included asymmetrically dilated fetal left heart with pericardial effusion, which was 2.5 mm in width at the left pericardial region (Figure 1A). Fetal echocardiograms including standard 4-chamber view, 5-chamber view, right ventricular outflow tract, left ventricular outflow tract, short-axis and aortic arch views, and their respective pulse-wave Doppler flow recordings, were performed with a 2.0- to 5.0-MHz convex probe. A Voluson 730 (Kretztechnik AG, Tiefenbach, Austria) ultrasound apparatus was used for the ultrasound studies.

The 4-chamber view showed a ventricular septal defect 6.2 mm in length (Figure 1B). The cephalically tilted 5-chamber view of the fetal heart showed an enlarged aortic root overriding a defective ventricular septum (Figure 1C). The dilated aortic root measured 6.7 mm in width (reference range, 95% confidence interval [CI], 3.9–7.1 mm) (Figure 1C). The right ventricular outflow tract of the fetal heart in short-axis view demonstrated a right ventricle having narrowed pulmonary artery 3.2 mm in width (reference



*Correspondence to: Dr Jeng-Hsiu Hung, Department of Obstetrics and Gynecology, Buddhist Tzu Chi General Hospital, Taipei Branch, 289, Jianguo Road, Xindian City, Taipei 231, Taiwan, R.O.C.
E-mail: jhung@tzuchi.com.tw • Received: June 29, 2007 • Accepted: December 13, 2007

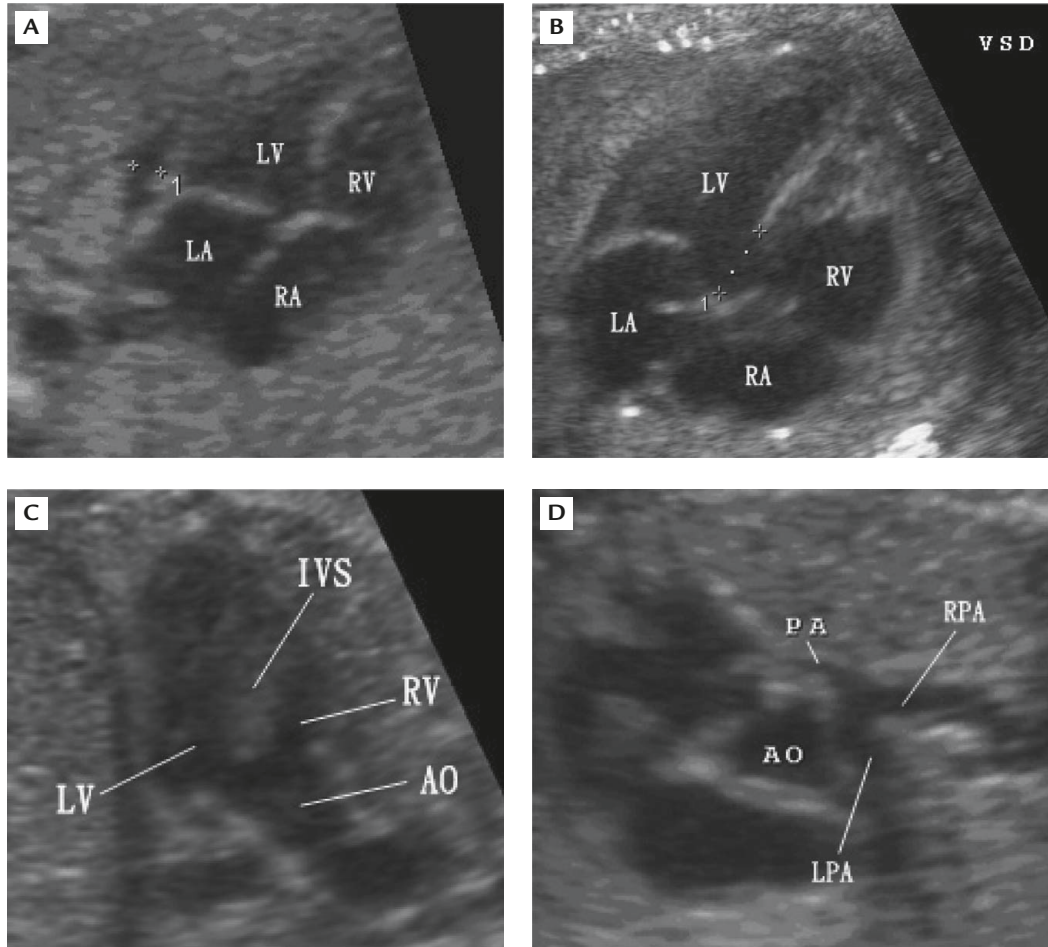


Figure 1. (A) Two-dimensional 4-chamber view of the fetal heart at 29⁺¹ gestational weeks shows mild pericardial effusion in the left heart. (B) The 4-chamber view of the fetal heart shows a large ventricular defect measuring 6.29 mm in width. (C) The 5-chamber view of the fetal heart shows an enlarged aortic root overriding a defective interventricular septum. (D) The short-axis view of the fetal heart shows narrowed diameter of the pulmonary artery. Bifurcation of the artery is also presented. LV = left ventricle; RV = right ventricle; LA = left atrium; RA = right atrium; AO = aorta; IVS = intraventricular septum; RPA = right pulmonary artery; LPA = left pulmonary artery; PA = pulmonary artery.

range, 95% CI, 4.9–8.9 mm) at 29⁺¹ gestational weeks (Figure 1D).

On color flow mapping, the 5-chamber view of the fetal heart showed an enlarged aorta overriding a defective interventricular septum (Figure 2A). The short-axis view showed pulmonary trunk with reversed blood flow (Figure 2B). The aortic arch view showed reversed blood flow at the ductus arteriosus (Figure 2C). A reversed-pulse Doppler flow was detected at the ductus arteriosus in short-axis view (Figure 2D).

Other than the fetal cardiac anomalies described, fetal karyotyping revealed a normal 46,XY chromosome. The fetal pericardial effusion subsided after maternal bed rest 2 weeks later. At 40⁺⁵ gestational weeks, labor was induced with oxytocin, but persistent fetal tachycardia (fetal heart rate, 160–165 beats/min) was recorded. Cesarean section was performed due to the

non-reassuring fetal status. The male neonate appeared to have mild cyanotic symptoms and weighed 3,800 g, with Apgar scores of 8 and 9 at 1 and 5 minutes, respectively. Neonatal echocardiography was performed immediately after birth, and findings confirmed TOF with pulmonary atresia. Cyanosis with oxygen desaturation of 74% breathing room air was found in the neonate after birth. Neonatal EKG showed sinus tachycardia, and the neonate was admitted to the neonatal intensive care unit for further evaluation and management.

On the 3rd postnatal day, cardiac catheterization was performed for presurgical preparation. The anterior posterior view of the right ventriculogram demonstrated an enlarged aortic root (Figure 3A). The aortic root was overriding a defective interventricular septum (Figure 3A). The lateral view demonstrated the hypoplastic infundibulum with an atretic pulmonary

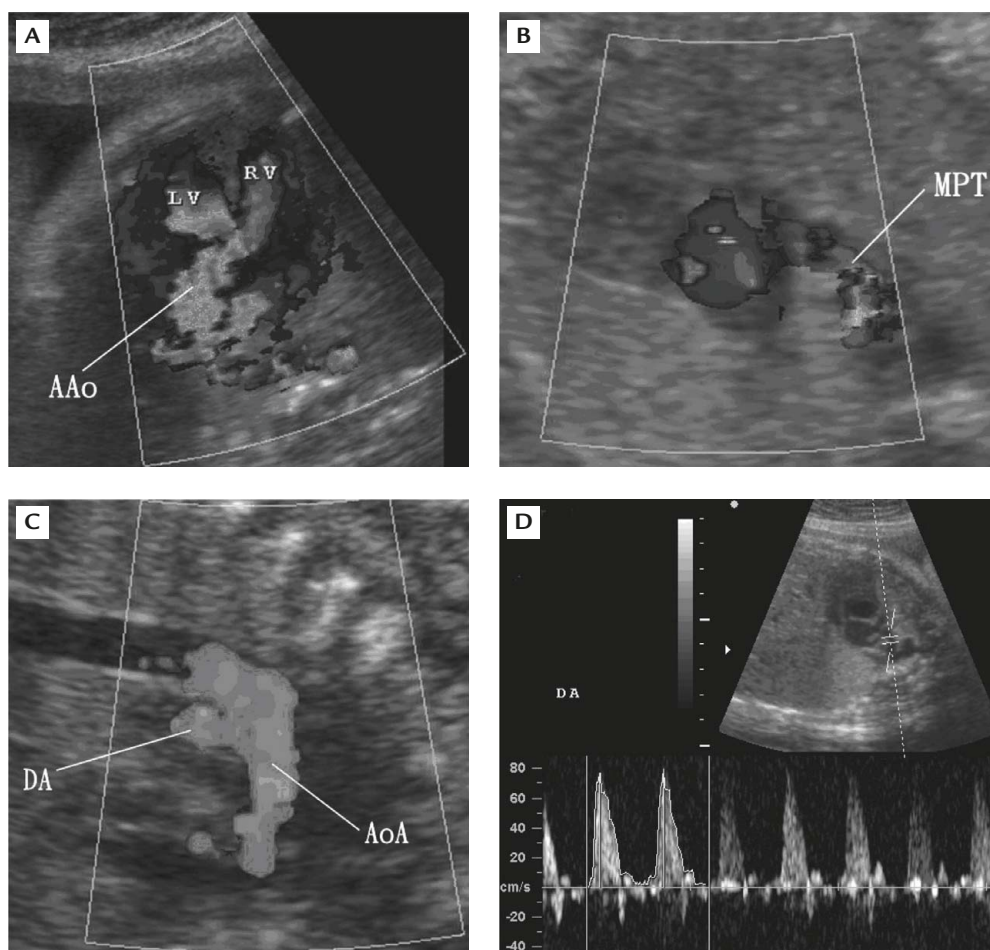


Figure 2. (A) The 5-chamber view of color flow mapping shows a ventricular defect and an enlarged ascending aorta (AAo). (B) The short-axis view of the fetal heart shows that the pulmonary trunk artery (MPT) is fed with reversed blood flow from the ductus arteriosus. (C) The longitudinal aortic arch view shows an enlarged ductus arteriosus (DA) that is fed with aortic flow from the aortic arch (AoA). (D) Doppler flow mapping of a short-axis view of the fetal heart. The directionality of the blood flow is reversed to normal. LV = left ventricle; RV = right ventricle.

trunk (Figure 2B). The posterior anterior view of the aortogram demonstrated the vertical duct originating from the aortic arch, running horizontally at first, then curving downward and connecting with the pulmonary trunk (Figures 3C and 3D). The ductus arteriosus, arising from the middle of the aortic arch, was supplying both the strictured right pulmonary artery and the patent left pulmonary artery. Under the impression of TOF with pulmonary atresia, and patent ductus arteriosus supplying the pulmonary trunk, the newborn received prostaglandin E1 for keeping the vertical ductus arteriosus open.

After further discussion with family members, the newborn was scheduled for total correction of the fetal heart. The surgical intervention for total correction was performed on the 27th day after birth. The operational procedures included patent ductus arteriosus ligation, ventricular septal defect repair, and right ventricular outflow track reconstruction. Partial resection of the

hypertrophic muscle bands over the right ventricle was also performed. The ventricular septal defect was repaired with Gore-Tex patch (W.L. Gore & Associates, Newark, NJ, USA), and the right ventricular outflow track was reconstructed with expanded polytetrafluoroethylene monocuspid-valved equine pericardial patch. The right atriotomy was closed with 6-0 prolene suture. On the 19th day after single-stage operation, EKG readings showed normal sinus rhythms. The oxygen saturation breathing room air was higher than 90%. The newborn was discharged weighing 4,090 g and in stable condition.

Discussion

TOF may not cause systemic hemodynamic compromise in the uterus. Even in cases of very tight infundibular stenosis and pulmonary atresia, the combined

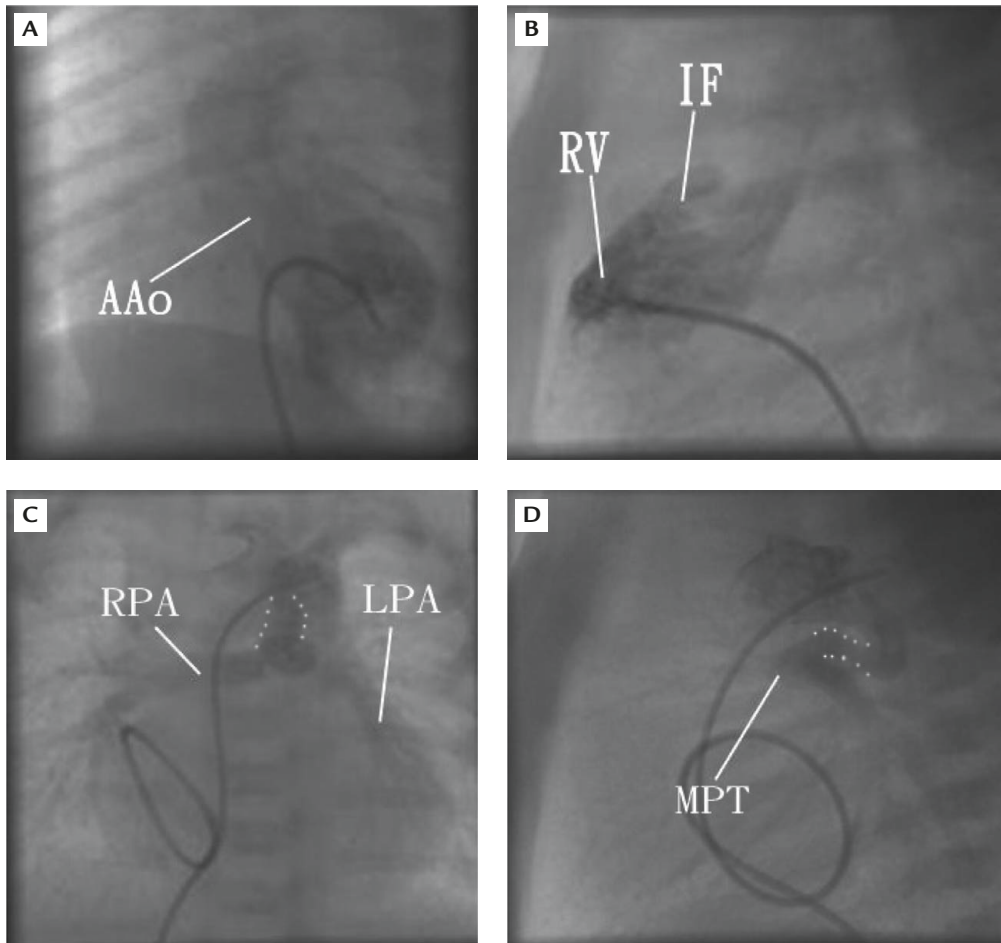


Figure 3. (A) The anteroposterior view of the angiogram of the newborn. The tip of the catheter is placed in the right ventricle. (B) The lateral view of the angiogram with tip of the catheter placed in the right ventricle. (C) The anteroposterior view of the angiogram with the tip of the catheter placed in the aortic arch. (D) The lateral view of the angiogram with the tip of the catheter placed in the aortic arch. The vertical ductus (dotted lines) and the pulmonary trunk can be observed. AAo = ascending aorta; RV = right ventricle; IF = infundibulum; RPA = right pulmonary artery; LPA = left pulmonary artery; MPT = pulmonary trunk artery.

output of both ventricles is directed toward the aorta, and the pulmonary vascular bed is supplied by reversed flow through the ductus arteriosus. This concept is supported by the fact that the newborn growth rate of our case was within normal range and the birth weight was 3,800 g at 40⁺⁵ gestational weeks.

The neonatal angiograms of this malformation showed an atretic pulmonary valve and a vertical duct originating from the aortic arch supplying both the strictured right pulmonary artery and the patent left pulmonary artery. The atretic part of the pulmonary trunk of TOF proved difficult to image prenatally, but the findings of a vertical duct with reversed blood flow by color Doppler study indirectly confirmed the presence of an atretic pulmonary valve.

In patients with pulmonary stenosis during fetal or neonatal life, the ductus tends to be more tortuous. It arises more cephalad on the aortic arch, and its aortic

origin is positioned more towards the concave apex of the arch, as shown in the angiogram (Figure 3C). The presence of such a vertical ductus may be related with late peripheral pulmonary stenosis. If there is severe pulmonary regurgitation after transannular patching of the right ventricular outflow tract, severe right-sided heart failure may result. The prenatal diagnosis of TOF with pulmonary atresia may herald that there are challenges ahead for the patient and physicians.

The traditional approach to managing TOF with pulmonary atresia has been to place a systemic-to-pulmonary artery shunt followed by a complete repair after the first 6 months of life. However, there has been a trend towards single-stage repair at an earlier age.³⁻⁶ It is certain from many reports, at least theoretically, that early single-stage repair can minimize the adverse effects of hypoxia, prevent organ damage, reduce development of severe right ventricular hypertrophy and

fibrosis, thereby avoiding extensive right ventricular muscle resection, reduce ventricular arrhythmias, and encourage the development of normal pulmonary vasculature with optimized functional outcomes.^{7,8} Most importantly, early single-stage repair of TOF with pulmonary atresia could avoid the use of extracardiac conduit and repeated surgery for conduit change as the child grows. In our case, the bilateral pulmonary arteries were potentially distensible. Therefore, rather than palliation therapy, single-stage primary repair by placing a systemic-to-pulmonary artery shunt was performed.

Traditionally, a transventricular approach for closure of ventricular septal defect has been widely used and is still in use with good results by many centers.^{9,10} The proposed advantages of the transventricular approach include closure of the malalignment-type ventricular septal defect seen with TOF, and a thorough examination and resection of the infundibular muscle bundles. The benefits of the transatrial/transpulmonary repair are derived from eliminating or minimizing a right ventriculotomy, which may cause late right ventricular dilatation and dysfunction as well as ventricular arrhythmia.¹¹ However, in TOF with pulmonary atresia, as in this case, transatrial transpulmonary repair is not feasible and traditional transventricular approach is the only choice.

Pulmonary regurgitation caused by transannular repairs is generally tolerable long after the operation. However, there are a certain percentage of patients who will eventually be hemodynamically compromised. Longstanding pulmonary regurgitation can result in right ventricular failure, progressive right ventricular distension, increasing tricuspid regurgitation, and ventricular arrhythmias leading to sudden death.^{12,13} Although the postoperative condition of this neonate was stable with normal sinus system without sign of right heart failure, close follow-up is essential to determine the function of the pulmonary valve in the patient. At this point, we believe a prenatal diagnosis of TOF has improved neonatal outcome.

Acknowledgments

This study was supported by research grants NSC 94-2314-B-075-014 from the National Science Council

and V96C1-159 from Taipei Veterans General Hospital, Taiwan, R.O.C.

References

- Juan CC, Hung GY, Chen YJ, Lee PC. Coexistence of peripheral primitive neuroectodermal tumor and tetralogy of Fallot. *J Chin Med Assoc* 2006;69:134-7.
- Liang CM, Hwang B, Lu JH, Lee PC, Weng ZC, Ho TY, Meng CC. Risk factors of prolonged postoperative pleural effusion after repair of tetralogy of Fallot. *J Chin Med Assoc* 2005;68:406-10.
- Fraser CD, McKenzie ED, Cooley DA. Tetralogy of Fallot: surgical management individualized to the patient. *Ann Thorac Surg* 2001;71:1556-63.
- Lee C, Lee CH, Kim SC, Lim C, Chang YH, Kang CH, Jo WM, et al. Outcome after single-stage repair of tetralogy of Fallot. *J Cardiovasc Surg* 2006;47:65-70.
- Bacha EA, Scheule AM, Zurakowski D, Erickson LC, Hung J, Lang P, Mayer JE, et al. Long-term results after early primary repair of tetralogy of Fallot. *J Thorac Cardiovasc Surg* 2001;122:154-61.
- Alexiou C, Mahmoud H, Al-Khaddour A, Gnanapragasam J, Salmon AP, Keeton BR, Monro JL, et al. Outcome after repair of tetralogy of Fallot in the first year of life. *Ann Thorac Surg* 2001;71:494-500.
- Cobanoglu A, Schultz JM. Total correction of tetralogy of Fallot in the first year of life: late results. *Ann Thorac Surg* 2002;74:133-8.
- Pozzi M, Trivedi DB, Kitchiner D, Arnold RA. Tetralogy of Fallot: what operation, at which age. *Eur J Cardiothorac Surg* 2000;17:631-6.
- Sousa Uva M, Lacour-Gayet F, Komiya T, Serraf A, Bruniaux J, Touchot A, Roux D, et al. Surgery for tetralogy of Fallot at less than six months of age. *J Thorac Cardiovasc Surg* 1994;107:1291-300.
- Alexiou C, Chen Q, Galogavrou M, Gnanapragasam J, Salmon AP, Keeton BR, Haw MP, et al. Repair of tetralogy of Fallot in infancy with a transventricular or a transatrial approach. *Eur J Cardiothorac Surg* 2002;22:174-83.
- Giannopoulos NM, Chatzis AK, Karros P, Zavaropoulos P, Papagiannis J, Rammos S, Kirvassilis GV, et al. Early results after transatrial/transpulmonary repair of tetralogy of Fallot. *Eur J Cardiothorac Surg* 2002;22:582-6.
- Ilbawi MN, Idriss FS, DeLeon SY, Muster AJ, Gidding SS, Berry TE, Paul MH. Factors that exaggerate the deleterious effects of pulmonary insufficiency on the right ventricle after tetralogy repair. Surgical implications. *J Thorac Cardiovasc Surg* 1987;93:36-44.
- Bove EL, Byrum CJ, Thomas FD, Kavey RE, Sondheimer HM, Blackman MS, Parker FB Jr. The influence of pulmonary insufficiency on ventricular function following repair of tetralogy of Fallot. Evaluation using radionuclide ventriculography. *J Thorac Cardiovasc Surg* 1983;85:691-6.