

Prenatal Diagnosis of Isolated Fetal Hydrocolpos Secondary to Congenital Imperforate Hymen

Jenn-Jhy Tseng^{1,3,4*}, Jason Yen-Ping Ho¹, Wen-Hsien Chen², Min-Min Chou^{1,3}

Departments of ¹Obstetrics and Gynecology and ²Radiology, Taichung Veterans General Hospital, and ³Hung-Kuang University, Taichung, and ⁴Institute of Clinical Medicine, National Yang-Ming University School of Medicine, Taipei, Taiwan, R.O.C.

A 32-year-old primigravida was referred to our hospital at 36 weeks of gestation with a fetal pelvic mass. Ultrasonography showed the fluid-filled area to be a 9 × 4 × 5-cm pear-shaped retrovesical mass with a funnel-shaped blind pouch at the distal end of the fetal vagina. Marked left hydronephrosis resulting from mass compression was also detected. Fetal magnetic resonance imaging further defined a pelvic lesion extending cephalically into the abdomen and caudally into the vagina. Membranal protrusion of the introitus was clearly identified. Therefore, the diagnosis of congenital imperforate hymen with hydrocolpos was established. At 38 weeks of gestation, a 2,966-g female infant was delivered vaginally with good Apgar scores. Physical examination of the neonate revealed a bulging membrane covering the vaginal opening. The presence of syndromic disorders (McKusick-Kaufman, Ellis-van Creveld or Bardet-Biedl syndromes), genitourinary and anorectal anomalies were excluded. The karyotype was 46,XX. A hymenotomy was performed on the second day of life. The infant recovered fully after hymenotomy. [*J Chin Med Assoc* 2008;71(6):325–328]

Key Words: congenital, hydrocolpos, imperforate hymen, magnetic resonance imaging, prenatal diagnosis

Introduction

The incidence of congenital imperforate hymen in term infants has been reported to be 0.1%.¹ Prenatal diagnosis of isolated hydrocolpos secondary to congenital imperforate hymen is a rare condition in prenatal ultrasound examination. It is important to prenatally confirm the presence of associated anomalies, which helps in the provision of proper counseling for the parents and planning of postnatal management. Here, we report a case of isolated hydrocolpos secondary to congenital imperforate hymen antenatally diagnosed and characterized by ultrasonography and magnetic resonance imaging (MRI).

Case Report

A 32-year-old primigravida was referred to our hospital for prenatal care at 36 weeks of gestation because of a fetal pelvic mass. Ultrasonography showed the suspicious

area to be a 9 × 4 × 5-cm pear-shaped retrovesical mass. The fluid-filled lesion presented as a blind pouch at the distal end of the fetal vagina (Figure 1A). The urinary bladder was of normal appearance (Figure 1B). Marked left hydronephrosis possibly resulting from compression by the pelvic mass was concomitantly detected. Fetal MRI defined a pelvic lesion with homogeneously low signal intensity on coronal T1-weighted image (Figure 1C). The mass extended cephalically into the abdomen and caudally into the vagina. The fetal uterus without fluid accumulation was visible on the top of the mass. Membranal protrusion of the introitus was identified. Furthermore, the presence of meconium extending down to the rectum and appearing as a hyperintense signal on axial T1-weighted sequence was detected (Figure 1D). The spine and sacrum were not unusual. Therefore, the diagnosis of congenital imperforate hymen with isolated hydrocolpos was established.

At 38 weeks of gestation, a 2,966-g female infant was delivered vaginally with good Apgar scores. Physical examination of the neonate revealed a bulging



*Correspondence to: Dr Jenn-Jhy Tseng, Department of Obstetrics and Gynecology, Taichung Veterans General Hospital, 160, Section 3, Taichung-Kang Road, Taichung 407, Taiwan, R.O.C.
E-mail: t1018@vghtc.gov.tw • Received: October 15, 2007 • Accepted: January 23, 2008

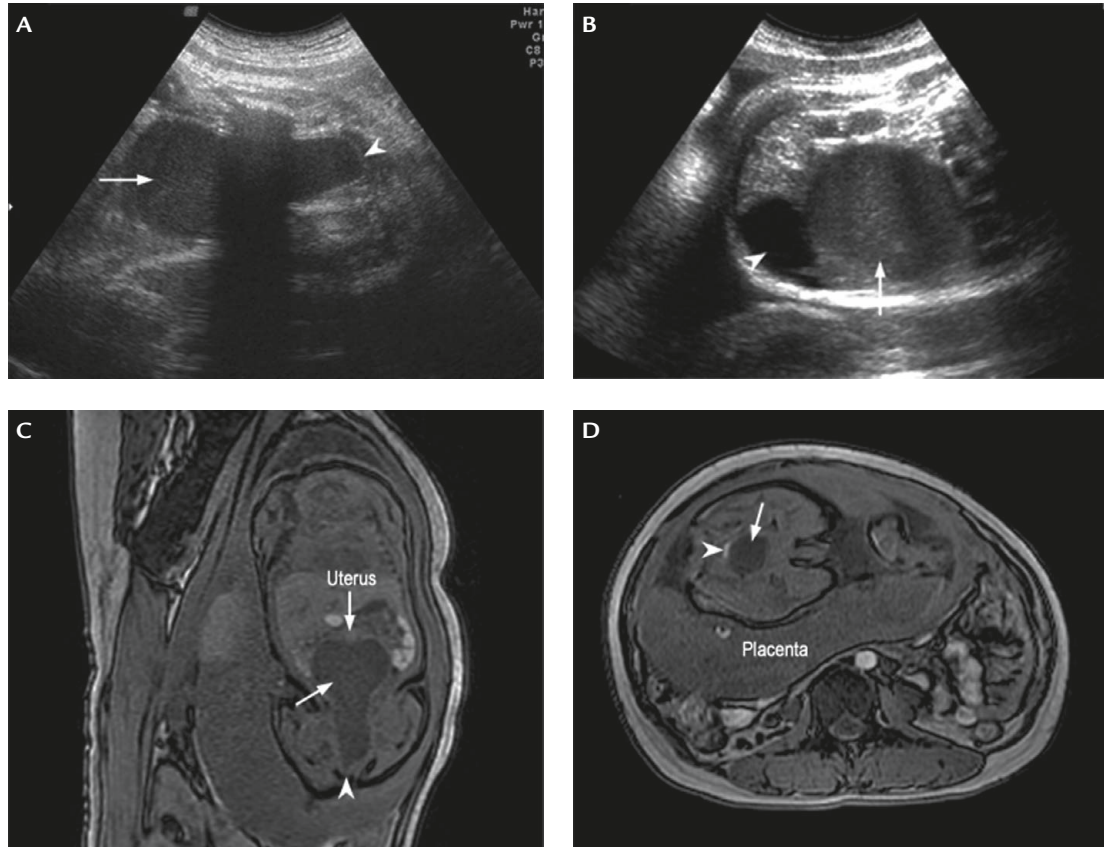


Figure 1. (A) Sagittal ultrasonography of the fetal pelvis shows a pear-shaped mass (arrow) presenting as a blind pouch at the distal end of the fetal vagina (arrowhead). (B) Transverse ultrasonography demonstrates a fluid-filled mass (arrow) behind the urinary bladder (arrowhead). (C) Coronal T1-weighted magnetic resonance imaging (MRI) identifies the uterus without fluid accumulation visible at the top of the mass (arrows). The arrowhead indicates the membranous protrusion of the introitus. (D) Axial T1-weighted MRI shows a hyperintense intrarectal signal (arrowhead) behind the hydrocolpos (arrow).

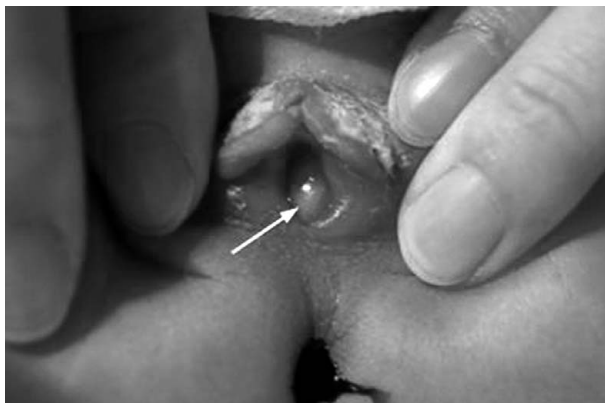

Figure 2. The neonate has a bulging membrane covering the vaginal opening (arrow).

membrane covering the vaginal opening (Figure 2). After detailed examination, the presence of syndromic disorders (e.g. McKusick-Kaufman, Ellis-van Creveld or Bardet-Biedl syndromes), genitourinary (e.g. persistent urogenital sinus) and anorectal (e.g. cloacal dysgenesis)

anomalies were excluded. The infant's karyotype was 46,XX. Umbilical venous estradiol concentration was 8,157 pg/mL (normal range in Asian subjects delivered at term is 5,480–8,020 pg/mL).²

Hymenotomy was performed on the second day of life to relieve compression-induced hydronephrosis, and 80 mL of yogurt-like whitish fluid was subsequently drained. Microscopically, intracellular glycogen content was detected by periodic acid-Schiff (PAS) stain in the desquamated cells from the vaginal discharge. The infant recovered fully after hymenotomy, which was followed by resolution of hydronephrosis.

Discussion

Failure of the hymen to rupture during the perinatal period results in imperforate hymen.³ It is most commonly an isolated finding and usually remains asymptomatic until puberty. The incidence of congenital imperforate hymen in term infants has been reported to

Table 1. Summary of prenatal ultrasound (US) and magnetic resonance imaging (MRI) findings of hydro(metro)colpos in recent literature

Reference	GA (wk)	US findings	MRI findings	Associated abnormalities	Neonatal diagnosis	Treatment and outcome
Hayashi et al ¹⁰	35	Retrovesical septate hypoechoic mass (7 cm)	Fluid-filled dilated uterus with a mid-plane septum; intrarectal meconium not clearly visible	No	Hydrometrocolpos with septate vagina and uterus didelphys, anal atresia, & ambiguous genitalia	Colostomy, anorectoplasty, and vaginoplasty; well with normal development
Dhombres et al ¹²	23	Retrovesical cystic mass, size unknown	Partially septate hydrocolpos with 2 hemi-uteri and moderate ascites; intrarectal meconium	Bilateral hydronephrosis	Septate hydrocolpos with uterus didelphys caused by persistent urogenital sinus	Died on postnatal day 1 due to multiorgan failure
Dhombres et al ¹²	30	Large pelvic cyst with septation, another cyst with thick wall at top right of cyst	2 hemi-uteri & 2 hemi-hydrocolpos; intrarectal meconium not visible	Bilateral hydronephrosis	Cloacal dysgenesis with hydrometrocolpos	Termination at gestation wk 33; expired
Picone et al ¹³	33	Anechoic pelvic mass (10 × 6 × 5 cm) behind fetal bladder	Fluid-filled uterus above cystic mass; intrarectal meconium	Left hydronephrosis, right renal agenesis & single umbilical artery	Hydrometrocolpos with imperforate hymen	Spontaneous evacuation on day 1 after birth
Picone et al ¹³	29	Anechoic pelvic mass with vertical septum, posterior to bladder	Fluid-filled dilated vagina; intrarectal meconium; Müllerian duplication	No	Hydrocolpos with imperforate hymen	Spontaneous resolution <i>in utero</i>
Picone et al ¹³	33	Anechoic pelvic mass with vertical septum, posterior to bladder	Fluid-filled dilated vagina; no intrarectal meconium	Right hydronephrosis, single umbilical artery	Septate vagina with bilateral hydrocolpos & imperforate anus; cloacal malformation	Colostomy & proctoplasty; no resolution
Current case	36	Hypoechoic pelvic mass (9 × 4 × 5 cm), posterior to bladder	Fluid-filled dilated vagina; intrarectal meconium; membranous protrusion of introitus	Left hydronephrosis	Hydrocolpos with imperforate hymen	Resolution after hymenotomy

GA = gestational age at diagnosis.

be 0.1%.¹ In the presence of vaginal outflow obstruction, there is potential for significant accumulation of cervicovaginal secretion during fetal life that occurs secondary to circulating estrogens.⁴ Elevated umbilical vein estradiol concentration and positive PAS stain (glycogen content) in the desquamated cells was observed in our case, compatible with the influence of estrogen on the development of fetal hydrocolpos secondary to congenital imperforate hymen.

Prenatal diagnosis of imperforate hymen with hydrometrocolpos has been reported as early as 25 weeks of gestation,⁵ although most cases are described during late gestation or after birth.^{6,7} This accounts for 15% of abdominal masses in female infants.⁸ The differential diagnosis of such a pelvic mass should include distended urinary bladder, ovarian neoplasm, reduplication of the sigmoid, and sacrococcygeal teratoma.⁹ Associated genitourinary (e.g. persistent urogenital sinus and nephronia) and anorectal anomalies (e.g. cloacal dysgenesis) have been mentioned.^{5,6,10,11}

In our case, the associated hydrocolpos manifested as a distended vagina and appeared as a pear-shaped cystic mass with diffuse low-level echoes. A distal vaginal obstruction was characterized by the ultrasonographic findings of a blind pouch covered by a thin membrane at the distal end of the vagina. However, imperforate hymen or transverse vaginal septum cannot be clearly differentiated by ultrasound examination only. Fetal MRI identified a membranous protrusion of the introitus and facilitated the ultimate diagnosis of congenital imperforate hymen. Furthermore, MRI is mandatory to specify fetal pelvic anatomy. Among the possible associated anomalies, cloacal dysgenesis carries the worst prognosis. In our case, the presence of a hyperintense T1 meconium signal (due to high protein content and mineral components) in the fetal rectum was found. Like reports published recently, the visualization of intrarectal meconium on T1 sequences could rule out any cloacal malformation (Table 1).^{10,12,13} The prognosis and neonatal management of isolated hydrocolpos differs greatly from that of hydrocolpos associated with cloacal dysgenesis. Therefore, MRI provides important

information for diagnosis, counseling and management of this anomaly.

In summary, the presence of prenatally detected hydrocolpos secondary to imperforate hymen warrants detailed imaging evaluation of fetal anatomy to exclude a large variety of malformations or syndromes.

References

1. Kahn R, Duncan B, Bowes W. Spontaneous opening of congenital imperforate hymen. *J Pediatr* 1975;87:768–70.
2. Shibata A, Harris DT, Billings PR. Concentrations of estrogens and IGFs in umbilical cord blood plasma: a comparison among Caucasian, Hispanic, and Asian-American females. *J Clin Endocrinol Metab* 2002;87:810–5.
3. Moore KL. The urogenital system. In: Moore KL, Persaud TVN, eds. *The Developing Human: Clinically Oriented Embryology*. Philadelphia: WB Saunders, 1982:255–97.
4. Spence HM. Congenital hydrocolpos. *JAMA* 1962;180:1100–5.
5. Winderl LM, Silverman RK. Prenatal diagnosis of congenital imperforate hymen. *Obstet Gynecol* 1995;85:857–60.
6. Odibo AO, Turner GW, Borgida AF, Rodis JF, Campbell WA. Late prenatal ultrasound features of hydrometrocolpos secondary to cloacal anomaly: case reports and review of the literature. *Ultrasound Obstet Gynecol* 1997;9:419–21.
7. Respondek-Liberska M, Krason A, Kaczmarek P, Jedrzejczyk S, Nowiczewski M, Chilarski A, Czichos E. Fetal hydrometrocolpos: not only diagnostic but also therapeutic dilemmas. *Ultrasound Obstet Gynecol* 1998;11:155–6.
8. Reed MH, Griscom NT. Hydrometrocolpos in infancy. *AJR Am J Roentgenol* 1973;118:1–13.
9. Westerhout FC, Hodgman JE, Anderson GV, Sack RA. Congenital hydrocolpos. *Am J Obstet Gynecol* 1964;89:957–61.
10. Hayashi S, Sago H, Kashima K, Kitano Y, Kuroda T, Honna T, Nosaka S, et al. Prenatal diagnosis of fetal hydrometrocolpos secondary to a cloacal anomaly by magnetic resonance imaging. *Ultrasound Obstet Gynecol* 2005;26:577–9.
11. Shen MC, Yang LY. Imperforate hymen complicated with pyocolpos and lobar nephronia. *J Chin Med Assoc* 2006;69:224–7.
12. Dhombres F, Jouannic JM, Brodaty G, Bessiere B, Daffos F, Benifla JL. Contribution of prenatal imaging to the anatomical assessment of fetal hydrocolpos. *Ultrasound Obstet Gynecol* 2007;30:101–4.
13. Picone O, Laperelle J, Sonigo P, Levailant JM, Frydman R, Senat MV. Fetal magnetic resonance imaging in the antenatal diagnosis and management of hydrocolpos. *Ultrasound Obstet Gynecol* 2007;30:105–9.