

# Prepubertal Testicular Germ Cell Tumors: 25-year Experience in Taipei Veterans General Hospital

Yin-Shen Chen<sup>1</sup>, Junne-Yih Kuo<sup>1\*</sup>, Tai-Wai Chin<sup>2</sup>, Chou-Fu Wei<sup>2</sup>, Kuang-Kuo Chen<sup>1</sup>,  
Alex T.L. Lin<sup>1</sup>, Luke S. Chang<sup>1</sup>

<sup>1</sup>Division of Urology, Department of Surgery, Taipei Veterans General Hospital, and Department of Urology, National Yang-Ming University School of Medicine; <sup>2</sup>Division of Pediatric Surgery, Department of Surgery, Taipei Veterans General Hospital, and Department of Surgery, National Yang-Ming University School of Medicine, Taipei, Taiwan, R.O.C.

**Background:** Due to the rarity of testicular tumors in the prepubertal population, adequate information about their biological course is difficult to document well in a single institution. The purpose of this study was to focus on prepubertal males in an attempt to evaluate clinical features and optimal management among various testicular germ cell tumors with long-term follow-up.

**Methods:** We retrospectively reviewed the records of children younger than 12 years of age with primary testicular germ cell tumors between February 1981 and December 2005 at Taipei Veterans General Hospital. Thirty-four children were diagnosed with adequate clinical and pathologic data. The stage of the disease was determined according to the staging system used by the Children's Oncology Group. Mean follow-up time was 139 months (range, 2–283 months).

**Results:** All of the 34 prepubertal patients were diagnosed initially with a painless scrotal mass. The mean age of the patients at diagnosis ranged from 6 months to 84 months (mean, 20.5 months). All patients underwent radical orchiectomy as an initial treatment. Twenty-nine (85.3%) patients had yolk sac tumors, and 5 (14.7%) had mature teratomas. Of the 29 patients with yolk sac tumor, 26 (89.7%) were diagnosed as stage I, 1 (3.4%) as stage III, and 2 (7.0%) as stage IV. Five (19.2%) of the 26 stage I yolk sac tumors progressed to metastasis after radical orchiectomy, and all of these 5 patients later received chemotherapy. One patient initially with stage III yolk sac tumor and 2 patients with stage IV yolk sac tumor were also treated with chemotherapy. Eventually, 1 patient with stage IV yolk sac tumor died due to tumor progression; the remaining 28 patients with yolk sac tumor all survived without tumor relapse after appropriate treatment. In the 5 patients with teratomas, there was no tumor relapse after radical orchiectomy with a mean follow-up time of 139.1 months. The 5-year survival rates for yolk sac tumor and teratomas were 96.5% and 100%, respectively.

**Conclusion:** The most common prepubertal malignant testicular tumor is yolk sac tumor, and the most common benign testicular tumor is teratoma. Children with testicular germ cell tumors have excellent long-term survival rates after appropriate treatment. [*J Chin Med Assoc* 2008;71(7):357–361]

**Key Words:** prepubertal testicular tumor, testicular teratoma, testicular yolk sac tumor

## Introduction

In children, testicular tumors are uncommon, with an incidence of approximately 0.5–2.0 per 100,000 individuals, and comprise about 1–2% of pediatric malignancies.<sup>1–3</sup> One study suggested that testicular tumors may be more common in Asian than in Caucasian

children.<sup>4</sup> However, only a few cases have been reported in East Asia.<sup>2,5–7</sup> To understand the differences in the clinical manifestations and optimal management of various prepubertal testicular tumors, we retrospectively reviewed 34 children with testicular tumor over the last 25 years at Taipei Veterans General Hospital in Taipei, Taiwan.



ELSEVIER

\*Correspondence to: Dr Junne-Yih Kuo, Division of Urology, Department of Surgery, Taipei Veterans General Hospital, 201, Section 2, Shih-Pai Road, Taipei 112, Taiwan, R.O.C.  
E-mail: jykuo@vghtpe.gov.tw • Received: July 23, 2007 • Accepted: April 28, 2008

## Methods

Between February 1981 and December 2005, 153 patients were diagnosed with testicular tumor in Taipei Veterans General Hospital. Children younger than 12 years of age with adequate clinical and pathologic data were evaluated. Tumor review criteria included patient age at diagnosis, presentation, radiologic investigation and tumor markers. All patients presented with a palpable scrotal mass and underwent radical orchiectomy via an inguinal approach as initial treatment. The disease stage was determined according to the staging system used by the Children's Oncology Group:<sup>8</sup> stage I, tumor limited to the testes; stage II, microscopic residual tumor or persistent elevated tumor markers after complete orchiectomy; stage III, tumor metastasis to retroperitoneal lymph nodes and size <4 cm; and stage IV, tumor metastasis to a site other than the retroperitoneal lymph nodes or retroperitoneal lymph nodes  $\geq$ 4 cm. Relapse was defined as increasing serum tumor markers, or the appearance of radiographic evidence of disease during follow-up.

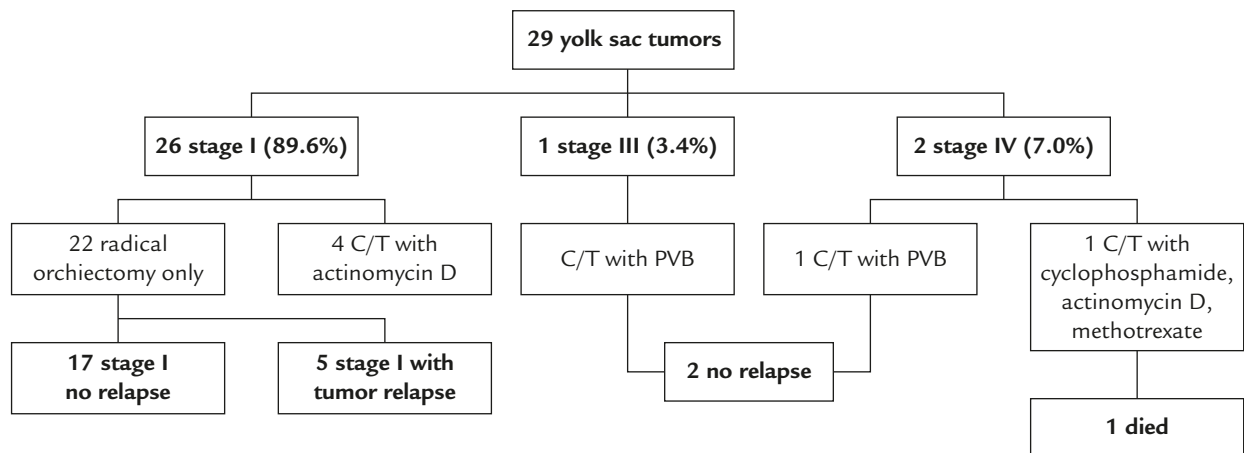
Over the 25-year period, the treatment of patients differed depending on the time of diagnosis. As shown in Figure 1, 4 patients with testicular stage I yolk sac tumors diagnosed before 1983 received adjuvant chemotherapy with actinomycin D monthly for 1 year after radical inguinal orchiectomy. The remaining 22 patients with stage I yolk sac tumor diagnosed after 1983 received radical orchiectomy only. The only stage III patient and 1 of 2 stage IV patients were treated with cisplatin, vinblastine and bleomycin (PVB). The other patient with stage IV yolk sac tumor with lung metastasis at diagnosis received chemotherapy with cyclophosphamide, actinomycin D and methotrexate.

Outcome data including tumor histopathology, evidence of metastases, treatment modalities and survival were included. Statistical analyses were performed using the Kaplan-Meier method. A probability level of  $p < 0.05$  was taken as statistically significant.

## Results

Between February 1981 and December 2005, there were 34 children (age <12 years) who were diagnosed with testicular tumors, and they were enrolled in the study. Twenty-nine yolk sac tumors and 5 teratomas in the children were reviewed. The mean prepubertal patient ages at diagnosis were 19.8 months (range, 6–47 months) and 24.9 months (range, 6–84 months) for yolk sac tumors and teratomas, respectively. All 34 patients were followed-up from 2 to 283 months, with a mean of 139 months after treatment.

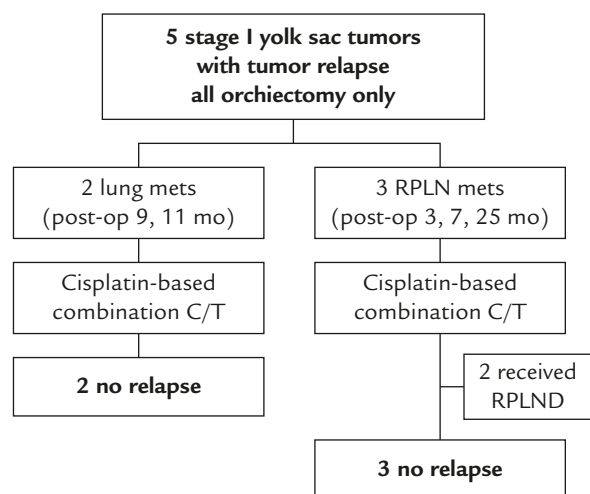
For the children with yolk sac tumor, all 29 had elevation of serum alpha-fetoprotein (AFP) at diagnosis. Serial preoperative AFP ranged from 60 to 66,641 ng/mL, with a mean of 6,537 ng/mL. As shown in Figure 1, there were 2 stage IV children who had lung metastasis at diagnosis. One died of progressive metastasis 2 months later despite chemotherapy. The other survived without relapse for 112 months after radical orchiectomy and chemotherapy with PVB. Additionally, 1 stage III child who had enlarged retroperitoneal lymph node survived without relapse for 15 years after radical orchiectomy and chemotherapy with PVB. For 26 children with stage I disease, 4 children who underwent adjuvant chemotherapy with actinomycin D had no tumor relapse with regular follow-up. Five of the remaining 22 stage I (19.2%) children with



**Figure 1.** Yolk sac tumors with various stages. C/T=chemotherapy; PVB=cisplatin, vinblastine and bleomycin.

stage I yolk sac tumor had recurrence with elevated AFP after the treatment of radical inguinal orchiectomy only. Then, chest radiograph or chest/abdominal computed tomography were performed. As shown in Figure 2, 2 patients with tumor recurrence in the lung were diagnosed 9 months and 11 months later, respectively, and the other 3 experienced recurrence over the retroperitoneum 3, 7 and 25 months post-orchiectomy, respectively. These 5 children with tumor relapse received cisplatin-based combination chemotherapy. Additionally, 2 of 3 patients with retroperitoneal lymph node metastasis underwent retroperitoneal lymph node dissection for residue mass after 6 cycles of chemotherapy. These 5 children with tumor recurrence after radical orchiectomy were all alive without relapse, and the mean follow-up was 212.6 months (range, 175.8–255.6 months).

In the 5 patients with teratomas, all pathologic reports were of stage I mature teratomas. Neither tumor recurrence nor distant metastasis was noted during follow-up. The 5-year survival rates for yolk sac tumors and teratomas were 96.5% and 100%, respectively.



**Figure 2.** Stage I yolk sac tumor with recurrence. C/T= chemotherapy; mets=metastasis; RPLN=retroperitoneal lymph node; RPLND=retroperitoneal lymph node dissection.

## Discussion

Testicular tumors in the prepubertal population are fundamentally distinct from those in the adult population. Adult testicular tumors are frequently comprised of a mixed histology, and they are often malignant.<sup>9</sup> In contrast, prepubertal testicular tumors typically contain only 1 histologic type, and they are either benign or malignant equally.<sup>10–13</sup> In our series, 14% (5/34) of prepubertal testicular tumors were benign testicular teratoma. The other 86% (29/34) of prepubertal testicular tumors were malignant and contained only 1 histologic type of yolk sac tumor.

Due to the rarity of prepubertal testicular tumors, the Section of Urology of the American Academy of Pediatrics (AAP) prompted the creation of the *Prepubertal Testicular Tumor Registry* (PTTR) in 1980, and Ross et al reported their most recent data on the demographics and natural history of prepubertal testis tumors in 2002.<sup>14</sup> In the PTTR, the most common prepubertal testicular tumors were yolk sac tumors, and the second most common were teratomas. There were some reviews of prepubertal testicular tumors in East Asia (Table 1). Two long-term reviews for 30 and 27 years, respectively, from 2 Japan medical centers revealed that the most common prepubertal testicular tumors were yolk sac tumors.<sup>5,6</sup> Additionally, there were 25 prepubertal yolk sac tumors and 24 mature teratomas in Beijing Children's Attached Hospital of Capital Medical University.<sup>7</sup> The largest multi-institutional report on prepubertal testicular tumors in Asia is from Korea.<sup>2</sup> There, 100 yolk sac tumors and 83 teratomas were recorded. In all of the above reports, the results were consistent with our report. The most common type of malignant tumor was yolk sac tumor, and the most common type of benign tumor was mature teratoma.

In yolk sac tumors, the epithelial lining of the cysts and tubules is the site of synthesis of AFP. So yolk sac tumors frequently secrete high concentrations of serum AFP, which is considered important in the diagnosis and follow-up of the tumors.<sup>15,16</sup> AFP is the fetal

**Table 1.** The incidence of prepubertal germ cell testicular tumors

	Country	Yolk sac tumor	Teratoma	Epidermal cyst	Other germ cell tumors
Ross et al <sup>14</sup>	USA	244	92	13	0
Kanto et al <sup>6</sup>	Japan	10	3	1	0
Terai et al <sup>5</sup>	Japan	7	5	0	0
Lee <sup>2</sup>	Korea	100	83	6	6 (mixed germ cell)
Song & Huang <sup>7</sup>	China	25	24	2	1 (seminoma)
This study	Taiwan	29	5	0	0
Total		415	212	22	7

albumin equivalent, and it is also produced by fetal hepatocytes. The concentration of AFP remains increased in all newborns until the age of 8 months (0–20 ng/mL), so serum AFP cannot be used to distinguish a yolk sac neoplasm from other testicular pathologies during this early period of life. However, increased AFP was reported in 94.7% of yolk sac tumors and 30.4% of teratomas.<sup>2</sup> But none of our teratoma patients aged 6–12 months old had AFP levels > 100 ng/mL. These data suggest that infants younger than 1 year with AFP > 100 ng/mL should be presumed to have a yolk sac tumor. In most cases, serum AFP levels can be monitored postoperatively to reliably indicate testicular tumor recurrence during follow-up.<sup>17,18</sup> If AFP levels do not decrease by the 5-day half-life after radical orchiectomy, residual tumor or metastatic disease should be considered. In our study, rising AFP concentrations were found in 5 children with tumor recurrence and correlated with the time of recurrence. Serum tumor markers play an important role in distinguishing among the different histologic types before surgery, and they are used to detect tumor recurrence or residual tumors after radical inguinal orchiectomy.

For stage I disease, active surveillance after radical orchiectomy can be followed without the need for adjuvant chemotherapy.<sup>19</sup> However, 10–25% of patients who received radical orchiectomy alone had a later relapse and subsequently died.<sup>20,21</sup>

Therefore, Liu et al<sup>22</sup> suggested that 2 or 3 courses of chemotherapy with PVB after radical orchiectomy for stage I prepubertal yolk sac tumor of the testis in children younger than 2 years was more effective compared with the standard treatment of radical orchiectomy alone.

A number of different cisplatin-based chemotherapy regimens, such as PVB and PEB (bleomycin, etoposide, cisplatin), have been used by the UK Children's Cancer Study Group. Many studies reported that, with current chemotherapy protocols, not only can all recurrences and metastasis be salvaged with platinum-based multi-agent chemotherapy,<sup>23</sup> but survival rates for all disease stages approach 100%, and there is less morbidity.<sup>17</sup>

In some studies, metastasis from yolk sac tumors in children are more likely to occur to the lung (20%) than to the retroperitoneum (4–6%).<sup>17,19</sup> Routine retroperitoneal lymph node dissection (RPLND) is excluded for the treatment of pediatric stage I yolk sac tumor, and many metastatic lymph nodes may be remitted after chemotherapy. The relapse-free survival rate of stage I yolk sac tumor was not improved after routine lymphadenectomy.<sup>24</sup> In our series, only 1 stage III yolk sac tumor (3.4%) and 3 relapsed stage I yolk sac tumors (10.3%) had retroperitoneal lymph node

metastasis. But the enlarged retroperitoneal lymph nodes in the patient with stage III tumor and 1 relapsed stage I patient were alleviated after chemotherapy, and RPLND was a needless operation in these patients. So, RPLND is not a routine operation for patients with retroperitoneal masses after chemotherapy.

Teratomas without pubertal change are uniformly benign in prepubertal testes.<sup>25</sup> As a result of their benign nature, testis-sparing surgery has evolved from radical orchiectomy due to there being no tumor recurrence with long-term follow-up.<sup>12,26</sup> In our study, preoperative diagnosis of teratomas could not be differentiated from malignancy. All 5 cases received radical orchiectomy. In teratoma, frozen section is an important practice to confirm the diagnosis of benign or malignant tumor and ensure complete tumor removal. Frozen section can also assess the adjacent testicular parenchyma to determine whether or not there are pubertal changes. A teratoma with presence of pubertal changes by frozen section is considered to be malignant. So radical orchiectomy and surveillance protocols similar to those performed in adult patients with teratomas are necessary as teratomas can be malignant in pubertal children.<sup>27</sup> Because of the extremely low incidence of multifocal disease and there being no discordance between frozen section and definitive histopathology in several series, testis-sparing surgery is considered safe for teratomas without pubertal change.<sup>28,29</sup>

In conclusion, of all prepubertal testicular tumors, the most common malignant tumor is yolk sac tumor, and the most common benign tumor is mature teratoma. Serum AFP is a useful tumor marker to distinguish different histologic types before surgery and to detect tumor recurrence or residual tumors after radical inguinal orchiectomy. Most of the patients in this study with distal metastasis or tumor relapse survived without disease after cisplatin-based combination chemotherapy. Teratomas without pubertal change are uniformly benign, and they do not require further radiographic follow-up for local or metastatic recurrence after radical orchiectomy. Due to the small number of testicular tumor cases, a multi-institutional report on prepubertal testicular tumors with long-term follow-up is necessary.

## References

1. Brosman SA. Testicular tumors in prepubertal children. *Urology* 1979;13:581–8.
2. Lee SD. Epidemiological and clinical behavior of prepubertal testicular tumors in Korea. *J Urol* 2004;172:674–8.
3. Kaplan GW, Cromie WC, Kelalis PP, Silber I, Tank ES Jr. Prepubertal yolk sac testicular tumors—report of the testicular tumor registry. *J Urol* 1988;140:1109–12.

4. Karamehmedovic O, Woodtli W, Pluss HJ. Testicular tumors in childhood. *J Pediatr Surg* 1975;10:109-14.
5. Terai A, Kawakita M, Yoshida O. Clinical experience with yolk sac tumors and teratoma in children. *Int J Urol* 1994;1:167-71.
6. Kanto S, Saito H, Ito A, Satoh M, Saito S, Arai Y. Clinical features of testicular tumors in children. *Int J Urol* 2004;11:890-3.
7. Song HC, Huang CR. Testicular tumors in children (report of 55 cases). *Chi J Urol* 2004;25:44-6.
8. Ritchey ML, Shamberger RC. Pediatric urologic oncology. In: Wein AJ, Kavoussi LR, Novick AC, Partin AW, Peters CA, eds. *Campbell's Urology*, 9<sup>th</sup> edition. Philadelphia: Saunders, 2007: 3900-5.
9. Reuter VE. Origins and molecular biology of testicular germ cell tumors. *Mod Pathol* 2005;18:S51-60.
10. Leonard MP, Jeffs RD, Leventhal B, Gearhart JP. Pediatric testicular tumors: the Johns Hopkins experience. *Urology* 1991; 37:253-6.
11. Kay R. Prepubertal testicular tumor registry. *Urol Clin North Am* 1993;20:1-5.
12. Sugita Y, Clarnette TD, Cooke-Yarborough C, Chow CW, Waters K, Hutson JM. Testicular and paratesticular tumours in children: 30 years' experience. *Aust N Z J Surg* 1999;69: 505-8.
13. Green DM. Testicular tumors in infants and children. *Semin Surg Oncol* 1986;2:156-62.
14. Ross JH, Rybicki L, Kay R. Clinical behavior and a contemporary management algorithm for prepubertal testis tumors: a summary of the Prepubertal Testis Tumor Registry. *J Urol* 2002;168:1675-8.
15. Homsy Y, Arrojo-Vila F, Khoriaty N, Demers J. Yolk sac tumor of the testicle: is retroperitoneal lymph node dissection necessary? *J Urol* 1984;132:532-6.
16. Talerman A, Haije WG, Baggerman L. Serum alphafetoprotein (AFP) in patients with germ cell tumors of the gonads and extragonadal sites: correlation between endodermal sinus (yolk sac) tumor and raised serum AFP. *Cancer* 1980;46:380-5.
17. Grady RW, Ross JH, Kay R. Patterns of metastatic spread in prepubertal yolk sac tumor of the testis. *J Urol* 1995;153: 1259-61.
18. Weissbach L, Altwein JE, Stiens R. Germinal testicular tumors in childhood. Report of observations and literature review. *Eur Urol* 1984;10:73-85.
19. Drago JR, Nelson RP, Palmer JM. Childhood embryonal carcinoma of testes. *Urology* 1978;12:499-503.
20. Hopkins TB, Jaffe N, Colodny A, Cassady JR, Filler RM. The management of testicular tumors in children. *J Urol* 1978;120: 96-102.
21. Green DM. The diagnosis and treatment of yolk sac tumors in infants and children. *Cancer Treat Rev* 1983;10:265-88.
22. Liu HC, Liang DC, Chen SH, Liu FL, Chang PY, Sheu JC, Wang NL. The stage I yolk sac tumor of testis in children younger than 2 years, chemotherapy or not? *Pediatr Hematol Oncol* 1998;15:223-8.
23. Haas RJ, Schmidt P, Gobel U, Harms D. Treatment of malignant testicular tumors in childhood: results of the German National Study 1982-1992. *Med Pediatr Oncol* 1994;23:400-5.
24. Kaplan WE, Firlit CF. Treatment of testicular yolk sac carcinoma in the young child. *J Urol* 1981;126:663-4.
25. Grady RW, Ross JH, Kay R. Epidemiological features of testicular teratoma in a prepubertal population. *J Urol* 1997; 158:1191-2.
26. Ross JH, Kay R, Elder J. Testis sparing surgery for pediatric epidermoid cysts of the testis. *J Urol* 1993;149:353-6.
27. Ross JH, Kay R. Prepubertal testis tumors. *Rev Urol* 2004; 6:11-8.
28. Tokuc R, Sakr W, Pontes JE, Haas GP. Accuracy of frozen section examination of testicular tumors. *Urology* 1992;40:512-6.
29. Valla JS. Testis-sparing surgery for benign testicular tumors in children. *J Urol* 2001;165:2280-3.