

Idiopathic Pulmonary Hemosiderosis: Favorable Response to Corticosteroids

Chung-Hua Chen¹, Hsiao-Bai Yang², Shyh-Ren Chiang³, Po-Chien Wang^{4*}

¹Department of Internal Medicine, Hope Doctors Hospital, Miao Li, Departments of ²Pathology and

⁴Internal Medicine, Ton-Yen General Hospital, Jhubei, Hsinchu, and ³Department of Internal Medicine, Chi-Mei Foundation Hospital, Tainan, Taiwan, R.O.C.

A 50-year-old Taiwanese woman had a history of massive hemoptysis occurring every 6 months for the past 4 years. After each bout of hemoptysis, chest roentgenography would show diffuse alveolar infiltration of bilateral lungs, which would usually resolve within 7 days. Transbronchial biopsy revealed diffuse alveolar hemorrhage and hemosiderin-laden macrophage infiltration. Idiopathic pulmonary hemosiderosis was diagnosed by excluding other glomerular, cardiac and immunological disorders. An initial dose of 20 mg prednisolone daily was tapered to 10 mg daily 1 month later. The patient is currently undergoing steroid therapy, and there have been no further episodes of hemoptysis. [*J Chin Med Assoc* 2008;71(8):421–424]

Key Words: diffuse alveolar hemorrhage, hemoptysis, idiopathic pulmonary hemosiderosis

Introduction

Idiopathic pulmonary hemosiderosis (IPH) is a very rare disease that causes diffuse alveolar hemorrhage. Its clinical course is exceedingly variable, and delayed diagnosis is common. Effective treatment of this disease requires a high degree of clinical suspicion and accurate differential diagnosis. The clinical characteristics of IPH include repeated episodes of hemoptysis, diffuse pulmonary infiltration, and iron deficiency anemia. Pathologic indication is abnormal hemosiderin iron deposits in the alveoli macrophages. The estimated incidence was 0.24 per million children in Sweden and 1.23 per million in Japan.¹ Most cases occur in children and young adults, usually male.² IPH is extremely rare in adults. Only 10 cases have been reported in the last 10 years. Here, we report a case of IPH in a middle-aged woman who responded favorably to corticosteroid treatment.

Case Report

After 4 days of coughing fresh blood, a 50-year-old Taiwanese postmenopausal housewife was examined

by the authors on February 18, 2005. She also complained of productive cough, shortness of breath, and orthopnea of 1 month's duration. She had experienced the same symptoms recurrently every 6 months for the past 4 years. She denied nasal bleeding, hematuria, body weight loss, or nocturnal sweating during the course of her illness. Her past history was unremarkable except that she had been receiving amlodipine 5 mg/day for the treatment of hypertension for 4 years. Physical examination revealed a middle-aged woman in mild cardiopulmonary distress. Her conjunctivae were pale. Wheezes and crackles could be heard from the chest bilaterally. She did not have a murmur on heart auscultation. Her liver and spleen were not palpable, and she did not have pitting edema.

Peripheral white cell count was 13,430/mm³, hemoglobin was 10.7 g/dL, and platelet count was 318,000/mm³. Serum biochemistry revealed blood urea nitrogen of 14 mg/dL, creatinine of 0.7 mg/dL, alanine aminotransferase of 27 IU/L, aspartate aminotransferase of 27 IU/L, prothrombin time of 11.3 seconds, and activated partial thromboplastin time of 30.4 seconds. Serum C-reactive protein level was 0.5 mg/dL. Electrocardiography was normal. Chest roentgenography showed diffuse alveolar infiltration



*Correspondence to: Dr Po-Chien Wang, Department of Internal Medicine, Ton-Yen General Hospital, 69, Sianjheng 2nd Road, Jhubei, Hsinchu 302, Taiwan, R.O.C.

E-mail: pochienwang@gmail.com • Received: August 23, 2007 • Accepted: March 24, 2008

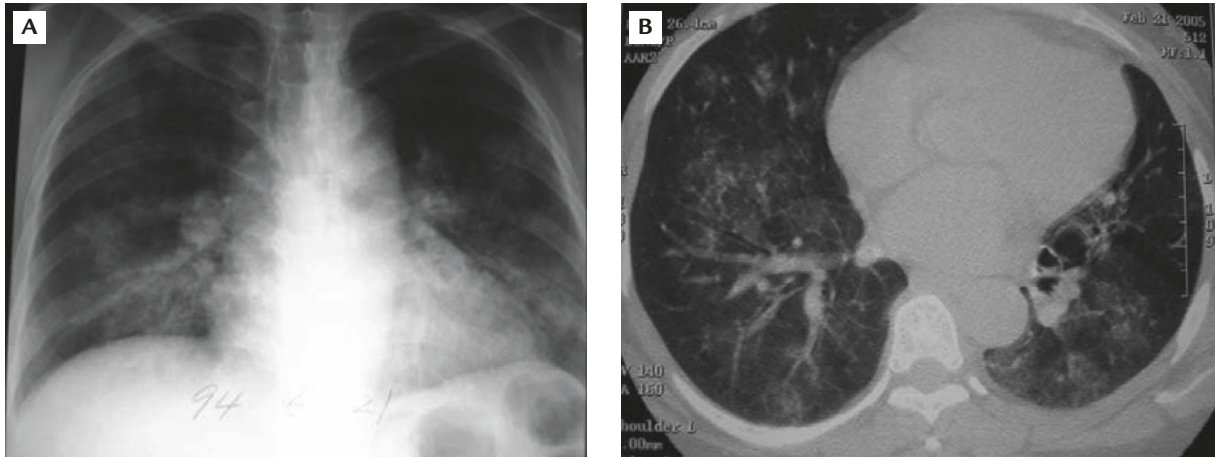


Figure 1. (A) Chest radiography shows bilateral lower lobe consolidation. (B) Chest computed tomography shows multiple patches of ground-glass infiltrates in both lung fields.

in bilateral lower lungs (Figure 1A). Chest computed tomography showed multiple patches of ground-glass infiltrates in both lungs (Figure 1B). Repeated sputum smear revealed no tuberculosis bacilli. Blood C3 and C4 levels were within normal limits. Antinuclear antibody was negative (1:40 \times). The symptoms improved spontaneously, and the patient was discharged 4 days later.

On June 24, 2005, she was again hospitalized for recurring hemoptysis. Chest radiography showed diffuse alveolar infiltrates as noted previously. Peripheral blood examination revealed microcytic hypochromic anemia, with hemoglobin of 8.1 g/dL, mean corpuscular volume of 67.5 fL, mean corpuscular hemoglobin of 19.5 pg, and mean corpuscular hemoglobin concentration of 28.8 g/dL. Serum iron, total iron-binding capacity, ferritin and transferrin levels were not checked. Bronchoscopy disclosed normal bronchial mucosa without active bleeding. Transbronchial biopsy was performed. Pathologic findings were alveolar hemorrhage and extravasation of red blood cells with hemosiderin-laden macrophages in the alveolar spaces. The iron-laden macrophages were confirmed by iron stain using Perl's technique (Figure 2). Blood anti-glomerular basement membrane (anti-GBM) antibody and antineutrophil cytoplasmic antibody (ANCA) were negative. IPH was diagnosed by excluding other glomerular, cardiac and immunological disorders. As in the previous clinical course, the symptoms and chest roentgenographic lesions resolved spontaneously.

She suffered two further episodes of hemoptysis in September and December 2005. A daily dose of 20 mg prednisolone was started on December 8, 2005 and tapered to 10 mg/day 1 month later. The patient currently remains on steroid therapy, and no further episodes of hemoptysis have occurred.

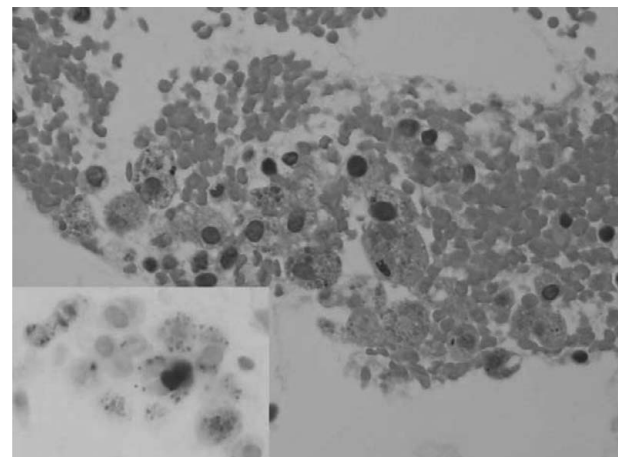


Figure 2. Lung tissue shows hemorrhage and aggregates of hemosiderin-laden macrophages (hematoxylin & eosin, 400 \times). Many Prussian blue ferric ferrocyanide particles can be seen in the hemosiderin-laden macrophages (inset: iron stain, 400 \times).

Discussion

Diffuse alveolar hemorrhage represents a medical emergency and requires an expedient method of identification. The many causes of diffuse alveolar hemorrhage include congenital anomaly, vasculitis, immunologic diseases such as Goodpasture's syndrome, collagen vascular diseases and idiopathic conditions.²⁻⁶ In some patients, an intensive search for a specific etiology ends up negative. Such cases are presently classified as IPH.²

IPH is a disease of unknown etiology that normally occurs in infancy or childhood. The disease is characterized by the triad of hemoptysis, pulmonary infiltrates on chest radiograph and iron deficiency anemia. The course of the disease is variable, independent of age and gender, and may involve spontaneous remission.

The pulmonary hemorrhage may be clinically insignificant or it may be massive with early death. Mean survival after diagnosis is 2.5–5 years.^{2,3} Anemia may be the only presenting feature of IPH, which is due to occult pulmonary hemorrhage.⁷ A report by Yao et al described 5 cases of IPH treated over a 25-year period.⁸ The classic IPH triad was noted at initial presentation in only 2 of the 5 patients. The clinical course of IPH was exceedingly variable; the mean delay before diagnosis was 9 months. Maintaining a high degree of clinical suspicion and including the disease in the differential diagnoses are mandatory. The case reported herein was not promptly diagnosed, probably because IPH is extremely rare in adult patients.

Initial corticosteroid treatment may be effective in some pediatric patients.^{7,9} Kiper et al reported 23 cases of pediatric IPH who were treated with corticosteroids administered in doses ranging from 5 mg every other day to 2 mg/kg daily, depending on the severity of the episodes.⁹ The duration of disease was 2–14 years. They concluded that their IPH patients benefited from long-term steroid treatment, which in turn resulted in a milder course. Long-term low-dose steroid treatment apparently minimized medical crises and assured prolonged survival.⁹ In most reported cases, an immunosuppressive agent is included in maintenance therapy to prevent recurrence.^{8,10–12} Yao et al reported recurrent bleeding episodes in 4 of 5 patients given corticosteroids alone.⁸ All 5 patients required immunosuppressive therapy to achieve symptom-free status. Saeed et al speculated that long-term immunosuppressive therapy may improve the prognosis.¹² Prolonged treatment with corticosteroids or immunosuppressive agents often produces significant side effects. Tutor and Eid reported the successful treatment of an IPH patient by using inhaled flunisolide.¹³ However, the time of inhaled steroid treatment and follow-up were not long enough to allow a conclusion to be drawn with regard to the effect of inhaled steroid treatment on IPH.

Children and adolescents are likely to exhibit a rapid disease course and poor prognosis. In adults, the course is often prolonged, with less severe symptoms and a more favorable prognosis.¹⁴ Most adult IPH patients respond well to corticosteroids.¹⁵ Some authors recommend a more effective therapy by using azathioprine in combination with prednisolone.^{1,16} Hanip et al reported a young female IPH patient who required assisted ventilation. She failed to respond to corticosteroids and was oxygen-dependent until she succumbed to the illness 2 years after initial presentation.¹⁷

The presence of serum ANCA may have prognostic value. Blanco et al, in a retrospective 4-year study of

ANCA in 4 children with IPH, reported findings of ANCA-positive sera in 3 of the 4 patients.¹⁸ In the same study, he also noted that the patient with the highest titer of ANCA had the worst prognosis. The case reported herein had a negative ANCA. Active anti-GBM disease may be absent of circulating anti-GBM antibodies. Renal biopsy with immunofluorescent studies or follow-up blood anti-GBM antibody should be considered in the diagnostic evaluation of subjects with diffuse pulmonary hemorrhage, including those with IPH.¹⁹ Regular follow-up of blood anti-GBM antibody is recommended for cases similar to that reported here.

References

- Loachimescu OC, Sieber S, Kotch A. Idiopathic pulmonary hemosiderosis revisited. *Eur Respir J* 2004;24:162–70.
- Albelda SM, Geftter WB, Epstein DM, Miller WT. Diffuse pulmonary hemorrhage: a review and classification. *Radiology* 1985;154:289–97.
- Collard HR, Schwarz MI. Diffuse alveolar hemorrhage. *Clin Chest Med* 2004;25:583–92.
- Lin YM, Liang KW, Ting CT. Unilateral pulmonary artery agenesis with presentation of hemoptysis: a case report. *J Chin Med Assoc* 1999;62:644–7.
- Cheng WE, Chen CH, Tao CW, Chern MS, Yuen KH, Perng RP. Anomalous systemic arterial supply to normal basilar segments of the left lower lobe of the lung: a case report. *J Chin Med Assoc* 1994;53:248–52.
- Lin CH, Lin CT, Chen CY, Peng HC, Chen HC, Wang PY. Pulmonary sequestration. *J Chin Med Assoc* 1994;53:168–72.
- Chen KC, Hsiao CC, Huang SC, Ko SF, Niu CK. Anemia as the sole presenting symptom of idiopathic pulmonary hemosiderosis: report of two cases. *Chang Gung Med J* 2004;27:824–9.
- Yao TC, Hung IJ, Wong KS, Huang JL, Niu CK. Idiopathic pulmonary haemosiderosis: an Oriental experience. *J Paediatr Child Health* 2003;39:27–30.
- Kiper N, Gocmen A, Ozcelik U, Dilber E, Anadol D. Long-term clinical course of patients with idiopathic pulmonary hemosiderosis (1979–1994): prolonged survival with low-dose corticosteroid therapy. *Pediatr Pulmonol* 1999;27:180–4.
- Chiu JH, Wong KS, Hsia SH, Lai SH. Idiopathic pulmonary hemosiderosis in a child: report of one case. *Acta Paediatr Tw* 2001;42:101–4.
- Huang SH, Lee PY, Niu CK. Treatment of pediatric idiopathic pulmonary hemosiderosis with low-dose cyclophosphamide. *Ann Pharmacother* 2003;37:1618–21.
- Saeed MM, Woo MS, MacLaughlin EF, Margetis MF, Keens TG. Prognosis in pediatric idiopathic pulmonary hemosiderosis. *Chest* 1999;116:721–5.
- Tutor JD, Eid NS. Treatment of idiopathic pulmonary hemosiderosis with inhaled flunisolide. *South Med J* 1995;88:984–6.
- Milman N, Pedersen FM. Idiopathic pulmonary haemosiderosis: epidemiology, pathologic aspects and diagnosis. *Respir Med* 1998;92:902–7.
- Soto RG, Soares MM. Idiopathic pulmonary hemosiderosis in pregnancy: anesthetic implications. *J Clin Anesth* 2005;17:482–4.

16. Airaghi L, Ciceri L, Giannini S, Ferrero S, Meroni PL, Tedeschi A. Idiopathic pulmonary hemosiderosis in an adult: favourable response to azathioprine. *Monaldi Arch Chest Dis* 2001;56:211-3.
17. Hanip MR, Isa MR, Zainudin BM. Idiopathic pulmonary haemosiderosis occurring in a Malaysian patient. *Singapore Med J* 1994;35:535-7.
18. Blanco A, Solis P, Gomez S, Valbuena C, Telleria JJ. Antineutrophil cytoplasmic antibodies (ANCA) in idiopathic pulmonary hemosiderosis. *Pediatr Allergy Immunol* 1994;5: 235-9.
19. Serisier DJ, Wong RCW, Armstrong JD. Alveolar haemorrhage in anti-glomerular basement membrane disease without detectable antibodies by conventional assays. *Thorax* 2006;61:636-9.