

# Adult Bochdalek Hernia with Bowel Incarceration

Yeh-Huang Hung<sup>1</sup>, Yu-Hon Chien<sup>2\*</sup>, Sheng-Lei Yan<sup>1</sup>, Ming-Feng Chen<sup>1</sup>

<sup>1</sup>*Division of Gastroenterology and Hepatology, Department of Internal Medicine, Chang Bing Show Chwan Hospital, and*

<sup>2</sup>*Department of Internal Medicine, Chang Bing Show Chwan Hospital, Chunghua, Taiwan, R.O.C.*

Bochdalek hernias are rare in adults. We report 2 cases of Bochdalek hernia with bowel obstruction. The first case was a 74-year-old male patient who suffered from abdominal pain and chest tightness for 1 day. Chest radiography indicated a mass-like lesion above the left diaphragm. The pain could not be relieved by nasogastric tube decompression for 12 hours. We arranged computed tomography, which revealed a dilated bowel above the diaphragm and intestinal obstruction with gangrenous change. The patient received emergency laparotomy, and a Bochdalek hernia was detected during the operation. The second case was a 75-year-old female patient who suffered from chest tightness and dyspnea for about 1 week. Chest X-ray and magnetic resonance imaging revealed herniation of small and large bowels at the right posterior aspect of the thoracic cavity. She received transthoracic repair of diaphragmatic hernia, recovered, and was discharged 15 days later. We recommend that adult Bochdalek hernia should be considered in the differential diagnosis of bowel obstruction. [*J Chin Med Assoc* 2008;71(10):528–531]

**Key Words:** bowel, hernia, laparotomy

## Introduction

Bochdalek hernia is usually diagnosed in the neonatal period. Its presence in adults is very rare.<sup>1</sup> Bochdalek hernia is the result of a congenital defect in the posterior costal part of the diaphragm in the region of the 10<sup>th</sup> and 11<sup>th</sup> ribs, which allows free communication between the thoracic and abdominal cavities.<sup>2,3</sup> Small Bochdalek hernias may remain undiagnosed until adulthood. A Bochdalek hernia is an infrequent, asymptomatic condition discovered incidentally during routine radiologic examinations.<sup>4</sup> In this report, we present 2 cases with intestinal obstruction caused by an incarcerated bowel through Bochdalek hernia.

## Case Reports

### Case 1

This 74-year-old male patient had a past history of essential hypertension for many years. He had suffered from abdominal pain and chest tightness over the left side of his chest suddenly since the early morning of July 20, 2005. The dull abdominal pain occurred in

the epigastric area, and was mildly relieved when sitting in the prone position. The left chest pain occurred without radiation to the shoulder, arm and cold sweating. The bowel sounds had become louder along with a tinkling sound.

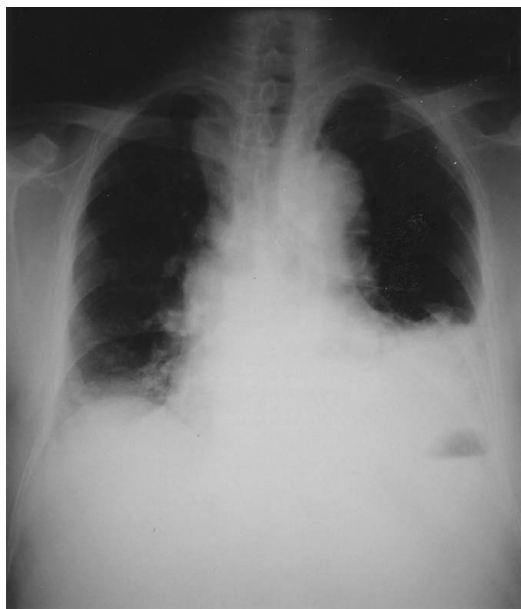Chest radiography demonstrated a non-homogeneous opacity in the left hemithorax, and gas-fluid levels in the stomach (Figure 1). Abdominal radiographs taken in the upright position showed multiple gas retention in the bowel. Laboratory data revealed: hemoglobin level of 16.3 g/dL, white blood cell count of 17,750/mm<sup>3</sup>, segments 68%, and platelet count of 263,000/mm<sup>3</sup>. Blood amylase, lipase, nitrogen, creatinine, and electrolytes were within normal limits. We inserted a nasogastric tube, which drained a lot of bile, but the pain was not relieved after decompression for more than 12 hours. Thus, we arranged for a computed tomography (CT) scan, which revealed a dilated loop of the bowel above the diaphragm. Intestinal obstruction with gangrenous change and diaphragmatic hernia were diagnosed (Figure 2).

The patient received an emergency laparotomy, during which a Bochdalek hernia was found with diaphragm defect, 3 × 3 cm in size, with an irregular margin on

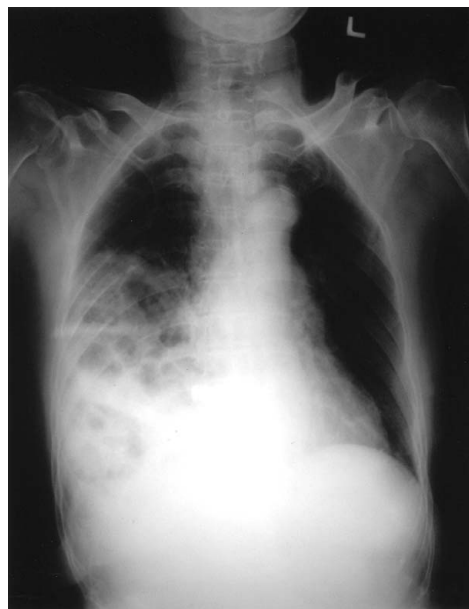

\*Correspondence to: Dr Yu-Hon Chien, Department of Internal Medicine, Chang Bing Show Chwan Hospital, 6, Lugong Road, Lukang Zhen, Changhua 505, Taiwan, R.O.C.

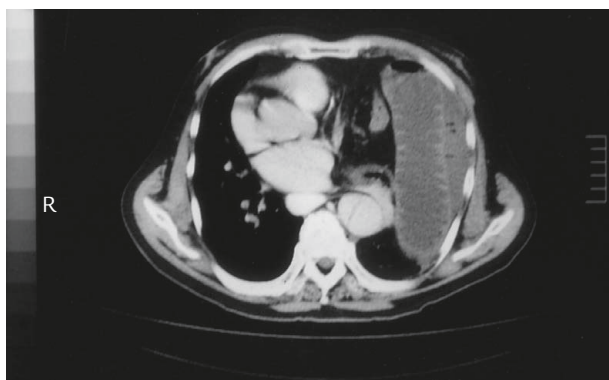
E-mail: [hyhseven@yahoo.com.tw](mailto:hyhseven@yahoo.com.tw) • Received: January 18, 2008 • Accepted: May 15, 2008



**Figure 1.** Chest X-ray of Case 1 shows non-homogeneous opacity in the left hemithorax and gas-fluid levels in the stomach.



**Figure 3.** Chest X-ray of Case 2 shows a hyperdense lesion containing bowel gas in the right pleural space.



**Figure 2.** Computed tomography scan of Case 1 demonstrates dilatation of the bowel above the diaphragm.

the left posterior-lateral side of the diaphragm. Above the diaphragm, the small intestine was affected with gangrenous change on the area 50 cm distal to the Treitz ligament. The omentum and part of the transverse colon were pushed upward. Surgical intervention included relief of the pressure, segmental resection of the involved portion of the small intestine, end-to-end anastomosis of the bowel, and repair of the diaphragm defect. The patient recovered well and was discharged 18 days later after operation.

### Case 2

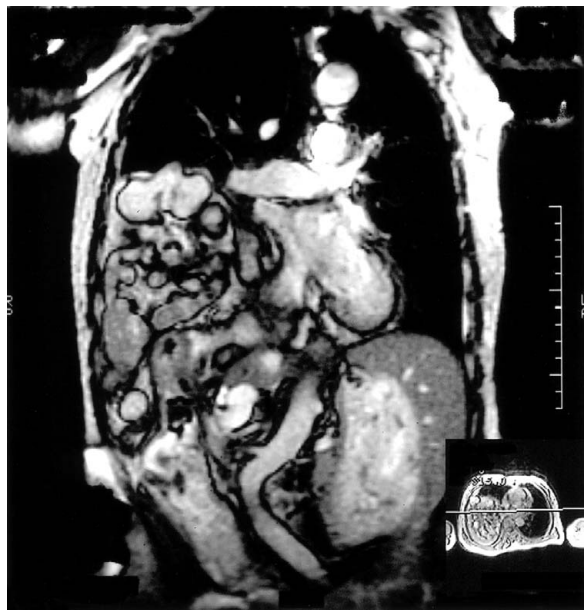The second case was a 75-year-old female patient with a history of chronic renal failure. She suffered from chest tightness and dyspnea for about 1 week, and called at our emergency room on June 29, 2005. The symptoms

occurred with cough, palpitation, abdominal fullness and dullness, but no local abdominal tenderness, right upper abdominal pain, rebounding pain, chest radiation pain, cold sweat, or lower leg edema during this period. She denied any recent traumatic history. Chest X-ray revealed 1 hyperdense lesion in the right thoracic cavity (Figure 3). Laboratory data were: hemoglobin level of 8.9 g/dL, white blood cell count of 6,400/mm<sup>3</sup>, segments 66%, and platelet count of 131,000/mm<sup>3</sup>. Blood urea nitrogen was 49 mg/dL (normal range, 8–20 mg/dL) and creatinine was 4.5 mg/dL (normal range, 0.7–1.5 mg/dL); both were above normal due to chronic renal failure. Electrolytes were within normal limits. The symptoms were not relieved after supportive care that included nasogastric tube decompression and prokinetic drug and intravenous fluid infusion.

We arranged chest magnetic resonance imaging (MRI) and found herniation of the small and large bowels up to the right posterior aspect of the thoracic cavity across a focal posterior diaphragmatic defect (Figure 4). The patient received transthoracic repair of the diaphragmatic hernia and reinforcement with prolene mesh, and was discharged 15 days later.

### Discussion

The incidence of congenital diaphragmatic hernia is approximately 1 in 4,000 live births.<sup>1</sup> The first description of gross anatomy associated with congenital



**Figure 4.** Magnetic resonance imaging of Case 2 shows herniation of small and large bowels in the right thoracic cavity.

diaphragmatic hernia in a newborn baby was reported by McCauley in 1754. Bochdalek hernia was first reported by Victor Alexander Bochdalek in 1848. The Bochdalek hernia is secondary to incomplete development of the pleuroperitoneal folds or improper or absent migration of the diaphragmatic muscle. These canals are normally closed by the pleuroperitoneal membranes in the 8<sup>th</sup> week of gestation. Failure to close leads to Bochdalek hernia. The foramen of Bochdalek hernia is usually a 2-cm slit in the diaphragm, just superior to the adrenal gland.

The detection of congenital diaphragmatic hernia may be missed because of intermittent herniation of the abdominal viscera into the thoracic cavity.<sup>5</sup> The positive pressure gradient, existing between the peritoneal and pleural spaces with a range of 7 to 20 cm H<sub>2</sub>O, may facilitate the herniation of abdominal viscera through a diaphragm rupture.<sup>6</sup> Other factors, including trauma, severe strain and obesity, can also increase abdominal pressure.<sup>7</sup> The bowel loop is herniated through the diaphragmatic defect. If the herniation is present from the time of birth, it is termed “congenital”. However, when the herniation forms later, resulting from the extension of intra-abdominal or perirenal fat into the thorax, it is termed “acquired”.<sup>8</sup>

The symptoms are varied. It is typically manifested by breathlessness, recurrent chest infections, and an absence of breath sounds in the thoracic region. In adults, gastrointestinal symptoms related to the obstruction of the herniated organ are more commonly seen, such as abdominal pain, intestinal obstruction, or chest

tightness.<sup>9</sup> There are various studies noting the contents of left-sided diaphragmatic hernias, which include colon, stomach, omentum, spleen, small bowel, pancreas and adrenal gland. However, the documented contents of right-sided hernias have been limited to the liver, gallbladder, kidneys and omentum.<sup>10</sup> Small Bochdalek hernias, which are posterolateral congenital diaphragmatic defects without symptoms, may remain undiagnosed until adulthood.

Bochdalek hernias are usually diagnosed on routine chest radiography. Frontal and lateral chest radiographs are the most important tools for diagnosis. Most Bochdalek hernias appear as gas-filled bowel loops or a soft tissue mass above the dome of the diaphragm. However, if the herniation is intermittent, the radiographs may be normal. In addition, Bochdalek hernia may be mistaken for left middle lobe collapse, pneumonic consolidation, pericardial fat pad, pericardial cyst, sequestration of the lung, mediastinal lipoma, or anterior mediastinal mass.<sup>7</sup>

Chest CT may directly visualize the focal defect and facilitate definite diagnosis of the hernia or other chest mass.<sup>8</sup> CT findings of diaphragm defect include intrathoracic herniation of the abdominal viscera or omentum through the defect, and thickening of the diaphragm or crus as a result of edema or hematoma.<sup>11,12</sup> Helical CT has been proven to be valuable in the detection of diaphragmatic injuries, with a sensitivity of 71%, a specificity of 100%, and an accuracy of 88% for left-sided injuries and 70% for right-sided injuries.<sup>13</sup> In our first patient, the chest radiographs and CT scan demonstrated the diaphragmatic hernia and ischemic dilated bowel above the diaphragm.

MRI can obtain a direct coronal and sagittal image to visualize the entire diaphragm, as in our second case. The T1-weighted sequence of the diaphragm hernia shows an abrupt defect in low signal intensity of the hemidiaphragm, and herniation of the abdominal viscus or omentum.<sup>14</sup>

Transabdominal and transthoracic approaches have been recommended in Bochdalek hernia repair. The abdominal approach is easily performed through an upper abdominal incision, when the patient has findings suggesting intestinal strangulation. The signs of intestinal obstruction and strangulation in our cases warranted an approach with a midline incision. We performed a midline laparotomy to approach the acute abdominal symptoms of the first patient. If the bowel does not show gangrenous change, transthoracic repair of diaphragmatic hernia is easier than midline laparotomy.<sup>10</sup>

In conclusion, even though Bochdalek hernia is rare in adults, frontal chest radiography is the most

important diagnostic tool. We should pay attention to the patient with unusual abdominal pain or a soft tissue mass above the dome of the diaphragm. CT and MRI are also valuable in detecting Bochdalek hernia and obstructive bowel lesion.

## References

1. Oldham KT, Colombani PM, Foglia RP. Congenital diaphragmatic hernia. In: Stolar CJ, ed. *Surgery of Infants and Children. Scientific Principles and Practice*. Philadelphia: JB Lippincott, 1997:883–95.
2. Marleta R. Diaphragmatic anomalies. In: Raffensperger JG, ed. *Swenson's Textbook of Paediatric Surgery*, 5<sup>th</sup> edition. New York: Appleton and Lange, 1990:721–35.
3. Kearney PA, Rouhana SW, Burnay RE. Blunt rupture of the diaphragm: mechanism, diagnosis, and treatment. *Ann Emerg Med* 1989;18:1326–30.
4. Mullins ME, Saini S. Imaging of incidental Bochdalek hernia. *Semin Ultrasound CT MR* 2005;26:28–36.
5. Eren S, Kantarci M, Okur A. Imaging of diaphragmatic rupture after trauma. *Clin Radiol* 2006;61:467–77.
6. Shanmuganathan K, Killeen K, Mirvis SE, White CS. Imaging of diaphragmatic injuries. *J Thorac Imaging* 2000;15:104–11.
7. Irish MS, Holm BA, Glick PL. Congenital diaphragmatic hernia: historical review. *Clin Perinatol* 1996;23:625–53.
8. Mullins ME, Stein J, Saini SS, Mueller PR. Prevalence of incidental Bochdalek's hernia in a large adult population. *AJR Am J Roentgenol* 2001;177:363–6.
9. Asensio JA, Demetriades D, Rodriguez A. Injury to the diaphragm. In: Mattock KL, Feliciano DU, Moore EE, eds. *Trauma*. New York: McGraw Hill, 1999:603–31.
10. Kapur B, Thomas S. Adult Bochdalek hernia: clinical features, management and results of treatment. *Jpn J Surg* 1991;21:114–9.
11. Eren S, Ciris F. Diaphragmatic hernia: diagnostic approaches with review of the literature. *Eur J Radiol* 2005;54:448–59.
12. Yen CH, Chen JD, Tui CM, Chou YH, Lee CH, Chang CY, Yu C. Internal hernia: computed tomography diagnosis and differentiation from adhesive small bowel obstruction. *J Chin Med Assoc* 2005;68:21–8.
13. Nchimi A, Szapiro D, Ghaye B, Willems V, Khamis J, Haquet L, Noukoua C, et al. Helical CT of blunt diaphragmatic rupture. *AJR Am J Roentgenol* 2005;184:24–30.
14. Shanmuganathan K, Mirvis SE, White CS, Pomerantz SM. MR imaging evaluation of hemidiaphragms in acute blunt trauma: experience with 16 patients. *AJR Am J Roentgenol* 1996;167:397–402.