

***Pneumocystis jiroveci* Pneumonia in Patients with Non-Hodgkin's Lymphoma Receiving Chemotherapy Containing Rituximab**

Hung Chang^{1,4*}, Hwei-Chung Yeh², Yung-Cheng Su¹, Ming-Hsun Lee^{3,4}

¹Division of Hematology-Oncology, ²Department of Gastroenterology and Hepatology, and ³Division of Infectious Diseases, Department of Internal Medicine, Chang Gung Memorial Hospital, Taipei, and

⁴Chang Gung University College of Medicine, Taoyuan Taiwan, R.O.C.

Rituximab enhances treatment efficacy of B-lineage lymphoma by targeting CD20⁺ B-cells. Such target therapies may compromise the immune system and render patients susceptible to opportunistic infections. We report 2 cases of lymphoma complicated with *Pneumocystis jiroveci* (previously known as *P. carinii*) pneumonia (PCP) while being treated with rituximab-containing chemotherapy regimens. In both cases, PCP developed during the neutropenic period. With timely diagnosis and proper management, both were treated successfully. We searched the literature and found that such opportunistic infection occurred only infrequently in lymphoma patients, and it has not been reported in the large-scale clinical trials of rituximab. Such cases demonstrate the importance of taking PCP into diagnostic consideration in lymphoma patients receiving similar therapies. [*J Chin Med Assoc* 2008;71(11):579–582]

Key Words: febrile neutropenia, lymphoma, opportunistic infection, *Pneumocystis jiroveci*, rituximab

Introduction

Rituximab is a monoclonal antibody which enhances the treatment efficacy of B-lineage lymphomas.^{1,2} It may be associated with compromise of immunity and subsequent opportunistic infections.^{3,4} *Pneumocystis jiroveci* (previously known as *P. carinii*) pneumonia (PCP) may occur in a wide range of hematologic diseases, notably lymphomas.^{5–7} In lymphomas, its incidence appears to be related to treatment intensity.⁸ With the standard regimen of cyclophosphamide, doxorubicin, vincristine and prednisolone (CHOP) with or without rituximab, such an opportunistic infection occurs infrequently. However, PCP can be possibly overlooked, so the true incidence is obscure. The present published guidelines for empirical therapy for febrile neutropenic patients do not include PCP in the early assessment,^{9,10} which may potentially cause delay in its diagnosis. In this report, we present 2 cases with PCP that occurred after chemotherapy containing rituximab, and discuss the importance of clinical alertness in the neutropenic period.

Case Reports

Case 1

A 45-year-old female was diagnosed with follicular lymphoma, grade I, in December 2005. The tumor was in stage IV_A, with bone marrow involvement. She received chemotherapy with CHOP, consisting of: cyclophosphamide 750 mg/m², day 1; doxorubicin 50 mg/m², day 1; vincristine 2 mg, day 1; and prednisolone 100 mg/day for 5 days. The same regimen was repeated in 3 weeks. Severe neutropenia (white blood cell count [WBC] 1,900/mm³ and absolute neutrophil count 437/mm³) and digital paresthesia occurred following chemotherapy, although there was no overt infection. Doxorubicin was omitted in the 3rd cycle of chemotherapy. Rituximab 375 mg/m² was added to the treatment (R-CHOP). Only 75% of doxorubicin was given in the 4th, 5th and 6th cycles.

On April 19, 2006, after 3 cycles of R-CHOP and a total of 6 cycles of chemotherapy, the patient was admitted with fever. She also complained of cough with scant sputum and mild substernal chest pain. Physical



*Correspondence to: Dr Hung Chang, Division of Hematology-Oncology, Department of Internal Medicine, Chang Gung Memorial Hospital, 5, Fu-Shing Street, Kweishan, Taoyuan 333, Taiwan, R.O.C.
E-mail: Hung.Chang@umassmed.edu • Received: October 22, 2007 • Accepted: June 9, 2008

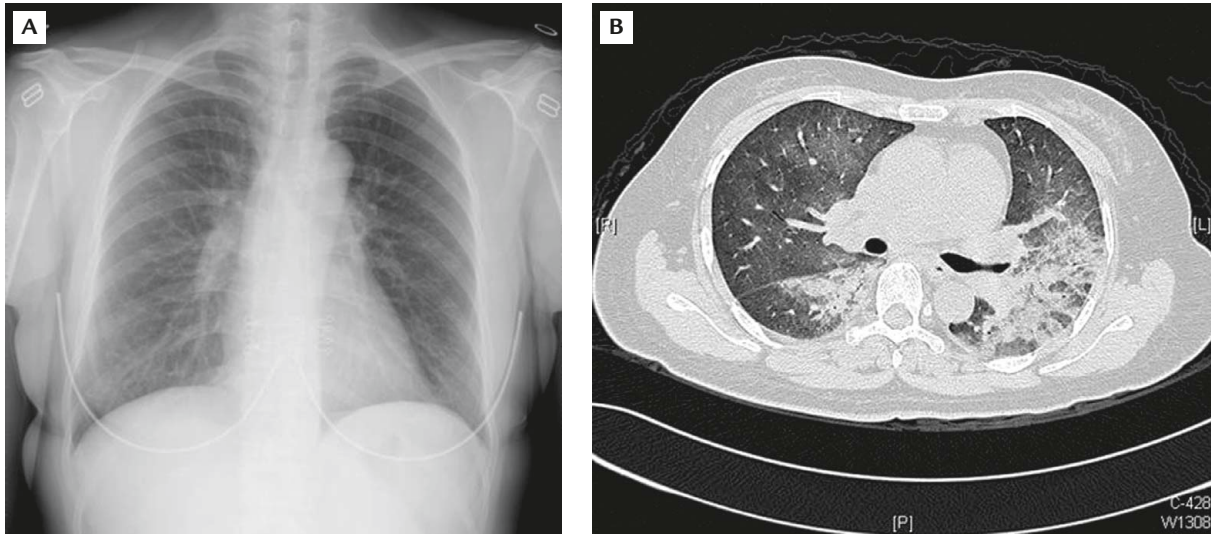


Figure 1. (A) Chest X-ray of Case 1 shows some ground glass appearance in the left lung and right lower lung fields. (B) High-resolution computed tomography shows patchy consolidation of bilateral perihilar areas.

examination did not show remarkable findings. Laboratory data showed hemoglobin of 12.8 g/dL, platelets of $208,000/\text{mm}^3$, and WBC of $1,300/\text{mm}^3$ with 83% neutrophils, 5% monocytes, 2% eosinophils, 9% lymphocytes and 1% basophils. Biochemistry profile showed normal liver and renal functions. Initial chest film showed only slightly exaggerated lung markings. The patient was treated with ciprofloxacin 300 mg intravenous infusion every 12 hours. The fever persisted, and chest X-ray taken 3 days later revealed some ground glass appearance in the left lung and right lower lung fields (Figure 1A). A high-resolution computed tomography (HRCT) scan the next day disclosed patchy consolidation of bilateral perihilar areas (Figure 1B). The patient did not receive bronchoscopy, and no sputum was available for microbiologic examination.

As PCP was suspected, treatment with trimethoprim-sulfamethoxazole (TMP-SMX) was given at a dose of TMP 5 mg/kg every 6 hours. Fever subsided 2 days after starting TMP-SMX. The treatment was continued for 21 days. Adjunctive steroid was used for 10 days and then tapered off. Follow-up chest film showed a normal result, and the patient was discharged after completing the treatment course for PCP. Another 2 cycles of rituximab plus chemotherapy were given. The dose of doxorubicin was further reduced to 66% in the 7th cycle and omitted in the 8th cycle. No prophylaxis for PCP was given, and she had no further complications.

Case 2

A 45-year-old housewife was diagnosed with extranodal marginal zone B-cell lymphoma with diffuse large

cell transformation in March 2006. The tumor was in stage II_{EA}, with involvement of the stomach and regional lymph nodes. The patient was a hepatitis B carrier, and lamivudine was given as prophylaxis for hepatitis B flare up. She received chemotherapy with CHOP. Neutropenic fever occurred following the first cycle of chemotherapy. Further chemotherapy was given every 3 weeks with dose reduction. Rituximab $375\text{ mg}/\text{m}^2$ was added to the treatment (R-CHOP) starting from the 3rd cycle of chemotherapy. Due to recurrent severe neutropenia after each cycle of treatment, doxorubicin was omitted in the 6th cycle of chemotherapy on June 26, 2006.

Neutropenic fever developed on July 11 (WBC $2,000/\text{mm}^3$) and she also had mild dry cough. Physical examination showed mild tachypnea (respiratory rate of 28/min) but otherwise unremarkable findings. The initial chest film showed slightly exaggerated lung markings. The patient was treated with ceftriaxone 1 g intravenous injection every 12 hours for 3 days. As the fever persisted, treatment was changed to flomoxef. Chest film was followed-up 6 days later, revealing ground glass appearance in the left lung field (Figure 2A). HRCT scan on the same day revealed slight thickening of the interlobular septa and intralobular interstitium in the left lung with multifocal ground glass opacities (Figure 2B).

Gomori's methenamine silver nitrate stain of the bronchoalveolar fluid detected the existence of *P. jiroveci* in the lungs. Treatment with TMP-SMX at a dose of TMP 5 mg/kg every 6 hours was instituted, and the fever subsided the following day. Seven days after starting TMP-SMX, WBC decreased to $1,900/\text{mm}^3$

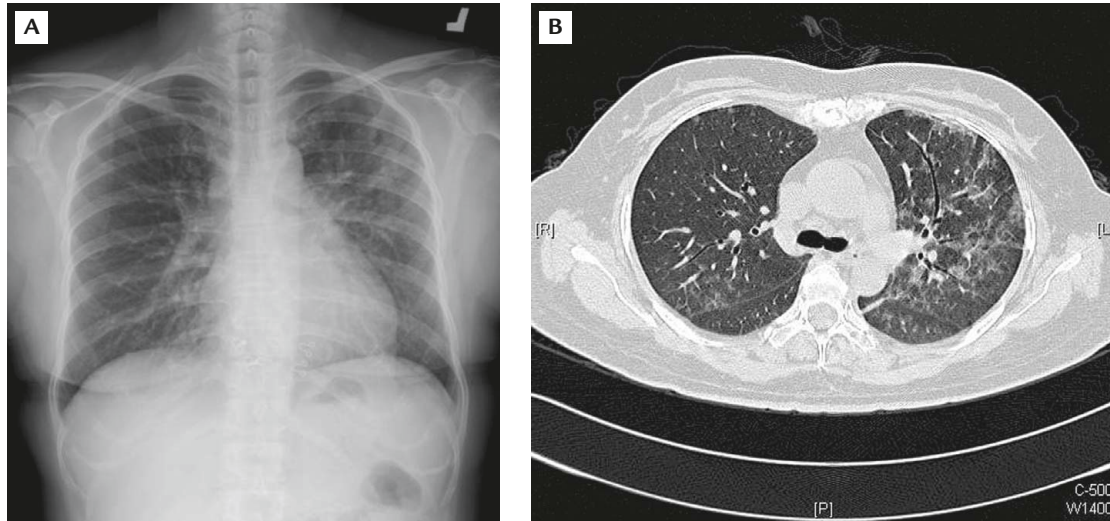


Figure 2. (A) Chest X-ray of Case 2 shows ground glass appearance in the left lung field. (B) High-resolution computed tomography reveals slight thickening of the interlobular septa and intralobular interstitium in the left lung with multifocal ground glass opacities.

with 1% myelocytes, 82% neutrophils, 8% monocytes, 1% eosinophils and 8% lymphocytes. Follow-up chest film showed no more infiltrates. TMP-SMX was replaced with clindamycin 600 mg intravenous infusion every 8 hours for suspected TMP-SMX-related neutropenia. The treatment was continued for a total of 21 days. No prophylaxis for PCP was given following complete treatment. Two more cycles of R-CHOP were given without further complications.

Discussion

PCP is an opportunistic infection occurring in immunocompromised hosts such as those with acquired immunodeficiency syndrome (AIDS) or recipients of organ transplantations. PCP may occur in a variety of hematologic diseases, including non-Hodgkin's lymphoma, chronic lymphocytic leukemia, acute leukemias, chronic myeloid leukemia, multiple myeloma, myelodysplastic syndrome, Hodgkin's disease and thrombocytopenia.⁵⁻⁷ Stem cell transplantation is by far the most immunocompromised state among hematologic diseases.¹¹ Such patients usually receive TMP-SMX prophylaxis. The incidence of PCP in such a prophylactic setting is low.¹¹ For patients treated with conventional chemotherapy, non-Hodgkin's lymphoma is the most common malignancy associated with such opportunistic infections.⁵⁻⁷ It has been well demonstrated that chemotherapy used for lymphoma may cause severe and prolonged depression of CD4 cell counts and levels of immunoglobulin G.¹² In some intensive treatment modalities, PCP occurs so frequently that routine prophylaxis is recommended.^{8,13}

Compared with infection caused by other pathogens, PCP can be significantly overlooked, especially in the presence of neutropenia. The treatment guidelines for empirical therapy of febrile neutropenia do not include treatment for PCP in the early phase.^{9,10} As PCP patients frequently have hypoxemia, failure to recognize early PCP may result in unfavorable outcomes. Both of our cases developed PCP in the setting of febrile neutropenia. Both received broad-spectrum antibiotics as the initial empirical treatment. With clinical alertness, the diagnosis of PCP was suspected by chest films taken 3 and 6 days after the onset of fever. In both cases, diagnosis was supported by HRCT on the same day that the chest film was taken. Specific treatment of PCP was also initiated on the same day.

Bronchoalveolar lavage cytology was performed in Case 2, confirming the diagnosis by Gomori's methenamine silver nitrate stain. Our experience demonstrated that PCP should be listed in the differential diagnoses of febrile neutropenia in patients with hematologic diseases, especially lymphoma. Early evaluation for PCP should also be considered in the treatment guidelines for such patients. As for treatment, although TMP-SMX is effective in the majority of cases, it may be intolerable due to gastrointestinal upset, allergic reactions or bone marrow suppression. In such conditions, clindamycin/primaquine is an alternative therapy,^{14,15} as illustrated by the use of clindamycin in Case 2 (primaquine was not available in our ward at that time).

Rituximab is a chimeric monoclonal antibody directed against CD20. Used in conjunction with conventional chemotherapy, it increases the treatment efficacy of B-lineage lymphomas.^{1,2} On the other hand, it may cause immunosuppression, rendering patients

prone to infection by microorganisms such as fungi and cytomegalovirus.^{3,4}

In the clinical trials done by Coiffier et al, 197 patients aged between 60 and 80 years received treatment with CHOP, while 202 patients received R-CHOP. In the R-CHOP arm, there were 12 cases with grade 3 to 4 infection and 8 cases of lung toxicity, but no case with frank PCP was reported.¹ Another controlled randomized trial enrolled 824 patients between 18 and 60 years of age. No case with frank PCP was reported in either arm.¹ Whether or not PCP prophylaxis was given to the enrolled cases was not described, but it can be shown that PCP is rare during such treatment courses. On the other hand, in more intensive treatment, patients were given R-CHOP at a 2-week interval; 7 interstitial pneumonitis and 3 documented PCP cases occurred among 50 patients.⁸ It was also demonstrated that occurrence of PCP was correlated with hypogammaglobulinemia.⁸ It reflected that immunosuppression may be more profound during more intensive treatment and the likelihood for developing opportunistic infection higher. Since rituximab suppresses CD20⁺ lymphocytes and leads to hypogammaglobulinemia, it will add to the potential risk of PCP or other opportunistic infections.

In clinical practice, PCP can be easily overlooked in patients treated with conventional regimens. In the absence of routine prophylaxis with TMP-SMX, the true incidence is not shown in any large-scale studies. Our cases received chemotherapy containing rituximab at the conventional 3- to 4-week intervals. PCP was not reported in previous clinical trials that used treatment of similar intensity. It is hoped that this report will draw attention to this opportunistic infection. As early diagnosis and proper treatment are important, clinicians should be highly alert to such complications. Although the guidelines for febrile neutropenia do not include PCP in the early assessment, PCP should be considered in the early phase of febrile neutropenia in patients with hematologic malignancies. Prophylaxis with TMP-SMX may be warranted if more studies showing the occurrence of PCP are available in the future.

References

1. Coiffier B, Lepage E, Briere J, Herbrecht R, Tilly H, Bouabdallah R, Morel P, et al. CHOP chemotherapy plus rituximab compared

- with CHOP alone in elderly patients with diffuse large B-cell lymphoma. *N Engl J Med* 2002;346:235–42.
2. Pfreundschuh M, Trumper L, Osterborg A, Pettengell R, Trnecny M, Imrie K, Ma D, et al. CHOP-like chemotherapy plus rituximab versus CHOP-like chemotherapy alone in young patients with good-prognosis diffuse large B-cell lymphoma: a randomised controlled trial by the MabThera International Trial (MInT) Group. *Lancet Oncol* 2006;7:379–91.
3. Lin PC, Hsiao LT, Poh SB, Wang WS, Yen CC, Chao TC, Liu JH, et al. Higher fungal infection rate in elderly patients (more than 80 years old) suffering from diffuse large B cell lymphoma and treated with rituximab plus CHOP. *Ann Hematol* 2007; 86:95–100.
4. Unluturk U, Aksoy S, Yonem O, Bayraktar Y, Tekuzman G. Cytomegalovirus gastritis after rituximab treatment in a non-Hodgkin's lymphoma patient. *World J Gastroenterol* 2006;12: 1978–9.
5. Roblot F, Le MG, Godet C, Hutin P, Texereau M, Boyer E, Prazuck T, et al. *Pneumocystis carinii* pneumonia in patients with hematologic malignancies: a descriptive study. *J Infect* 2003; 47:19–27.
6. Pagano L, Fianchi L, Mele L, Girmenia C, Offidani M, Ricci P, Mitra ME, et al. *Pneumocystis carinii* pneumonia in patients with malignant haematological diseases: 10 years' experience of infection in GIMEMA centres. *Br J Haematol* 2002;117:379–86.
7. Barbounis V, Aperis G, Gambletsas E, Koumakis G, Demiris M, Vassilomanolakis M, Efremidis A. *Pneumocystis carinii* pneumonia in patients with solid tumors and lymphomas: predisposing factors and outcome. *Anticancer Res* 2005;25:651–5.
8. Brusamolino E, Rusconi C, Montalbetti L, Gargantini L, Uziel L, Pinotti G, Fava S, et al. Dose-dense R-CHOP-14 supported by pegfilgrastim in patients with diffuse large B-cell lymphoma: a phase II study of feasibility and toxicity. *Haematologica* 2006; 91:496–502.
9. Hughes WT, Armstrong D, Bodey GP, Brown AE, Edwards JE, Feld R, Pizzo P, et al. 1997 guidelines for the use of antimicrobial agents in neutropenic patients with unexplained fever. Infectious Diseases Society of America. *Clin Infect Dis* 1997; 25:551–73.
10. Guidelines for the use of antimicrobial agents in patients with febrile neutropenia in Taiwan. *J Microbiol Immunol Infect* 2005;38:455–7.
11. Tuan IZ, Dennison D, Weisdorf DJ. *Pneumocystis carinii* pneumonia following bone marrow transplantation. *Bone Marrow Transplant* 1992;10:267–72.
12. Tsimberidou AM, Younes A, Romaguera J, Hagemester FB, Rodriguez MA, Feng L, Ayala A, et al. Immunosuppression and infectious complications in patients with stage IV indolent lymphoma treated with a fludarabine, mitoxantrone, and dexamethasone regimen. *Cancer* 2005;104:345–53.
13. McLaughlin P, Hagemester FB, Romaguera JE, Sarris AH, Pate O, Younes A, Swan F, et al. Fludarabine, mitoxantrone, and dexamethasone: an effective new regimen for indolent lymphoma. *J Clin Oncol* 1996;14:1262–8.
14. Korraa H, Saadeh C. Options in the management of pneumonia caused by *Pneumocystis carinii* in patients with acquired immune deficiency syndrome and intolerance to trimethoprim/sulfamethoxazole. *South Med J* 1996;89:272–7.
15. Noskin GA, Murphy RL, Black JR, Phair JP. Salvage therapy with clindamycin/primaquine for *Pneumocystis carinii* pneumonia. *Clin Infect Dis* 1992;14:183–8.