

Alveolar Rhabdomyosarcoma of the Left Hand with Bilateral Breast Metastases in an Adolescent Female

Geok-Chin Tan^{1*}, Mohd-Sidik Shiran², Abdul-Rahman Hayati¹, Noor-Akmal Sharifah¹,
Aida-Selamat Nurul³, Mohammad Rohaizak⁴

Departments of ¹Pathology, ³Radiology and ⁴Surgery, Faculty of Medicine, Universiti Kebangsaan, Kuala Lumpur, and ²Department of Pathology, Faculty of Medicine and Health Sciences, Universiti Putra Malaysia, Serdang, Malaysia.

Rhabdomyosarcoma is a common extramammary malignancy in pediatric age groups, but it rarely metastasizes to the breast. Breast rhabdomyosarcomas are commonly metastatic, with possible primary locations at the head and neck, trunk, extremities, retroperitoneum and perianal region. We report a case of primary alveolar rhabdomyosarcoma of the upper extremities in a 17-year-old adolescent female who presented with bilateral lower limb weakness and bilateral breast lumps. [*J Chin Med Assoc* 2008;71(12):639–642]

Key Words: adolescence, breast, metastasis, rhabdomyosarcoma

Introduction

Rhabdomyosarcoma accounts for approximately 4% of all childhood malignancies. Metastasis to the breast from extramammary malignancies is rare, with an incidence of 2–6%,¹ but its recognition is important. The common metastatic diseases of the breast include lymphoma, malignant melanoma and carcinoma. A metastatic lesion must be distinguished from primary breast cancer because the treatment and prognosis are quite different. Histology is mostly alveolar type, and the primary tumor is usually located in the extremities. Disseminated disease is frequently accompanied by breast metastasis.²

Case Report

A 17-year-old female presented to the National University Hospital with a 2-month history of intermittent low back pain, associated with bilateral lower limb weakness. She also complained of difficulty in

defecation and passing urine. She noticed a hard, rounded lump on the dorsum of her left hand which had slowly been increasing in size for the past 2 months. It was painless and there was no history of trauma. There was a positive family history of breast cancer.

Physical examination revealed loss of pinprick sensation from the abdomen downwards. Bilateral breast lumps were found during breast examination. A firm, ill-defined, mobile and nontender right breast mass was noted at the 10 o'clock position, which measured 0.7 × 0.7 cm. There were multiple left breast masses in the upper and lower inner quadrants measuring from 0.5 cm to 1.5 cm in diameter; these masses were also firm in consistency, nontender and mobile. There was no axillary lymph node palpable. A provisional diagnosis of primary breast cancer metastasis to the spine was made.

MRI of the thoracic spine (Figure 1)

There were compression fractures of the T8, L2 and L4 vertebrae. Lobulated anterolateral paravertebral masses



*Correspondence to: Dr Geok-Chin Tan, Department of Pathology, Faculty of Medicine, Hospital Universiti Kebangsaan Malaysia, Jalan Yaacob Latif, Bandar Tun Razak, 56000 Cheras, Kuala Lumpur, Malaysia.
E-mail: tan_geok_chin@yahoo.com • Received: January 21, 2008 • Accepted: July 14, 2008

were seen on the T2, T8, L2 and L4 vertebrae. These lesions appeared to envelope the vertebral bodies at T2 with intraspinal extension, which was seen to compress the spinal cord and occupy both intervertebral foraminae. These findings were consistent with multilevel vertebral compression with paraspinal masses and intraspinal extension, which were likely to be metastases. In addition, there were 2 nodules seen on the antero-basal and laterobasal segments of the right lower lobe, suggestive of lung metastasis.

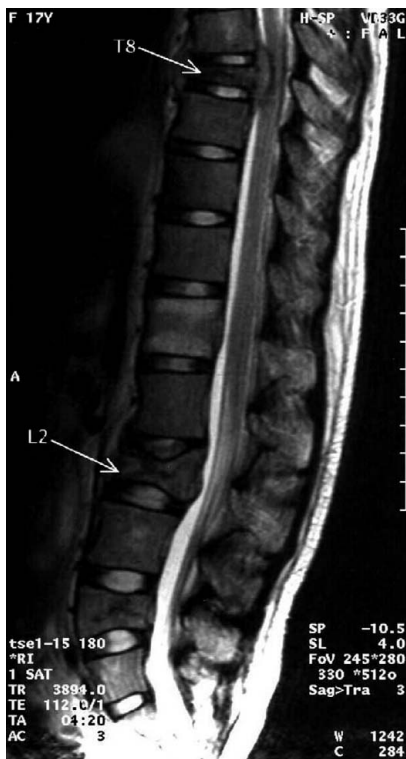


Figure 1. Magnetic resonance imaging of the thoracic spine shows T8, L2 and L4 vertebrae compression fractures with spinal cord involvement.

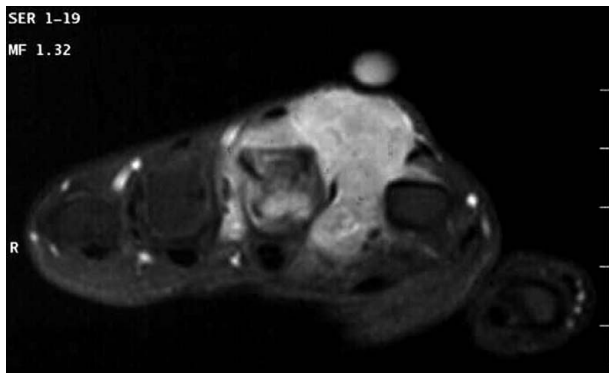


Figure 2. A mass arose from the dorsal and palmar interossei and occupied both the dorsal and palmar compartments of the hand.

MRI of the left hand (Figure 2)

There was a mass occupying both the dorsal and palmar compartments of the hand, which arose from the muscles of the dorsal and palmar interossei. The cortex on the radial aspect of the third metacarpal appeared to be thinned out, with a focal area of dehiscence. The mass was isointense to the surrounding muscles on T1WI and hyperintense to the muscles on T2WI. Marked homogeneous enhancement was demonstrated after gadolinium injection. These findings suggested a malignant soft tissue mass that most likely originated from the interossei muscle and infiltrated the third metacarpal.

Pathologic findings

Fine needle aspiration cytology of the breasts

Both right and left breast lumps showed similar features: highly cellular smears of poorly differentiated malignant cells displaying hyperchromatic, pleomorphic nuclei with distinct nucleoli and scanty cytoplasm. These cells were arranged in both cohesive groups displaying nuclear moulding and singly distributed in a blood-stained background. A few of the cells showed lobulated and binucleated nuclei. The findings were consistent with a poorly differentiated malignant tumor. A possibility of soft tissue malignancy was suggested, and tissue biopsy was recommended for immunohistochemical study. Excision biopsies of the breast lump and lump on the dorsum of the left hand were performed.

Histopathologic findings

The findings of both breast and upper extremity lumps were similar. The tumor was composed of malignant cells arranged in nests separated by connective tissue septa (Figure 3). Some of the tumor cells remained firmly attached to fibrous strands, but others tended to detach because of a lack of cohesiveness, which resulted in a typical alveolar appearance (Figure 4). The tumor cells had small, round to oval, hyperchromatic nuclei

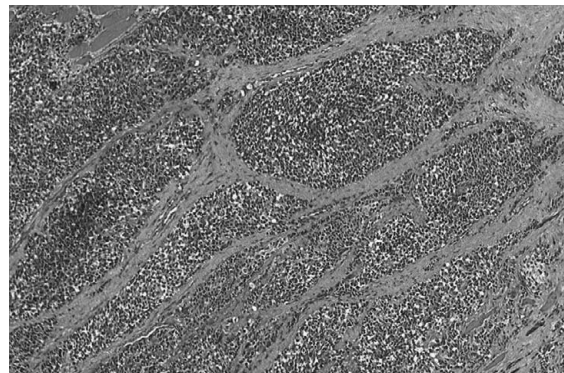

Figure 3. Malignant cells were separated by fibrous septa and formed nests (hematoxylin & eosin, 40 \times).

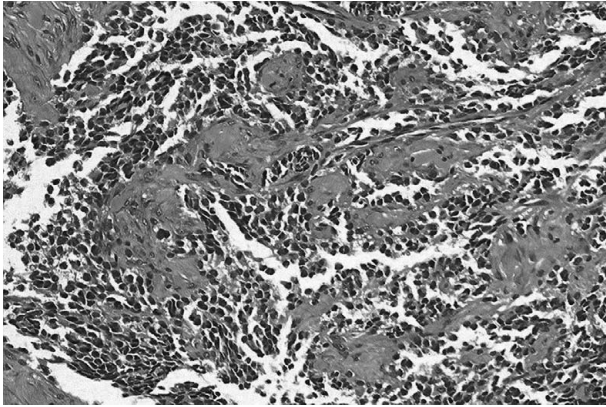


Figure 4. Malignant cells showed lack of cohesiveness, which resulted in a typical alveolar appearance (hematoxylin & eosin, 100×).

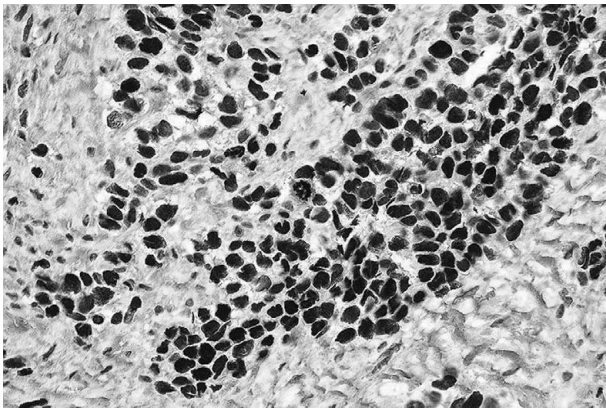


Figure 5. Tumor cells showed nuclear positive reactivity toward MyoD1 (200×).

with scanty eosinophilic cytoplasm. Eight mitoses were counted in 10 high-power fields. Areas of necrosis were also seen in the centers of these cellular aggregates. Multinucleated giant cells were also noted. Immunohistochemically, tumor cells showed diffuse positive reaction for MyoD1 (Figure 5), desmin and vimentin, and negative reaction for smooth muscle actin, cytokeratin, leukocyte common antigen, and CD99. Final diagnosis was alveolar rhabdomyosarcoma of the left hand with metastasis to the breasts, spine and lung.

Postoperatively, the patient received 5 cycles of rhabdomyosarcoma chemotherapy protocol consisting of ifosfamide (1.8 g/m²/day for 5 days) and etoposide (100 mg/m²/day for 5 days). Unfortunately, she succumbed to the disease 6 months later.

Discussion

Rhabdomyosarcoma is a tumor of mesenchymal origin which arises from cells committed to skeletal muscle differentiation. It commonly affects the head and neck

region, the genitourinary tract or the extremities. Metastatic involvement of the breast from an extramammary malignancy is uncommon, with an incidence of 0.8–6.6% in reported series of breast neoplasms. The Intergroup Rhabdomyosarcoma Study reviewed 26 cases of both primary and secondary rhabdomyosarcomas over a period of 20 years and found that 27% were primary and 73% metastatic.³ Other primary tumors that metastasize to the breast include malignant melanoma, lymphoma, leukemia and neuroblastoma.⁴

In 1980, Howarth et al followed-up 108 consecutively diagnosed patients with rhabdomyosarcoma, and found that 6% of them subsequently developed metastatic tumors of the breast. They noted that 85% had alveolar histology, and the patients' gender and age indicated that the physiologic state of the breast was an important determining factor in the development of breast metastases.⁵ Increased vascularity of the breast was thought to be responsible for the development of hematogenous metastases, as most of these patients were younger women.⁶ There was a reported case of metastatic rhabdomyosarcoma to the breast in a pregnant woman, which further supported the hypothesis that vascularity plays a significant role in the hematogenous spread of the disease.⁷

The most common metastatic sites from primary rhabdomyosarcoma are lung, bone, bone marrow and liver. Our patient had metastasis to the breast, lung, bone (spine), and bone marrow. Alveolar rhabdomyosarcoma is the most common histologic type, appearing as malignant, small, round, blue tumor. There are a number of differential diagnoses for this tumor. Hence, tissue biopsy together with immunohistochemical study is mandatory for a definitive diagnosis.

The distinction of primary mammary malignancy from extramammary malignancies metastatic to the breast is important for patient management. In patients with breast metastasis, the prognosis is generally poor because most of them have widely disseminated disease. In these patients, systemic treatment or palliative care is more appropriate than extensive surgery. A histopathologist should provide an accurate diagnosis and prevent unnecessary surgery.

References

1. Birjawi GA, Haddad MC, Tawil AN, Khoury NJ. Metastatic rhabdomyosarcoma to the breast. *Eur Radiol* 2001;11:555–8.
2. Rosen PP. *Rosen's Breast Pathology*, 2nd edition. Philadelphia: Lippincott Williams & Wilkins, 2001:823.
3. Hays DM, Donaldson SS, Shimada H, Crist WM, Newton WA Jr, Andrassy RJ, Wiener E, et al. Primary and metastatic rhabdomyosarcoma in the breast: neoplasms of adolescent females.

- A report from the Intergroup Rhabdomyosarcoma Study. *Med Pediatr Oncol* 1997;29:181-9.
4. Boorthroyd A, Carty H. Breast masses in childhood and adolescence. *Pediatr Radiol* 1994;24:81-4.
 5. Howarth CB, Caces JN, Pratt CB. Breast metastases in children with rhabdomyosarcoma. *Cancer* 1980;46:2520-4.
 6. Hajdu SI, Urban JA. Cancers metastatic to the breast. *Cancer* 1972;29:1691-6.
 7. Yaren A, Guclu A, Sen N, Erdem E, Demirkan F. Breast metastasis in a pregnant woman with alveolar rhabdomyosarcoma of the upper extremity. *Eur J Obstet Gynecol Reprod Biol* 2008;140:131-3.