

# Prenatal Diagnosis of Extrastructurally Abnormal Chromosomes: Clinical Experience and Literature Review

Jenn-Jhy Tseng<sup>1,2,3,4\*</sup>, Min-Min Chou<sup>1</sup>, Feng-Chu Lo<sup>1</sup>, Hui-Yu Lai<sup>1</sup>, Min-Hui Chen<sup>1</sup>, Esther Shih-Chu Ho<sup>1</sup>

<sup>1</sup>Department of Obstetrics and Gynecology, Taichung Veterans General Hospital, <sup>2</sup>Department of Nursing, Hung-Kuang University, <sup>3</sup>Department of Obstetrics and Gynecology, China Medical University, Taichung, and <sup>4</sup>Institute of Clinical Medicine, National Yang-Ming University School of Medicine, Taipei, Taiwan, R.O.C.

**Background:** To evaluate the clinical association of extrastructurally abnormal chromosomes (ESACs) with pregnancy outcome based on the cytogenetic characteristics of the ESACs.

**Methods:** We retrospectively reviewed 12 ESAC cases identified from 12,991 cases who received genetic amniocentesis between January 1983 and March 2008. Prenatal ultrasound findings, characteristics of ESACs (karyotypes, special features, origin, inheritance) and pregnancy outcomes were recorded.

**Results:** The prenatal prevalence of ESACs was 0.092% (12/12,991). Of the 12 ESAC cases, all were *de novo*. Seven (58.3%) originated from nonacrocentric chromosomes and the other 5 (41.7%) were from acrocentric chromosomes, with 3 originating from chromosome 15. Six of the 12 cases (50%) were large ESACs; however, the other 6 (50%) were medium to small ESACs. All acrocentric ESACs contained dicentric and bisatellite characteristics. Using FISH and SKY techniques, the origins of 2 cases (patients 10 and 12) were clearly identified to be from chromosomes 15 and 10, respectively. Five of the 12 ESAC cases (41.7%) had congenital anomalies found by prenatal ultrasound. All were nonacrocentric in origin that were medium (1/5) to large (4/5) in size. After prenatal genetic counseling, 8 of the 12 (66.7%) couples opted to terminate the pregnancy. The other 4 (33.3%) continued the pregnancy and their babies were delivered at term normally and were followed-up, with normal development ranging from 2 to 17 years.

**Conclusion:** With sophisticated cytogenetic characterization and ultrasound examination, it is possible to precisely categorize most fetuses with ESACs as being either at high risk of abnormality or at a relatively low risk. [*J Chin Med Assoc* 2009;72(1):29–33]

**Key Words:** extrastructurally abnormal chromosome, genetic counseling, prenatal diagnosis

## Introduction

Extrastructurally abnormal chromosomes (ESACs) are a heterogeneous group. They have been described variously as markers, supernumeraries, accessories, and B-chromosomes.<sup>1</sup> Some are harmless and are associated with phenotypic normality (the B-chromosome), but others may pose a risk for the fetus. ESACs are encountered in about 1 in 1,000 prenatal diagnoses, frequently in the mosaic state with a normal cell line.<sup>1–5</sup> More than 50% of ESACs are acrocentric in origin, and *idic(15)*, commonly referred to as *inv dup(15)*, is the most

common type.<sup>4</sup> Owing to their diverse origin and variable euchromatin content, the phenotypes associated with ESACs vary significantly. This variability poses a great dilemma for genetic counselors when an ESAC is detected during prenatal diagnosis because prediction of the pregnancy outcome is difficult. Warburton reported 123 occurrences of prenatally diagnosed ESAC cases and estimated that the phenotypic risk associated with acrocentric origin was 10.9% and that with nonacrocentric origin was 14.7%.<sup>6</sup> Recently, the contribution of molecular cytogenetic analyses (e.g. fluorescence *in situ* hybridization [FISH] and spectral



\*Correspondence to: Dr Jenn-Jhy Tseng, Department of Obstetrics and Gynecology, Taichung Veterans General Hospital, 160, Section 3, Taichung-Kang Road, Taichung 407, Taiwan, R.O.C.  
E-mail: t1018@vghtc.gov.tw • Received: May 14, 2008 • Accepted: December 17, 2008

karyotyping [SKY]) have offered the possibility of rapid identification of the origin and nature of ESACs, which improves the prediction of clinical outcome during prenatal genetic counseling.

In this study, we retrospectively reviewed cases of ESACs detected prenatally in our institution between January 1983 and March 2008, and attempted to evaluate the clinical association of the ESACs with clinical outcomes based on the cytogenetic characteristics of the ESACs. A review of the relevant literature was also done.

## Methods

We retrospectively checked all cases who received amniocentesis and reviewed the 12 ESAC cases we found in Taichung Veterans General Hospital during the period between January 1983 and March 2008.

*In situ* amniotic fluid cell culture, harvest, and Giemsa-banding technique were performed according to the standard protocols. Twenty primary colonies were examined by standard analyses. If the available number of the colonies was fewer than 20, a total of 20 cells from both primary and trypsinized cultures were examined. True mosaicism was defined as abnormal cell lines with ESACs present in at least 2 independent cultures. Special stains, including C- and NOR-bands, were applied to each ESAC case. Additional studies performed with the fluorescent dye DPAI (4',6-diamidino-2-phenylindole) and SRY gene (sex-determining region on the Y chromosome) were individualized. Parents' karyotypes were determined in order to identify *de novo* or familial inheritance of the ESACs. In comparison with the long arm of chromosome 21 (21q), the ESACs were categorized as small (<1/2 21q), medium, or large (>21q).

FISH and/or SKY were performed in 2 recent cases (nos. 10 and 12 in Table 1) according to the manufacturer's protocol. For case 10 undergoing FISH, 2 centromeric probes (D15Z1, Vysis, Des Plaines, IL, USA; and D15Z4, Cytocell, Cambridge, UK) and probes for the Prader-Willi syndrome (SNRPN, Vysis) and Angelman syndrome (UBE3A, Cytocell) chromosome regions were adopted. For case 12, multicolor SKY paint and FISH with chromosome-specific alphoid satellite DNA probe for chromosome 10 (CEP10, Gael, Scotland, UK) were done.

Prenatal ultrasound findings were reviewed in all cases. Continuous follow-up was conducted for clinical data regarding pregnancy outcome. Before a decision was made to terminate or continue with the pregnancy, formal counseling was provided by a genetic counselor.

## Results

The prenatal diagnoses of the 12 ESAC cases are summarized in Table 1. The prenatal prevalence of ESACs was 0.092% (12/12,991). These cases comprised 3.17% (12/378) of all chromosomal disorders during the study period. The indications for genetic amniocentesis were advanced maternal age (8/12), fetal anomaly (2/12), parents' anxiety (1/12), and maternal serum test showing high-risk result (1/12). All 12 ESAC cases were *de novo*.

Conventional cytogenetics with G-banding technique showed true mosaicism of ESACs (47,N,+mar/46,N) in 8/12 cases (66.7%). The size of the ESACs in 6/12 cases (50%) was large; however, the other 6 (50%) were medium to small. Seven of the 12 ESACs (58.3%) originated from nonacrocentric chromosomes and the other 5 (41.7%) were derived from acrocentric chromosomes (D/G groups), with 3 originating from chromosome 15. The C- and NOR-banding studies revealed that all acrocentric ESACs contained dicentric and bisatellite characteristics. FISH results showed that case 10 originated from chromosome 15. The presence of signals for the Prader-Willi/Angelman syndrome critical regions (SNRPN and UBE3A) was confirmed (Figure 1). SKY identified the ESAC in case 12 as originating from chromosome 10 (Figure 2).

Five of the 12 ESAC cases (41.7%) had congenital anomalies found by prenatal ultrasound. All of them were from nonacrocentric chromosomes, including 4/5 (80%) with large (cases 2, 4, 6, and 11) and 1/5 (20%) with medium (case 7) ESACs.

Four of the 12 (33.3%) babies were delivered at term normally. They were followed-up, with normal development ranging from 2 to 17 years. After prenatal genetic counseling, 8 of the 12 (66.7%) couples decided to terminate the pregnancy. Of the pregnancies that were terminated, 5 fetuses (cases 2, 4, 6, 7 and 11) had apparent congenital abnormalities found by prenatal ultrasound, 2 (cases 2 and 10) had large-sized ESACs, and 1 (case 9) had 2 different ESACs. There were no gross abnormalities found in the 3 terminated fetuses with unremarkable prenatal sonographic findings. Postnatal investigations using abortus skin tissues and/or umbilical cord blood confirmed the prenatal diagnoses in all 8 terminated cases.

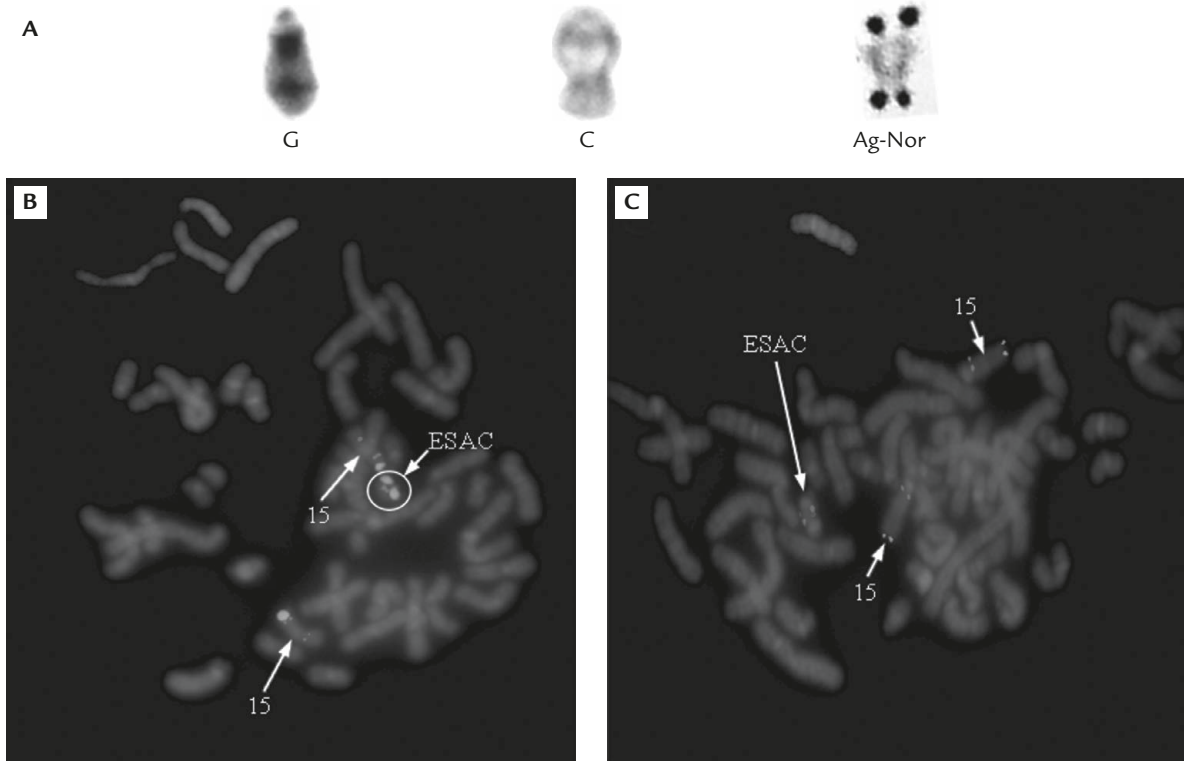
## Discussion

The origin and genetic content (euchromatin or heterochromatin) of ESACs should be investigated.

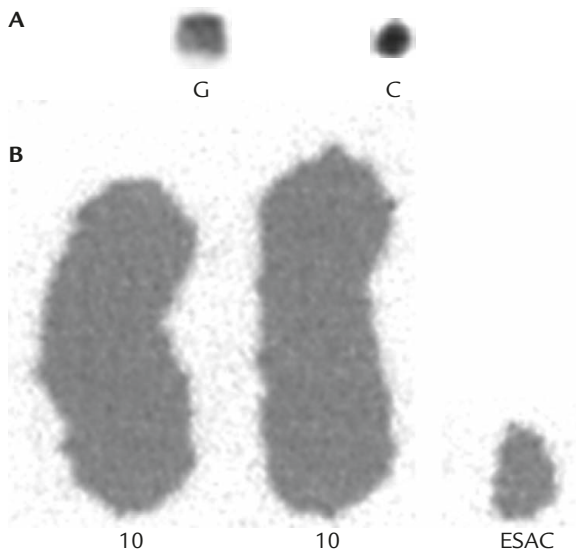
**Table 1.** Prenatal diagnosis of extrastructurally abnormal chromosomes (ESACs) (January 1983 to March 2008)

Case	Indication	US findings	Characteristics of ESACs			Outcome	
			Karyotype	Special features	Origin		Inheritance
1	Parents' anxiety	Unremarkable	47,XY,+mar/46,XY	Medium, dicentric, bisatellite, DAPI(+)	15	De novo	Normal at 17 years old
2	AMA	Unremarkable	47,XY,+mar/46,XY	Large, dicentric, bisatellite, DAPI(-)	D/G group not 15	De novo	Terminated
3	AMA	Unremarkable	47,XY,+mar/46,XY	Medium, dicentric, bisatellite, DAPI(+)	15	De novo	Normal at 16 years old
4	Fetal anomaly	CDH, rhizomelia, polyhydramnios	47,XX,+mar/46,XX	Large, monocentric, nonsatellite	Unknown	De novo	Terminated
5	AMA	Unremarkable	47,XX,+mar	Medium, dicentric, bisatellite, DAPI(-)	D/G group not 15	De novo	Normal at 8 years old
6	Fetal anomaly	CHD, cleft lip, Dandy-Walker malformation	47,XY,+mar	Large, dicentric, nonsatellite	?(9p)	De novo	Terminated
7	AMA	CHD (CAVC)	45,X/46,X,+mar/ 47,XY,+15	Medium, SRY(+), monocentric, nonsatellite	?Y	De novo	Terminated
8	AMA	Dandy-Walker malformation	47,XX,+mar	Large, monocentric, nonsatellite	?9p	De novo	Terminated
9	AMA	Unremarkable	46,X,+mar1/46,X, +mar2/46,X,r(X)	Small to medium, SRY(-), monocentric, nonsatellite	?X	De novo	Terminated
10	AMA	Unremarkable	47,XY,+mar	Large, dicentric, bisatellite, DAPI(+), D15Z1++, D15Z4++, SNRPN+, UBE3A+	15	De novo	Terminated
11	AMA	Hydrops fetalis	47,XY,+mar/46,XY,del (13)(q21.32)	Large, monocentric, nonsatellite	?(16p)	De novo	Terminated
12	DS, high risk	Unremarkable	47,XX,+mar/46,XX	Small, monocentric, nonsatellite, CEP 10+, SKY 10+	10	De novo	Normal at 2 years old

US = prenatal ultrasound; DAPI = 4',6-diamidino-2-phenylindole; AMA = advanced maternal age; CDH = congenital diaphragmatic hernia; CHD = congenital heart disease; CAVC = common atrioventricular canal; SRY = sex-determining region on the Y chromosome; DS = maternal serum Down syndrome screening test.



**Figure 1.** Serial studies of case 10. (A) Partial karyotype of the fetus with G-, C- (dicentric) and Ag-Nor banding (bisatellite). Metaphase FISH studies demonstrate the presence of signals for: (B) Prader-Willi syndrome critical region (SNRPN); (C) Angelman syndrome critical region (UBE3A) of chromosome 15. ESAC = extrastructurally abnormal chromosome.



**Figure 2.** Serial studies of case 12. (A) Partial karyotype of the fetus with G- and C-banding. C-banding discloses that the majority of this extra material is comprised of constitutive heterochromatin. (B) The SKY technique confirms chromosome 10 to be the origin. ESAC = extrastructurally abnormal chromosome.

Traditionally, this requires the use of special stains, including C-bands for constitutive heterochromatin around the centromere and the distal end of the Y chromosome, NOR-bands for the nucleolus organizing

region in the short arms of the acrocentric group (chromosomes 13, 14, 15, 21 and 22), and DAPI for the heterochromatin of chromosomes 9, 15 and Y differentially. Through these studies, we identified 5 acrocentric (dicentric and bisatellite) and 7 non-acrocentric (nonsatellite) ESACs. The origin of 3 acrocentric ESACs from chromosome 15 was confirmed due to the presence of positive DAPI stain (cases 1, 3, and 10); however, the presence of critical regions in these cases cannot be excluded without further evaluations.

With the increasing sophistication of molecular cytogenetics (e.g. FISH and SKY), further precise characterization of ESACs is possible. Therefore, it has become easier to predict the phenotype-genotype correlations of ESACs. In FISH, about 80% are shown to be derived from the acrocentric chromosomes, most commonly from chromosomes 15 or 22, and often involve only the pericentromeric region and the satellites.<sup>7</sup> The SKY technique offers the possibility of rapid identification of the origin and nature of some ESACs.<sup>5</sup> In our study, 2 ESAC cases were investigated further with FISH (case 10) and SKY (case 12). The presence of critical regions (SNRPN+ and UBE3A+) for Prader-Willi/Angelman syndromes in chromosome 15 was confirmed by FISH in case 10. The pregnancy was

therefore terminated. The application of SKY in case 12 showed the origin of ESAC to be chromosome 10. The pregnancy continued to term because this ESAC was small and almost completely comprised of C-band-positive heterochromatic materials. With new modalities to supplant classical cytogenetics, such as array-CGH and chromosome specific-molecular rulers, it will be possible to fully characterize the genetic content and dosage of each ESAC and to potentially describe/predict the clinical phenotype for specific cases.<sup>8</sup> Replication banding is used primarily to identify inactive X chromatin.<sup>5</sup> Therefore, this technique could be used in a case of ESAC originating from the X chromosome to further predict the phenotype.

The unconfirmed origins of the other 8 ESACs in this study were investigated by conventional G-, C-, and NOR-banding techniques. Most of them occurred before the feasibility of FISH or SKY. Some hints were still present. Two acrocentric ESACs (cases 2 and 5) were expressed by negative DAPI stains, hence chromosome 15 was excluded as the origin. The other ESACs may have originated from chromosomes 9p, 16p, X or Y. Nevertheless, conventional techniques could help provide a basis for further investigations with molecular studies. This would effectively shorten the interval between prenatal diagnosis and genetic counseling.

Upon the discovery of an ESAC at prenatal diagnosis, parental chromosomes are required. In principle, a heterochromatic ESAC conveys a low risk, whereas an euchromatic ESAC may imply a high risk for phenotypic abnormality.<sup>6</sup> Given the wide range of cytogenetic heterogeneity, it is not surprising that there should be a wide phenotypic range, including normality.<sup>5</sup> The majority of harmless ESACs comprise acrocentric short arm and pericentromeric material or other autosomal pericentromeric chromatin.<sup>9</sup> Many ESACs are very small and prone to loss during cell division, which results in familial mosaicism.<sup>10</sup> When a parent has the ESAC in mosaic state, prediction for the fetus is more difficult. The chromosome could potentially be harmful, but the parent might be protected by a particular tissue distribution.<sup>11</sup> Mosaicism appears not to alter the risk of abnormality. Furthermore, those in whom fetal ultrasonographic anomaly has been detected are at high risk.

With cytogenetic characterization and prenatal ultrasound examination, it is possible to precisely categorize most fetuses with ESACs as being either at high risk of abnormality or at a relatively low risk.

The information can be clearly conveyed to the parents of affected fetuses by genetic counselors.

## Acknowledgments

This work was supported by a research grant from Taichung Veterans General Hospital (TCVGH-956403C). The assistance of Dr Ming Chen and Dr Chyi-Chyang Lin in the preparation of this manuscript is gratefully acknowledged.

## References

1. Hook EB, Cross PK. Extrastructurally abnormal chromosomes (ESAC) detected at amniocentesis: frequency in approximately 75,000 prenatal cytogenetic diagnosis and association with maternal and paternal age. *Am J Hum Genet* 1987;40:83-101.
2. Benn PA, Hsu LYF. Incidence and significance of supernumerary marker chromosomes in prenatal diagnosis. *Am J Hum Genet* 1984;36:1092-102.
3. Sachs ES, van Hemel JO, den Hollander JC, Jahoda MGJ. Marker chromosomes in a series of 10,000 prenatal diagnoses: cytogenetic and follow-up studies. *Prenat Diagn* 1987;7:81-9.
4. Blennow E, Bui TH, Kristofferson U, Vujic M, Anneren G, Holmberg E, Nordenskjold M. Swedish survey on extra structurally abnormal chromosomes in 39,105 consecutive prenatal diagnoses: prevalence and characterization by fluorescence *in situ* hybridization. *Prenat Diagn* 1994;14:1019-28.
5. Gardner RJM, Sutherland GR. Chromosome abnormalities detected at prenatal diagnosis. In: Gardner RJM, Sutherland GR, eds. *Chromosome Abnormalities and Genetic Counseling*. New York: Oxford University Press, 2004:392-432.
6. Warburton D. *De novo* balanced chromosome rearrangements and extra marker chromosomes identified at prenatal diagnosis: clinical significance and distribution of breakpoints. *Am J Hum Genet* 1991;49:995-1013.
7. Crolla JA. FISH and molecular studies of autosomal supernumerary marker chromosomes excluding those derived from chromosome 15: II. Review of the literature. *Am J Med Genet* 1998;75:367-81.
8. Huang B, Solomon S, Thangavelu M, Peters K, Bhatt S. Supernumerary marker chromosomes detected in 100,000 prenatal diagnoses: molecular cytogenetic studies and clinical significance. *Prenat Diagn* 2006;26:1142-50.
9. Callen DF, Eyre H, Yip MY, Freemantle J, Haan EA. Molecular cytogenetic and clinical studies of 42 patients with marker chromosomes. *Am J Med Genet* 1992;43:709-15.
10. Chudley AE, Zheng HZ, Pabello PD, Shia G, Wang HC. Familial supernumerary microchromosome mosaicism: phenotypic effects and an attempt at characterization. *Am J Med Genet* 1983;16:89-97.
11. Brondum-Nielsen K, Mikkelsen M. A 10-year survey, 1980-1990, of prenatally diagnosed small supernumerary marker chromosomes, identified by FISH analysis: outcome and follow-up of 14 cases diagnosed in a series of 12,699 prenatal samples. *Prenat Diagn* 1995;15:615-9.