

Monostotic Vertebral Paget's Disease of the Lumbar Spine

Lien-Chen Wu, Chun-Hsiung Tseng, Yueh-Feng Chiang, Yang-Hwei Tsuang*
Department of Orthopedic Surgery, Taipei City Hospital, Taipei, Taiwan, R.O.C.

Paget's disease in the Far East is quite rare. Age at diagnosis is usually greater than 50 years, and the disease typically affects the spine. Most patients are usually diagnosed with Paget's disease following radiographic examination for other purposes. It usually occurs at multiple vertebral levels, with only 10–25% of vertebral Paget's disease being monostotic. The disease rarely causes neurologic complications resulting from compression of intraspinal nerve tissue. Here, we present 2 cases of monostotic vertebral Paget's disease of the third lumbar vertebra. The first patient, who may be the first documented case of Paget's disease in the lumbar spine with progressive neurologic deficiency in an Asian population, received decompressive laminectomy due to marked spinal stenosis with neurologic deficits. The symptoms were greatly relieved following surgery, and ambulatory ability was restored. The second patient was diagnosed with Paget's disease following surgical biopsy. He remained asymptomatic at the most recent follow-up. [*J Chin Med Assoc* 2009;72(1):52–55]

Key Words: lumbar vertebra, Paget's disease, spinal stenosis

Introduction

Paget's disease is commonly diagnosed in northern Europe, North America, Australia, and New Zealand, but is rare in the Far East. About 3.7% of individuals of Anglo-Saxon origin older than the age of 55 are afflicted with Paget's disease.^{1–3} This incidence increases with age.

Paget's disease typically affects more than one bone in the body, with the pelvis (15%) and spine (13%) being the most common sites of affliction.^{4,5} The majority of individuals with Paget's disease do not seek medical treatment unless there is associated pain or other related symptoms. Moreover, there are rarely neurologic complications associated with compression of intraspinal nerve tissues.⁵ Here, we present 2 cases of monostotic vertebral Paget's disease of the third lumbar vertebra.

Case Reports

Case 1

This was a 77-year-old woman who presented to our orthopedic clinic with low back pain, bilateral sciatica,

and left leg weakness. The patient had been diagnosed with renal function impairment 10 years previously, and had been receiving regular continuous ambulatory peritoneal dialysis 3 months prior to admission. Paget's disease, with involvement of the third lumbar vertebra (L3), had been suspected for 10 years.

The patient recalled that the first episode of low back pain with right sciatica had occurred approximately 10 years ago. Paget's disease was diagnosed following roentgenographic examination, and injectable calcitonin was then administered for nearly 6 years until the symptoms subsided completely. The response was excellent, but low back pain recurred 2 years later and was again treated with calcitonin. Although the symptoms were again initially controlled, the administration was changed to nasal spray 6 months later due to the occurrence of cold sweats. The response was unsatisfactory this time.

Three months prior to this admission, low back pain and bilateral sciatica developed and worsened daily. Progressive muscle weakness of the left leg was noted, and the patient was unable to stand up without support. On admission, physical examination indicated a positive straight leg raising test of the left leg. Muscle power was grade 4, and hyporeflexia of the knee and ankle



*Correspondence to: Dr Yang-Hwei Tsuang, Department of Orthopedic Surgery, Taipei City Hospital, 145, Zheng Zhou Road, Taipei 103, Taiwan, R.O.C.
 E-mail: tsuang66@ms71.hinet.net • Received: January 22, 2008 • Accepted: August 14, 2008

were also noted. Radiography of the lumbosacral region revealed an enlarged L3 vertebra, consisting of increased anteroposterior and transverse diameters without increase in vertical height (Figure 1). Long bone survey by roentgenographic examination was also performed; no other Pagetic bone lesion was observed. Magnetic resonance imaging (MRI) of the lumbar spine revealed a posterior protrusion of the L3/4 intervertebral disc and L3 vertebral body (Figure 2). Severe spinal canal compromise with approximately 70% reduction of the cross-sectional area was apparent. Alkaline phosphatase levels were found to be 108 U/L (normal range,

45–125 U/L), indicating that osteoblast activity was normal. There had been no significant change in the gross appearance of the L3 vertebra as determined by roentgenographic analysis over the preceding 2-year period. We assumed that the patient was in the osteosclerotic phase of Paget's disease with lumbar stenosis. Therefore, surgical intervention for posterior decompression was scheduled.

Posterior decompression with total laminectomy of L3 was performed. Obvious hypertrophy of the L3 lamina and hypertrophic spondyloarthropathy of the L2/3 and L3/4 facet joints were apparent. The bone was relatively hard, with coarse trabeculation. Central and lateral spinal stenoses were a consequence of the posteriorly expanded vertebral body and bulged L3/4 disc from the anterior aspect, and hypertrophic lamina and facet joints from behind. Histologic examination revealed irregular Pagetic bone plates with a mosaic pattern (Figure 3). There was absence of osteoblastic or osteoclastic activity, and no evidence of fibrovascular proliferation in the marrow space. Osteosclerotic phase of Paget's disease was confirmed.

The postoperative course was uneventful; the symptoms of low back pain and bilateral sciatica were greatly relieved following surgery. The patient's ambulatory ability improved daily, and walking distance increased. After discharge, the patient received nasal spray calcitonin and regular sessions of rehabilitation. Residual mild low back pain persisted for several months. Unfortunately, the patient died approximately 8 months after surgery due to aspiration pneumonia and septic shock.

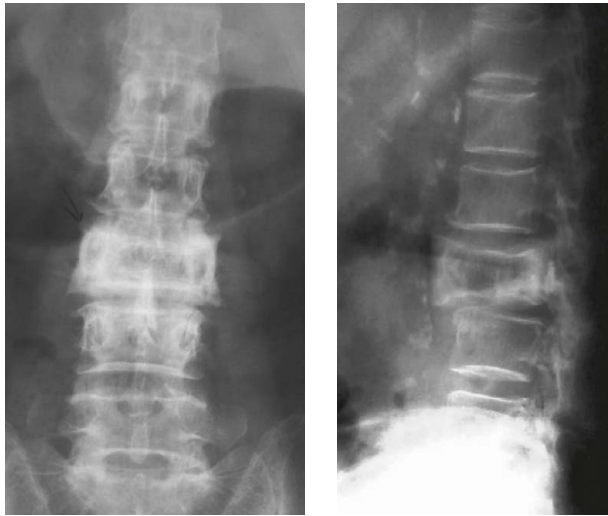

Figure 1. Anteroposterior and lateral radiographs of Case 1. Note the "picture frame" appearance of the L3 vertebral body.

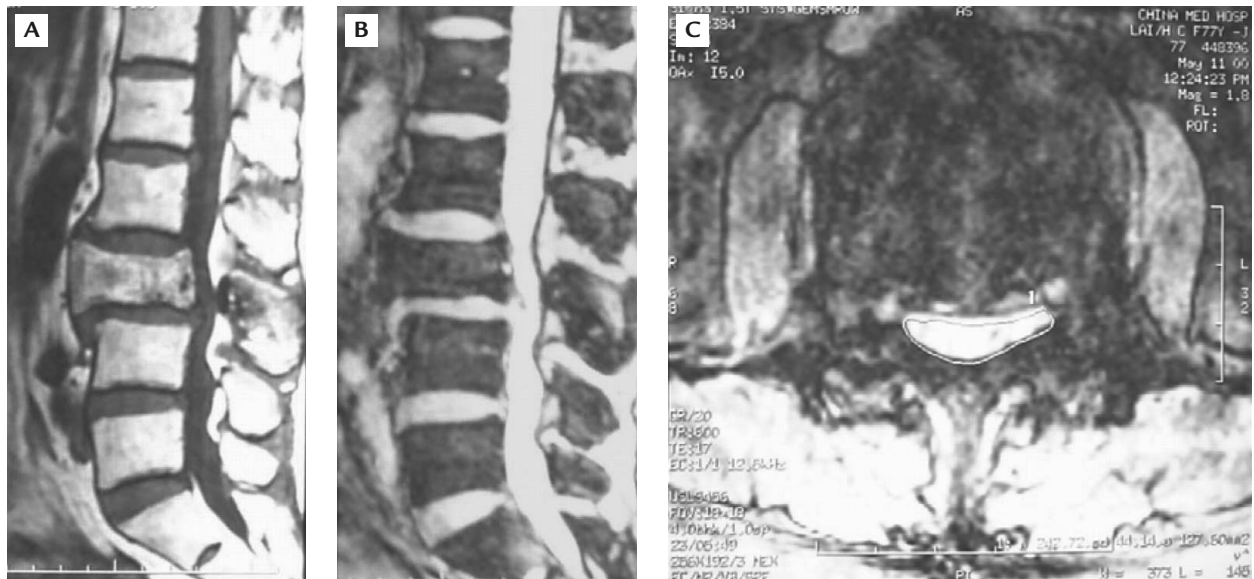


Figure 2. Magnetic resonance imaging: (A) sagittal plane; (B) axial plane. Both show focal stenosis of the spinal canal and compression of the dura sac at the level of the L3 vertebra. (C) Axial view centered on the L3 vertebra: note the severe spinal canal compromise with reduction of the cross-sectional area of about 70%.

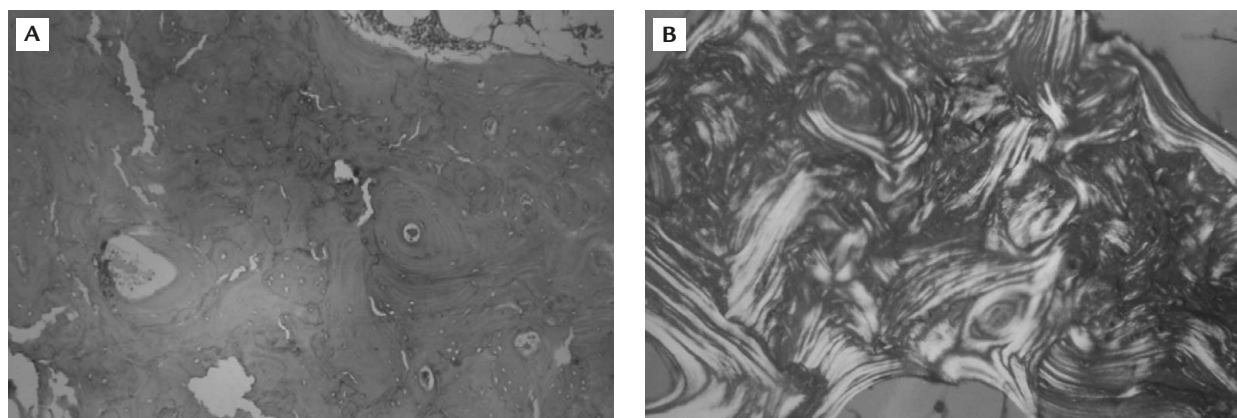


Figure 3. Bone specimen of Case 1. (A) Bone biopsy shows irregular Pagetic bone plates (hematoxylin & eosin, 100 \times). (B) Increased irregular cement line forming a mosaic pattern (hematoxylin & eosin under polarized light, 200 \times).

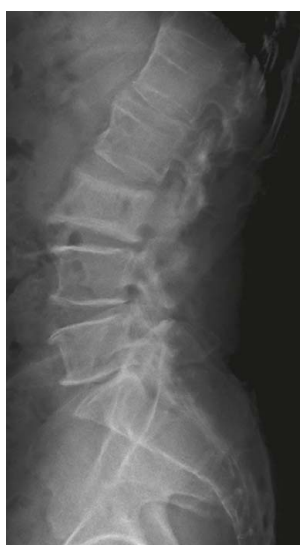
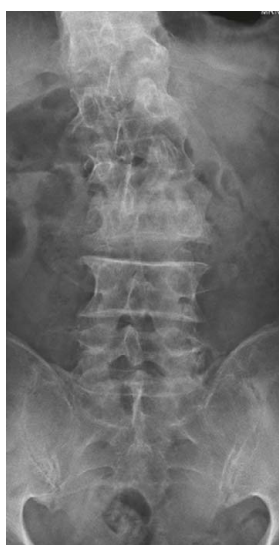
Figure 4. Anteroposterior and lateral radiographs of the lumbosacral spine of Case 2 also shows a “picture frame” appearance of the L3 vertebral body.

Case 2

This was a 59-year-old male who presented with mild numbness over his bilateral iliac region. Physical examination did not reveal any obvious neurologic deficiency. Radiography of the lumbosacral spine showed an osteosclerotic L3 vertebra with increased anteroposterior and transverse diameters (Figure 4). MRI of the lumbar region was performed and the sclerotic lesion was confirmed. Radionuclide bone scan revealed increased uptake at the L3 and left fourth rib areas. With a differential diagnosis of Paget’s disease or sclerotic metastases, the patient was hospitalized for biopsy and further assessment.

Alkaline phosphatase level was 510 U/L on admission. Histologic examination revealed a mosaic bone plate pattern, with an increased number of osteoclasts. There was no evidence of malignancy in the specimen

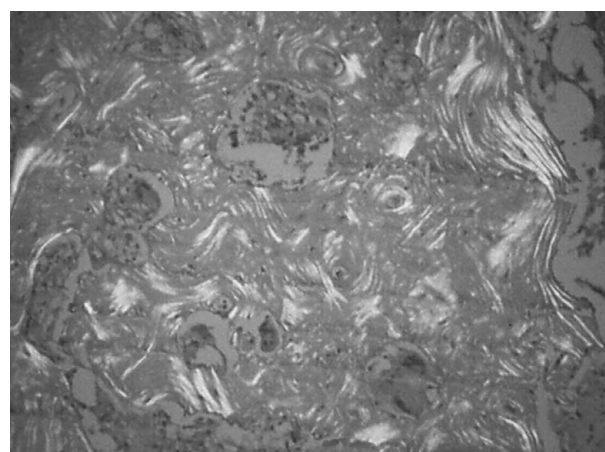


Figure 5. Bone specimen of Case 2 shows increased irregular cement line forming a mosaic pattern (hematoxylin & eosin under polarized light, 150 \times).

(Figure 5). The diagnosis of intermediate-phase Paget’s disease was made. In the succeeding years of follow-up, there were no obvious neurologic complications or bone pain, and lumbar roentgenography revealed no significant change. This patient no longer receives treatment and is being followed-up periodically.

Discussion

The lumbar spine is the most common site of spinal involvement in Paget’s disease, and is affected in approximately 50% of cases.^{6,7} Typically, involvement occurs at multiple vertebral levels, with only 10–25% of vertebral Paget’s disease cases being monostotic.^{8,9} Neurologic complications due to monostotic vertebral involvement have been reported, but the condition is usually minor and requires medical treatment only.^{10,11}

Paget’s disease of the bone is characterized by focal regions of highly exaggerated bone modeling

and remodeling, but occasionally a differential diagnosis of sclerotic or lytic metastases needs to be considered. Radionuclide bone scan can help to establish the diagnosis, and is recommended in all patients to determine the distribution of the disease. Computed tomography and MRI are helpful in the assessment of spinal stenosis or other neurologic complication. However, as early Paget's disease cannot always be distinguished from a metastatic tumor, a biopsy of the lesion may be performed.

In the later phase of the disease, a typical "picture frame" appearance of the vertebral body can be seen radiographically, and was noted in both of our cases (Figures 1 and 4). Enlargement of the vertebral body may result in incongruity of facet joint surface with destruction of articular cartilage and alteration of the biomechanics of the facet joints.^{2,5,12} Vertebral body enlargement and spondyloarthropathy of the facet joints may ultimately result in disc degeneration, and even spinal instability and stenosis. Due to the slow progression of vertebral Paget's disease, symptoms may be static for many years. Pharmacologic treatment is the first choice for symptomatic vertebral Paget's disease. Therapies with calcitonin and bisphosphonates have been shown to be clinically effective.^{2,13}

In Case 1, the symptoms gradually became more severe in the later months prior to surgical intervention. This may have been due to: (1) limited calcitonin bioavailability associated with nasal spray use;^{10,14} (2) development of antibodies leading to calcitonin resistance;^{1,2,10} (3) lack of therapeutic efficacy due to protein loss (including calcitonin) associated with continuous ambulatory peritoneal dialysis. As a consequence of failed pharmacologic therapy and the marked neurologic deficit, decompressive laminectomy was the treatment of choice in this particular case. The postoperative course was uneventful, and the patient was satisfied with the symptomatic relief and increased ambulatory ability. Although surgical risk is increased due to the increased lamina thickness and hypervascularity of Pagetic bone, decompressive laminectomy is an effective treatment for Paget's disease with marked spinal cord compression, or in cases where pharmacologic therapy has failed. As with all types of neural damage, recovery after surgery may be slow. The operation was palliative and was considered successful in terms of symptom relief. The ultimate cause of this patient's death (aspiration pneumonia and septic shock) was unrelated to the surgical procedure or Paget's disease.

In Case 2, there were no obvious lumbar radiographic changes apparent during follow-up. The development of osteosarcoma in Pagetic bone is relatively

rare, occurring in less than 1% of cases, while high-grade sarcomas are more commonly detected in patients with polyostotic lesions.^{1,2} Nevertheless, as this is the most serious possible complication of Paget's disease, patients like our Case 2 should be examined periodically.

Paget's disease with bone involvement is rare in Asia, and even rarer among Chinese.¹⁵ Our literature review found only 3 cases reported in Taiwan.¹⁶⁻¹⁸ Our Case 1 may be the first documented case of Paget's disease in the lumbar spine requiring decompressive laminectomy in an Asian population.

References

- Roodman GD, Windle JJ. Paget's disease of bone. *J Clin Invest* 2005;115:200-8.
- Koval KJ. Bone metabolism and metabolic bone diseases. In: Rosier RN, Bukata SV, eds. *Orthopedic Knowledge Update 7*. Philadelphia: American Academy of Orthopedic Surgeons, 2002:152-3.
- Hadjipavlou A, Gaitanis I, Kontakis G. Paget's disease of the bone and its management. *J Bone Joint Surg Br* 2002;84:160-9.
- Weinstein SL, Buckwalter JA. *Turek's Orthopedics: Principles and Their Application*, 5th edition. Philadelphia: Lippincott Williams & Wilkins, 1994:110-2.
- Hadjipavlou A, Lander P. Paget's disease of the spine. *J Bone Joint Surg Am* 1991;73:1376-81.
- Rosen MA, Matasar KW, Irwin RB, Rosenberg BF, Herkowitz HN. Osteolytic monostotic Paget's disease of the fifth lumbar vertebra: a case report. *Clin Orthop* 1991;262:119.
- Rosen MA, Wesolowski DP, Herkowitz HN. Osteolytic monostotic Paget's disease of the axis: a case report. *Spine* 1988;13:125.
- Awwad EE, Sundaram M. Radiologic case study: vertebral Paget's disease causing paraparesis. *Orthopedics* 1987;10:528-31.
- Chines A, Villareal D, Pacifici R. Paget's disease of bone affecting a single vertebra: clinical, radiological and histopathologic correlations. *Calcif Tissue Int* 1992;50:115.
- Kanis J. *Pathophysiology and Treatment of Paget's Disease of Bone*, 2nd edition. London: Martin Dunitz, 1998.
- Altman R. Paget's disease of bone. In: Coe FL, Favus MJ, eds. *Disorders of Bone and Mineral Metabolism*, 2nd edition. Philadelphia: Lippincott Williams & Wilkins, 2002:985-1020.
- Altman RD, Brown M, Gargano F. Low back pain in Paget's disease of bone. *Clin Orthop* 1987;217:152-61.
- Woitge HW, Oberwittler H, Heichel S, Grauer A, Ziegler R, Seibel MJ. Short- and long-term effects of ibandronate treatment on bone turnover in Paget disease of bone. *Clin Chem* 2000;46:684-90.
- Delmas PD, Meunier PJ. The management of Paget's disease of bone. *N Engl J Med* 1997;336:558-66.
- Resnick D, Niwayama G. Paget's disease. In: Resnick D, Niwayama G, eds. *Diagnosis of Bone and Joint Disorders*, 3rd edition. Philadelphia: Saunders, 1987:1923-63.
- Wang CL, Wu CT, Chien CR, Hang YH. Paget's disease of the tibia. *J Formos Med Assoc* 1999;98:444-7.
- Wu LC, Tsuang YH. Spinal stenosis due to monostotic Paget's disease of lumbar vertebra: a case report. *J Orthop Surg Taiwan* 2004;21:50-4.
- Hou CC, Lo CW, Chang JM, Tzeng CC. Monostotic Paget's disease: a case report. *Chin J Radiol* 2002;27:117-21.