

Intravitreal Injection of Bevacizumab for the Treatment of Choroidal Neovascularization in a Patient with Angioid Streaks

Yu-Chi Liu^{1,2}, Chang-Sue Yang^{1,2*}, Meng-Ping Shyong^{3,4}, Fenq-Lih Lee^{1,2}, Shui-Mei Lee^{1,2}

¹Department of Ophthalmology, Taipei Veterans General Hospital, ²National Yang-Ming University School of Medicine, ³Institute of Clinical Medicine, National Yang-Ming University School of Medicine, Taipei, and ⁴Su-Ao Veterans Hospital, I-Lan, Taiwan, R.O.C.

We report the favorable outcome of intravitreal injection of bevacizumab (Avastin) to treat choroidal neovascularization (CNV) secondary to angioid streaks in an 82-year-old Chinese man. Within 2 weeks of bevacizumab injection, visual acuity improved from 20/40 to 20/25 and optical coherence tomography revealed complete resolution of CNV and retinal edema. The juxtafoveal hemorrhage nearly disappeared, and the size of CNV markedly regressed from 1,200 μm to unremarkable on fluorescein angiography. These improvements were maintained after 2 additional doses of intravitreal bevacizumab administered at 4-week intervals. No ocular or systemic side effects were observed. Neither recurrent CNV lesion nor new hemorrhage was noted during 18 months of follow-up. The short-term results suggest that intravitreal injection of bevacizumab for the treatment of CNV in patients with angioid streak is well tolerated and highly effective. It may be a promising pharmacologic treatment option since limited therapies are available for this disease with a rather aggressive course. [*J Chin Med Assoc* 2009;72(2):98–102]

Key Words: angioid streaks, Avastin, bevacizumab, choroidal neovascularization

Introduction

Angioid streaks are irregular dark red or brownish lines radiating from the optic nerve head. They represent breaks or dehiscences in thickened and calcified Bruch's membrane and are associated with systemic diseases such as pseudoxanthoma elasticum.¹ Secondary development of choroidal neovascularization (CNV) is the most important and frequent complication. The natural history and visual prognosis is usually poor due to macular involvement and central vision loss.² Laser photocoagulation has limited success and high recurrence rate in treating CNV secondary to angioid streaks.² The long-term efficacy of photodynamic therapy (PDT) for angioid streaks and CNV remains under evaluation. Until recently, there were rare reports of effective therapy for CNV associated with angioid streaks in the literature.

Herein, we report our experience with managing a case of bilateral CNV in angioid streaks. Prior

transpupillary thermotherapy and intravitreal injection of triamcinolone did not prevent enlargement of CNV and a final disciform scar formation in the left eye of our patient. Thereafter, intravitreal injection of bevacizumab (Avastin; Genentech Inc., South San Francisco, CA, USA) was used as a salvage treatment in his right eye, and CNV completely regressed, with rapid vision improvement. There was no recurrent CNV during 18 months of follow-up. To the best of our knowledge, this is the longest follow-up period for this treatment modality ever reported.

Case Report

An 82-year-old male with a medical history of hypertension and old myocardial infarction came to our clinic due to blurred vision of the left eye for 1 month. Upon examination, best-corrected visual acuity (BCVA) was 20/32 in the right eye and 20/100 in the left eye.



*Correspondence to: Dr Chang-Sue Yang, Department of Ophthalmology, Taipei Veterans General Hospital, 201, Section 2, Shih-Pai Road, Taipei 112, Taiwan, R.O.C.
E-mail: csyang@vghtpe.gov.tw • Received: May 7, 2008 • Accepted: September 2, 2008

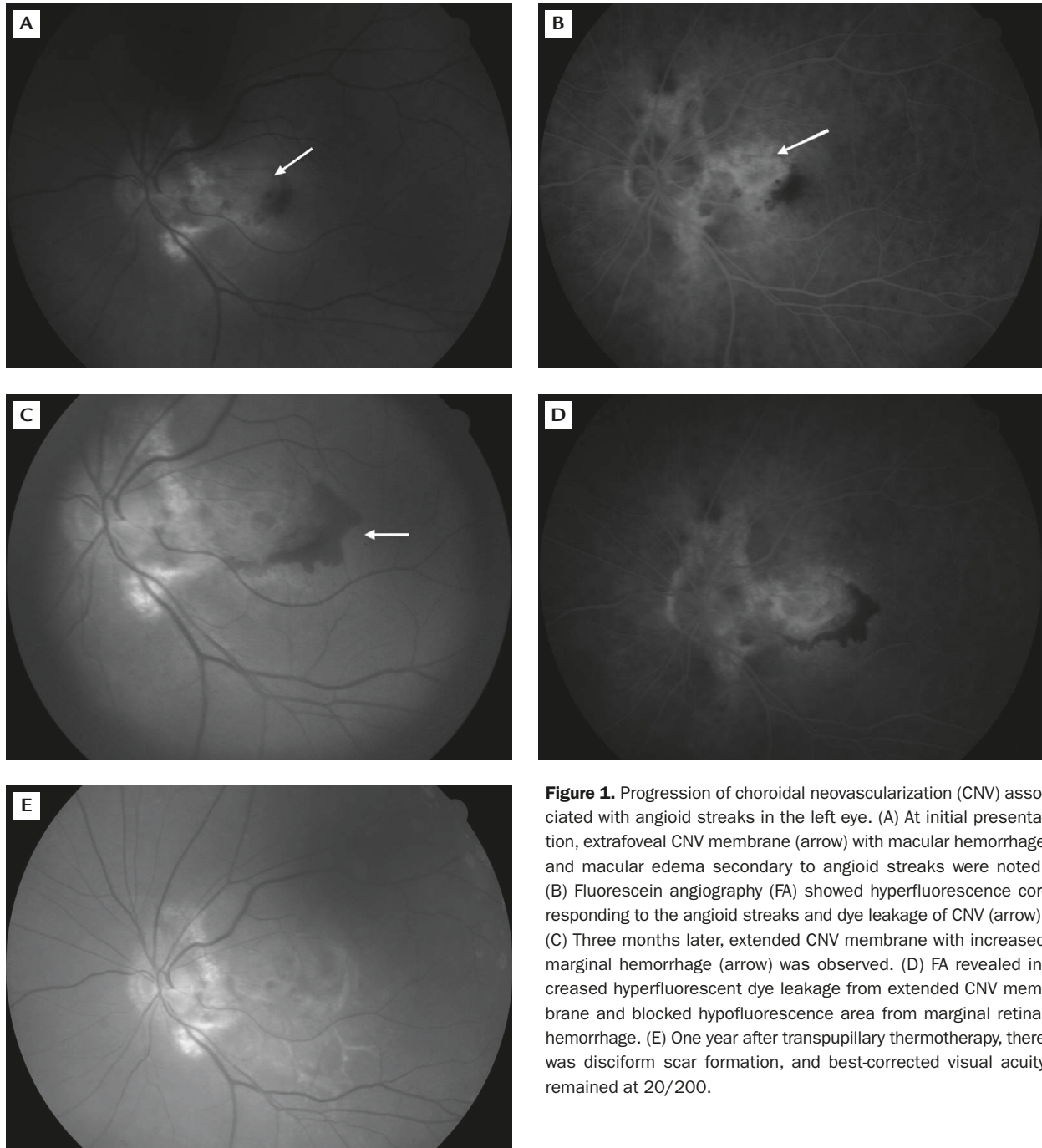


Figure 1. Progression of choroidal neovascularization (CNV) associated with angiod streaks in the left eye. (A) At initial presentation, extrafoveal CNV membrane (arrow) with macular hemorrhage and macular edema secondary to angiod streaks were noted. (B) Fluorescein angiography (FA) showed hyperfluorescence corresponding to the angiod streaks and dye leakage of CNV (arrow). (C) Three months later, extended CNV membrane with increased marginal hemorrhage (arrow) was observed. (D) FA revealed increased hyperfluorescent dye leakage from extended CNV membrane and blocked hypofluorescence area from marginal retinal hemorrhage. (E) One year after transpupillary thermotherapy, there was disciform scar formation, and best-corrected visual acuity remained at 20/200.

The anterior segments and intraocular pressure were normal in both eyes. Fundus examination showed bilateral angiod streaks, extrafoveal CNV membrane with macular hemorrhage and edema in the left eye (Figure 1A). Fluorescein angiography (FA) revealed hyperfluorescence corresponding to angiod streaks and leakage of extrafoveal CNV in the left eye (Figure 1B). The greatest linear dimension (GLD) of CNV, including CNV leakage area and blood-blocked hypofluorescence area, was 1,600 μm .

Triamcinolone acetonide (2 mg) was intravitreally injected in the left eye, and it consequently diminished macular edema and hemorrhage within 1 month after the injection. However, extended CNV membrane with increased marginal hemorrhage to 2,600 μm in GLD was noted in the left eye 2 months later (Figures 1C and 1D). The patient chose to undergo transpupillary thermotherapy (TTT) (550 mW in energy, 3.0 mm spot size, 60 seconds of exposure time) rather than PDT for treatment of his left eye due to financial considerations.

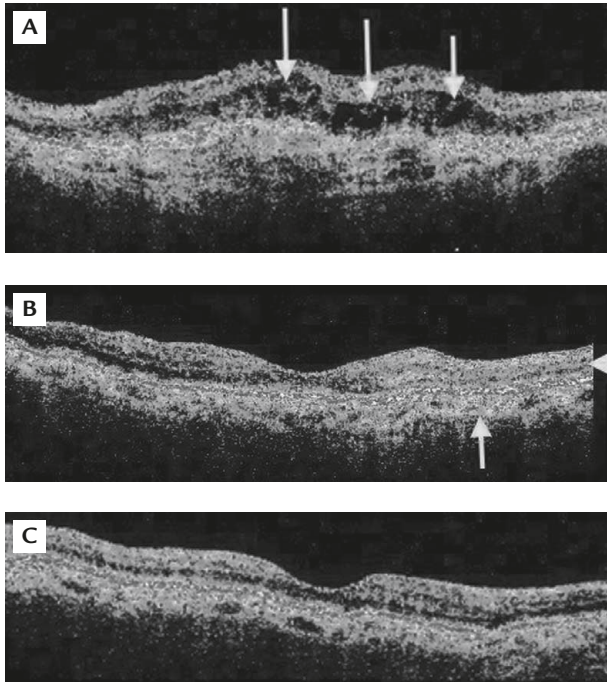


Figure 2. Choroidal neovascularization (CNV) associated with angioid streaks shown by optical coherence tomography (OCT). (A) In the left eye, extrafoveal CNV with retinal thickening and cystic edema (arrows) were noted 1 year after transpupillary thermotherapy. The central macular thickness on OCT was 317 μm . There was macular disciform scar formation and best-corrected visual acuity (BCVA) remained at 20/200. (B) At initial presentation of the right eye, juxtafoveal CNV (arrow) and intraretinal edema (arrowhead) were noted on OCT. (C) Two weeks after intravitreal injection of bevacizumab into the right eye, there was regression of CNV and resolution of retinal edema on OCT. BCVA improved from 20/40 to 20/25 1 month after the injection.

During 1 year of follow-up after TTT, macular disciform scar formation occurred and BCVA remained at 20/200 in his left eye (Figure 1E). Meanwhile, extrafoveal CNV with retinal thickening and cystic edema were still noted on optical coherence tomography (OCT) (Figure 2A). In addition, the patient suffered from metamorphopsia with BCVA of 20/40 in his right eye, and funduscopy disclosed juxtafoveal hemorrhage and macular edema in his right eye (Figure 3A). FA showed active dye leakage from the juxtafoveal CNV, measuring 1,200 μm in GLD (Figure 3B), and OCT showed juxtafoveal CNV and retinal edema in his right eye (Figure 2B).

After explaining the therapeutic options, the off-label use of bevacizumab (Avastin; Genentech Inc.) and its potential risks and benefits were discussed with the patient. He signed a comprehensive consent form. The patient was treated with an off-label intravitreal injection of bevacizumab 2.5 mg/0.1 mL into his right eye. Two weeks after the injection, there was

marked decrease of juxtafoveal hemorrhage on fundus examination (Figure 3C), and FA demonstrated obvious regression of CNV with dye staining only in his right eye (Figure 3D). There was also apparent resolution of juxtafoveal CNV and retinal edema on OCT (Figure 2C). The BCVA of the right eye improved to 20/25 1 month after the injection. The patient underwent another 2 repeat intravitreal injections of bevacizumab 2.5 mg/0.1 mL in the right eye at 1-month intervals. The BCVA in his right eye was preserved at 20/25, without recurrent CNV lesion or new hemorrhage, during 18 months of follow-up.

Discussion

CNV has been reported to occur from discontinuities or breaks in thickened and calcified Bruch's membrane in 70–86% of patients with angioid streaks. The visual prognosis of such lesions is poor because the natural history is aggressive and most have macular involvement.² Until recently, therapy for CNV in patients with angioid streaks remained a great challenge to ophthalmologists.

Laser photocoagulation may close the CNV and help stabilize visual acuity or slow visual loss, but with a very high frequency of recurrence.² TTT has also been used to treat CNV in patients with angioid streaks who had enlargement of the lesion and decrease in visual acuity.³ The authors commented that TTT did not appear to alter the course of the disease and the visual prognosis was usually poor.³ Our case had similar results following TTT in the left eye. Verteporfin PDT was recently used as an alternative therapy for CNV secondary to angioid streaks, but its benefits are still under evaluation. Browning et al⁴ showed that PDT appeared to limit visual loss through the first 12 months of follow-up, and Karacorlu et al⁵ described a short-term cessation or decrease of fluorescein leakage from CNV after PDT treatment. However, over a longer follow-up period, PDT did not seem to prevent disease progression, CNV growth and vision loss.⁶ We have recently presented increased and persistent subretinal hemorrhage with a final disciform scar formation after PDT for CNV secondary to angioid streaks.⁷ The visual prognosis was poor despite retreatments with PDT.

Bevacizumab is a humanized monoclonal antibody to vascular endothelial growth factor (VEGF) designed for intravascular administration, and is approved by the FDA for the treatment of metastatic colorectal cancer.⁸ Improvements in visual acuity, FA and OCT with intravitreal injection of bevacizumab to treat

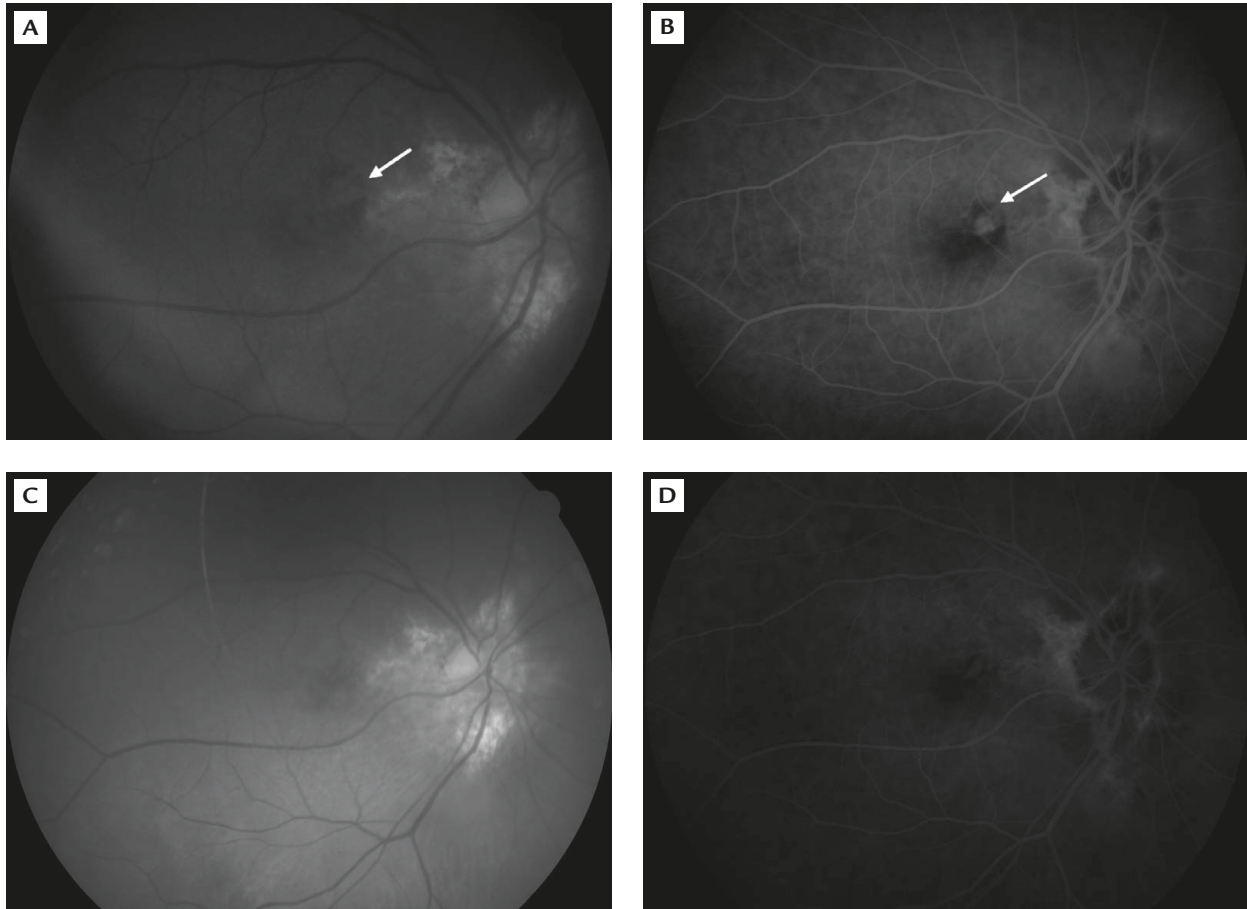


Figure 3. Regression of choroidal neovascularization (CNV) associated with angiod streaks after intravitreal injection of bevacizumab in the right eye. (A) Fundus photography revealed angiod streaks and juxtafoveal CNV with new retinal hemorrhage (arrow). (B) Active dye leakage of juxtafoveal CNV (arrow) and macular edema were noted on fluorescein angiography (FA). (C) Two weeks after treatment with intravitreal injection of bevacizumab, there was rapid and marked decrease in juxtafoveal hemorrhage. (D) There was obvious regression of CNV leakage, with dye staining only noted on FA.

neovascular age-related macular degeneration (AMD) have been reported by Rosenfeld et al.⁹ Based on this report, we hypothesized that this potent VEGF inhibitor might suppress CNV secondary to angiod streaks. Bevacizumab may be a promising pharmacologic treatment in this field, but has rarely been discussed.^{10,11}

In the left eye of the present case, TTT and intravitreal triamcinolone did not prevent the angiogenesis and enlargement of CNV, but produced disciform scar and poor visual outcome. Owing to the patient's refusal to receive PDT, we decided to perform an off-label intravitreal injection of bevacizumab into his right eye as a salvage treatment. The patient rapidly and favorably improved in visual acuity and FA outcome, and the retinal structures normalized on OCT examination. We thought that these favorable functional and anatomic results might be due to the combined anti-leakage and anti-angiogenesis effect of bevacizumab without inducing any chorioretinal tissue damage.

These improvements were maintained without recurrence of CNV after 2 additional bevacizumab monthly injections. Our results from using this anti-VEGF agent in angiod streaks have shown that it is able to arrest the progression of CNV with long-term quiescence following 3 injections. This might imply that the pathogenic activity of CNV secondary to angiod streaks is more similar to that of pathologic myopia than that of AMD. Longer follow-up and prospective studies are necessary for further evaluation of the long-term therapeutic effects and optimal injection frequency.

In conclusion, we presented a patient with bilateral CNV in angiod streaks. TTT and intravitreal triamcinolone did not prevent enlargement of CNV and disciform scar formation in prior left eye treatment. In contrast, after intravitreal injection of bevacizumab in the right eye, CNV completely regressed, with vision improvement over 18 months of follow-up. The short-term therapeutic effect was satisfactory in both visual

and anatomic outcomes. Since no ideal treatment has been available for this disease with an aggressive course, intravitreal injection of bevacizumab appears to be promisingly effective in treating such patients.

Acknowledgments

This study was supported by grants from the National Science Council and Taipei Veterans General Hospital (V95C1-144, V97C1-164), Taiwan.

References

1. Mansour AM. Systemic associations of angioid streaks. *Ophthalmologica* 1993;207:57–61.
2. Lim JI, Bressler NM, Marsh MJ, Bressler SB. Laser treatment of choroidal neovascularization in patients with angioid streaks. *Am J Ophthalmol* 1993;116:414–23.
3. Aras C, Baserer T, Yolar M, Yetik H, Artunay O, Guzel H, Ozkan S. Two cases of choroidal neovascularization treated with transpupillary thermotherapy in angioid streaks. *Retina* 2004;24:801–3.
4. Browning AC, Chung AK, Ghanchi F, Harding SP, Musadiq M, Talks SJ, Yang YC, et al. Verteporfin photodynamic therapy of choroidal neovascularization in angioid streaks: one-year results of a prospective case series. *Ophthalmology* 2005;112:1227–31.
5. Karacorlu M, Karacorlu S, Ozdemir H, Mat C. Photodynamic therapy with verteporfin for choroidal neovascularization in patients with angioid streaks. *Am J Ophthalmol* 2002;134:360–6.
6. Arias L, Pujol O, Rubio M, Caminal J. Long-term results of photodynamic therapy for the treatment of choroidal neovascularization secondary to angioid streaks. *Graefes Arch Clin Exp Ophthalmol* 2006;244:753–7.
7. Shyong MP, Chen SJ, Lee FL, Tsao YP, Hsu WM. Increased and persistent subretinal haemorrhage after photodynamic therapy for choroidal neovascularization secondary to angioid streaks. *Eye* 2006;20:1420–2.
8. Hurwitz H, Fehrenbacher L, Novotny W, Cartwright T, Hainsworth J, Heim W, Berlin J, et al. Bevacizumab plus irinotecan, fluorouracil, and leucovorin for metastatic colorectal cancer. *N Engl J Med* 2004;350:2335–42.
9. Rosenfeld PJ, Moshfeghi AA, Puliafito CA. Optical coherence tomography findings after an intravitreal injection of bevacizumab (Avastin) for neovascular age-related macular degeneration. *Ophthalmic Surg Lasers Imaging* 2005;36:331–5.
10. Teixeira A, Moraes N, Farah ME, Bonomo PP. Choroidal neovascularization treated with intravitreal injection of bevacizumab (Avastin) in angioid streaks. *Acta Ophthalmologica Scandinavica* 2006;84:835–6.
11. Rinaldi M, Dell’Omo R, Romano MR, Chiosi F, Cipollone U, Costagliola C. Intravitreal bevacizumab for choroidal neovascularization secondary to angioid streaks. *Arch Ophthalmol* 2007;125:1422–3.