

Acute Severe Chromium Poisoning After Dermal Exposure to Hexavalent Chromium

Chun-Chi Lin¹, Ming-Ling Wu^{1,2*}, Chen-Chang Yang^{1,3}, Jiin Ger^{1,2}, Wei-Jen Tsai^{1,2}, Jou-Fang Deng^{1,2}

¹Division of Clinical Toxicology, Department of Medicine, Taipei Veterans General Hospital, and Departments of

²Medicine and ³Environmental and Occupational Medicine, Faculty of Medicine, National Yang-Ming University School of Medicine, Taipei, Taiwan, R.O.C.

Severe acute chromium poisoning related to dermal involvement has rarely been reported in the literature. We report a case of acute severe chromium poisoning through skin exposure as a result of a chemical burn of 15% of the body surface area and multiple organ failure after short-term exposure. Medical interventions, including mechanical ventilation, continuous venovenous hemofiltration, and plasmapheresis were performed. In addition, a chelating agent, dimercaptopropane sulfonic acid, was infused intravenously, combined with intravenous N-acetylcysteine and ascorbic acid as adjuvant therapy. The patient was discharged on day 33 without long-term sequelae. The consequence of transdermal exposure of hexavalent chromium should not be overlooked. [*J Chin Med Assoc* 2009;72(4):219–221]

Key Words: acute renal failure, chromium poisoning, dermal exposure

Introduction

Chromium is a trace element that is essential to human health. It is also widely used in various industries. Chromium exists in both metallic and valence states, with hexavalent chromium being the most toxic and carcinogenic. Strongly oxidizing and corrosive, hexavalent chromium salts such as potassium dichromate or chromic acid cause local dermal effects and systemic toxicity when they enter the body through the skin. Local dermal effects, including chrome holes, contact dermatitis and chemical burns, are commonly seen in occupational exposure cases. On the other hand, systemic toxicity of hexavalent chromium, which is commonly seen after intentional exposure, causes intense gastrointestinal bleeding, renal failure, intravascular hemolysis, liver damage, shock, coma, and even death.¹ Severe acute chromium poisoning following dermal involvement has rarely been reported.^{2–5} We report a case of acute chromium poisoning that resulted from extensive dermal exposure to hexavalent chromium in an electroplating tank.

Case Report

A 22-year-old electroplating worker entered a 3-meter high electroplating tank to clean its interior. Although he noticed that the electroplating solution had not completely drained away and his legs were immersed in the solution, he continued his cleaning work. The electroplating solution was later identified as chromic acid. The worker experienced a pricking pain over his lower limbs within 10 minutes. He left the tank immediately and washed his legs with a copious amount of water. However, his condition deteriorated, with subsequent presentations of nausea, vomiting, abdominal pain, dyspnea and dizziness.

Three hours after exposure, he visited our emergency department for help. On arrival, physical examination revealed an alert and afebrile patient (blood pressure, 118/78 mmHg; pulse, 94/min) with clear breath sounds. The noticeable abnormality was the presence of first-degree chemical burns over both legs with brown-tinged pigmentation, estimated to be about 15% of total body surface area (TBSA). Laboratory



*Correspondence to: Dr Ming-Ling Wu, Division of Clinical Toxicology, Department of Medicine, Taipei Veterans General Hospital, 201, Section 2, Shih-Pai Road, Taipei 112, Taiwan, R.O.C.
E-mail: mlwu@vghtpe.gov.tw • Received: May 23, 2008 • Accepted: November 25, 2008

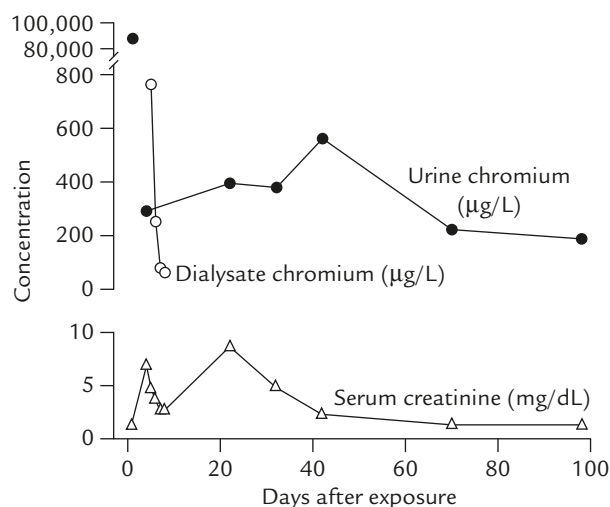
Table 1. Selected laboratory values of a 22-year-old man following transdermal exposure to hexavalent chromium*

	Day 1	Day 2	Day 3	Day 4	Day 5	Day 6	Day 7	Day 13
WBC (4,500–11,000/mm ³)	22,000	17,500	14,500	15,900	8,400	10,100	12,000	13,700
Segmented neutrophils/lymphocytes (%)	97/1	90/4	84/12	95/1	89/7	97/3	86/7	72/18
Hemoglobin (14–18 g/dL)	16.7	15.9	15.3	16.5	12.5	12.1	14.1	12.3
Platelets (150–400 × 10 ³ /mm ³)	346	301	220	164	104	96	118	343
Sodium (135–147 mmol/L)	136	138	126	132	138	142	138	131
Potassium (3.4–4.7 mmol/L)	3.0	3.9	4.4	3.4	3.3	2.7	2.6	3.7
Chloride (100–114 mmol/L)		99	92					
Calcium (8.4–10.6 mg/dL)		7.7		6.4		7.8		
BUN (7–20 mg/dL)	18	29	37	35	28	30	22	47
Creatinine (0.5–1.5 mg/dL)	1.2	2.6	8.1	6.8	4.6	3.6	2.6	9.3
ALT (0–40 U/L)		32	235	204	68	65	134	107
AST (5–45 U/L)		60	780	674	24	65	68	43
Creatinine phosphokinase (0–140 U/L)	450	597		607		222		186

*Continuous venovenous hemofiltration was performed on days 3–10, and hemodialysis was carried out on days 10–30. WBC = white blood cell count; BUN = blood urea nitrogen; ALT = alanine aminotransferase; AST = aspartate aminotransferase.

workup was remarkable for leukocytosis, with a white blood cell count of 22,000/mm³, and mild elevation of creatinine phosphokinase to 450 U/L (normal, 0–140 U/L). Blood creatinine and hepatic aminotransferase levels were within normal limits. Selected laboratory values are shown in Table 1. Under room air, arterial blood gas was pH 7.4, PCO₂ was 37.4 mmHg, PO₂ was 83.3 mmHg, and HCO₃ was 22.6 mmol/L. Methemoglobin level was reported later with a value of 0.8%. Chest X-ray showed no active lung lesions. The chromium concentration of the tank solution was 1.42 M. Initial chromium level of spot urine was 88,208 µg/L (reference, 0–5.2 µg/L). Because of progressive chromium intoxication, the patient was hospitalized and received adequate fluid replacement therapy. Chelating therapy with intravenous dimercaptopropanesulfonate (DMPS) 125 mg every 12 hours was started on day 1 post exposure. Intravenous N-acetylcysteine 50 mg/kg every 4 hours and ascorbic acid 100 mg every 12 hours were also used as adjuvant therapy.

Oliguria with increasing serum creatinine level developed within 24 hours. In spite of emergent hemodialysis, acute pulmonary edema with subsequent respiratory failure developed on day 3. The patient was intubated and placed on mechanical ventilation. Transient liver function impairment (peak alanine aminotransferase level of 235 U/L on day 3) and elevated creatinine phosphokinase (peak level of 607 U/L on day 4) were also noted. Anemia and thrombocytopenia developed on day 5. Continuous venovenous hemofiltration and plasmapheresis were also instituted on day 3 and chelating therapy with DMPS and N-acetylcysteine were continued. Daily chromium

**Figure 1.** Sequential change in chromium and creatinine levels.

concentrations in dialysate were 763, 250, 79, and 61 µg/L from day 5 through to day 8, respectively.

Although the patient developed multiple skin chrome ulcers and had prolonged acute renal failure, his condition gradually improved. On day 10, he was transferred to the general ward and no longer required hemofiltration, plasmapheresis, or therapy with DMPS and N-acetylcysteine. Acute renal failure was managed with hemodialysis until day 30. He was discharged on day 33 without the need of supplemental oxygen or hemodialysis. Follow-up at the outpatient clinic for 3 months did not reveal the presence of any organ dysfunction. The Details of serial urine chromium and serum creatinine measurements are shown in Figure 1.

Discussion

Systemic toxicity from transdermal exposure to hexavalent chromium should not be overlooked. Previous reports showed significant morbidity and mortality among cases who had chromic burn > 10% TBSA. Two cases died with external burns of 10% and 40% of TBSA caused by chromic acid,^{2,5} and a 20% TBSA burn produced hepatic damage, acute renal failure and anemia in another patient.⁶ Even a small burn of 1% TBSA might result in significant illness.³

The absorption of hexavalent chromic ions through the skin is assumed to be rather rapid. In general, peak blood level can be reached within 5 hours after skin exposure.^{7,8} Organ damage can occur thereafter. In our case, the kidney was the main target organ. While the skin lesions were relatively self-limited, this patient manifested acute renal failure complicated with acute respiratory failure for a prolonged period. Serum creatinine level did not return to normal until 70 days after exposure. In addition, transient liver function impairment and elevated creatinine phosphokinase were also noted. Certain severe manifestations, such as intense gastrointestinal bleeding, intravascular hemolysis, shock and coma, were not observed in our case.

Chromium is mainly excreted through urine, with an initial half-life of 2–3 days, followed by a terminal half-life of about 1 month.⁹ Initial urine chromium level in this case was 88,208 µg/L, which decreased rapidly to 292 µg/L on day 4. Nevertheless, urine chromium levels remained elevated until 3 months after exposure, hinting that chromic ion reenters the blood circulation slowly when it is distributed into extravascular spaces.

Supportive measures are considered as the mainstay in the management of acute chromium poisoning. Although chromium is primarily excreted through urine, extracorporeal removal measures, such as hemodialysis, hemoperfusion or peritoneal dialysis, are not helpful in removing chromium from the body.¹⁰ Hemodialysis in our case was implemented for acute renal failure complicated with acute pulmonary edema, not for chromium removal. Exchange transfusion might be another choice to reduce blood chromium concentration, but its effect on prognosis remains unclear.¹¹ Based on animal studies, several medications have been recommended in treating chromium poisoning. Among them, ascorbic acid has the potential capacity to enhance the reduction of hexavalent chromium to the less toxic trivalent chromium, while N-acetylcysteine and DMPS may significantly increase the total amount of chromium excretion.^{12–14} N-acetylcysteine and DMPS were both administered to our patient 6 hours after chromium exposure. However, he did not avoid

developing life-threatening phenomena, such as acute renal failure and pulmonary edema.

Early aggressive excision of exposed skin is an alternative way to decrease the systemic toxicity from dermal chromium exposure. One patient who had a 10% TBSA burn caused by chromic acid did not develop systemic toxicity when excision of the burned area was performed 7 hours post exposure.⁴

In summary, we have reported a case of acute chromium poisoning from dermal exposure. It illustrated that absorption of chromium from a 15% burn of TBSA could result in severe systemic toxicity. Therefore, the consequences of transdermal exposure to hexavalent chromium should not be overlooked.

Acknowledgments

The authors are indebted to the Taiwan Environmental and Occupational Medicine Association for the “Young Physician Award for Medichem 2008”.

References

1. Barceloux DG. Chromium. *J Toxicol Clin Toxicol* 1999;37:173–94.
2. Major RH. Studies on a case of chromic acid nephritis. *Johns Hopkins Hosp Bull* 1922;33:56–61.
3. Terrill PJ, Gowar JP. Chromic acid burn: beware, be aggressive, be watchful. *Br J Plast Surg* 1990;43:699–701.
4. Matey P, Allison KP, Sheehan TM, Gowar JP. Chromic acid burns: early aggressive excision is the best method to prevent systemic toxicity. *J Burn Care Rehabil* 2000;21:241–5.
5. Wang XW, Davies JW, Sirvent RLZ. Chromic acid burns and acute chromium poisoning. *Burns* 1985;11:181–4.
6. Schiffel H, Weidmann P, Weiss M, Massry SG. Dialysis treatment of acute chromium intoxication and comparative efficacy of peritoneal versus hemodialysis in chromium removal. *Mineral Electrolyte Metab* 1982;7:28–35.
7. Baranowska-Dutkiewicz B. Absorption of hexavalent chromium by skin in man. *Arch Toxicol* 1981;47:47–50.
8. Laitung JK, Earley M. The role of surgery in chromic acid burn: our experience with two patients. *Burns Incl Therm Inj* 1984;10:378–80.
9. Lindberg E, Vesterberg O. Urinary excretion of chromium in chromeplaters after discontinued exposure. *Am J Ind Med* 1989;16:485.
10. Ellis EN, Brouhard BH, Lynch RE. Effects of hemodialysis and dimercaprol in acute dichromate poisoning. *J Toxicol Clin Toxicol* 1982;19:249–58.
11. Meert KL, Ellis J, Aronow R. Acute ammonium dichromate poisoning. *Ann Emerg Med* 1994;24:748–50.
12. Bradberry SM, Vale JA. Therapeutic review: is ascorbic acid of value in chromium poisoning and chromium dermatitis? *J Toxicol Clin Toxicol* 1999;37:195–200.
13. Hruby K, Donner A. 2,3-dimercapto-1-propanesulphonate in heavy metal poisoning. *Med Toxicol Adverse Drug Exp* 1987;2:317–23.
14. Hantson P, Van Caenegem O, Decordier I, Haufroid V, Lison D. Hexavalent chromium ingestion: biological markers of nephrotoxicity and genotoxicity. *Clin Toxicol* 2005;43:111–2.