

An Unusual Case of Metastatic Small Intestinal Tumor Due to Prostate Cancer

Shou-Wu Lee^{1*}, Teng-Yu Lee¹, Hong-Zen Yeh¹, Chi-Sen Chang¹, Ren-Ching Wang²

¹Division of Gastroenterology, Department of Internal Medicine, and ²Department of Pathology, Taichung Veterans General Hospital, Taichung, Taiwan, R.O.C.

Prostate cancer is a common cancer in men, and its clinical behavior ranges from microscopic tumors to aggressive cancer with metastatic potential. We report the case of an 81-year-old man with primary prostate cancer, AJCC stage T2 and Gleason's score 10, which was diagnosed in March 2007. The patient received upper endoscopy due to symptoms of abdominal fullness and body weight loss, and a soft tumor in the secondary portion of the duodenum was found. Biopsy demonstrated a poorly differentiated carcinoma with positive prostate specific antigen cytoplasmic stain. The pathologic appearance was consistent with prostate cancer metastatic to the small bowel. Abdominal computed tomography also showed multiple liver tumors with enlarged retroperitoneal lymph nodes. This case should help raise clinical awareness of the possibility of unusual metastatic sites in patients with primary prostate cancer. [*J Chin Med Assoc* 2009;72(5): 271–274]

Key Words: prostate cancer, small bowel metastasis

Introduction

Prostate cancer is a common cancer in men. In America, 218,890 cases are diagnosed and 27,050 deaths occur annually.¹ In Taiwan, prostate cancer is the 6th most common cancer in males, and its incidence rose to 14 per 105 in the year 2000.² The clinical behavior of prostate cancer ranges from a microscopic, well-differentiated tumor to an aggressive cancer with substantial invasive and metastatic potential. The most common metastatic targets for prostate cancer include lymph nodes, bone, lung and liver.³ Metastasis to the small intestine is an unusual phenomenon of prostate cancer, but it can elicit several gastrointestinal complications, such as bleeding or obstruction. Herein, we present a case of small intestine tumor caused by metastasis of prostate cancer.

Case Report

An 81-year-old man had a history of benign prostate hyperplasia for 10 years. He came to our hospital due to symptoms of abdominal fullness and urine retention

of 1 month's duration in April 2007. He had no history of dysuria or body weight loss. Laboratory workup demonstrated microscopic hematuria by urinary analysis and a high level of prostate-specific antigen (PSA) up to 44.9 ng/mL (normal, <4.0 ng/mL). Abdominal computed tomography (CT) detected enlargement of the prostate gland to about 5.3 cm in diameter with low attenuation nodules (Figure 1A). Transurethral resection of the prostate was performed, and biopsy reported adenocarcinoma without perineural invasion. Gleason's score was 5 + 5 (Figure 2A). Bone scan study found no definite evidence of bone metastasis. The initial stage was T2N0M0, and the patient was later discharged from our hospital and received radiotherapy of the prostate gland for 2 months with a total dose of 4,680 cGy, which was followed by continuous hormone therapy. PSA level ranged from 2 ng/mL to 4 ng/mL.

The patient was brought to our hospital in April 2008 due to symptoms of abdominal fullness, poor appetite and body weight loss of 10 kg over a period of 2 months. He had no history of cough, oligouria, abdominal pain or tarry stool. Laboratory workup detected nonspecific findings except for an elevated PSA level



*Correspondence to: Dr Shou-Wu Lee, Division of Gastroenterology, Department of Internal Medicine, Taichung Veterans General Hospital, 160, Section 3, Chung-Kang Road, Taichung 407, Taiwan, R.O.C. E-mail: ericest@vghtc.gov.tw • Received: July 31, 2008 • Accepted: January 23, 2009

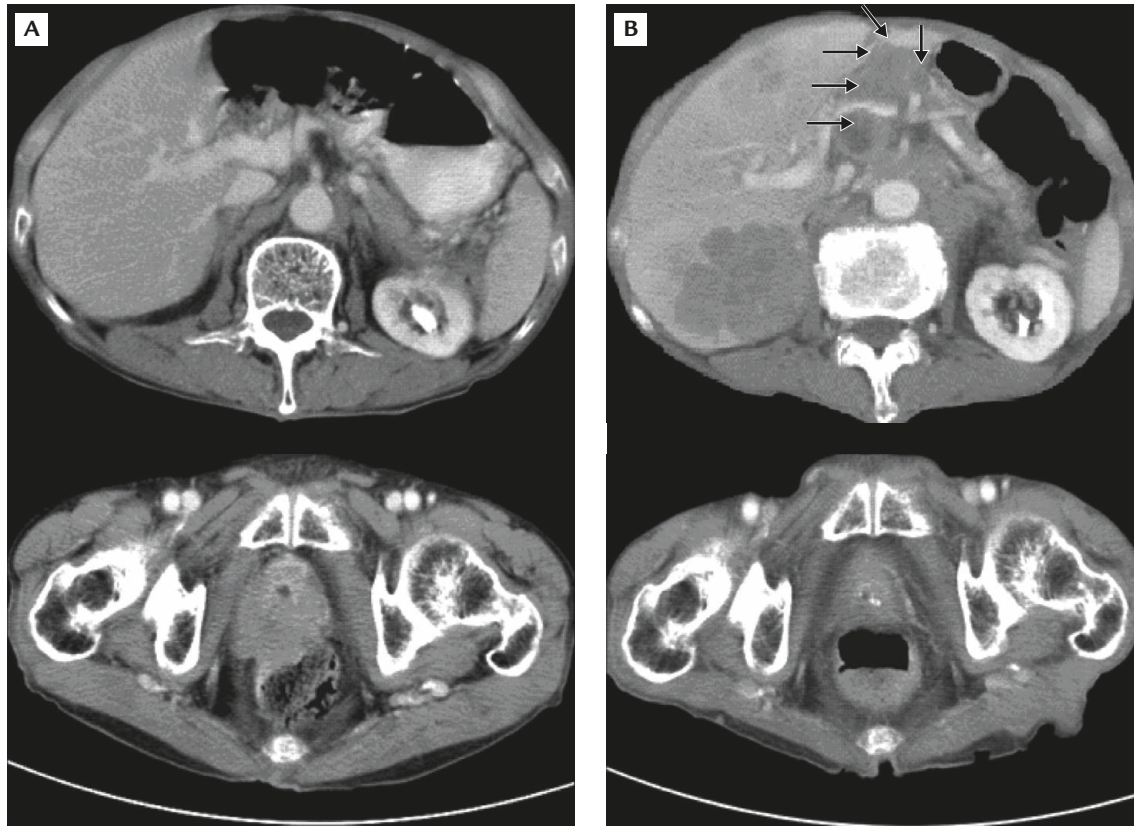


Figure 1. (A) Abdominal computed tomography in April 2007 shows an enlarged prostate gland with low attenuation nodules. (B) Abdominal computed tomography 1 year later in April 2008 shows progression to retroperitoneal lymph node and liver metastasis with duodenal invasion (arrows).

of 9.20 ng/mL. Upper endoscopy showed a single soft tumor with hyperemic mucosal change in the secondary portion of the duodenum complicated with partial lumen narrowing (Figure 3), and biopsy demonstrated duodenal tissue with poorly differentiated carcinoma with positive PSA cytoplasmic stain. The morphology of the duodenal tumor was similar to the previous prostate pathologic appearance and was consistent with prostate cancer metastasis to the small bowel (Figures 2B–D). Abdominal CT demonstrated only mild enlargement of the prostate gland, but showed enlarged retroperitoneal lymph nodes and multiple liver tumors with probable duodenal invasion (Figure 1B). Bone scan study did not detect any evidence of bone metastasis.

The patient was later discharged from hospital and received clinical follow-up. No further aggressive treatment was administered due to patient refusal.

Discussion

The incidence of prostate cancer has been increasing rapidly. The clinical course of prostate cancer ranges

from a well-differentiated and localized tumor to an invasive and metastatic cancer. The predictive factors for prognosis can be estimated by American Joint Committee on Cancer (AJCC) staging criteria and Gleason's score.⁴

The Gleason grading system is based on the architectural features of prostate cancer cells, and an increasing percentage of high-grade tumor is associated with a statistically significant poorer cancer specific survival rate.⁵ Metastases are more common in patients with poorly differentiated lesions and are usually seen in tumors that penetrate the capsule.⁶ In our patient, the pathologic prostate appearance showed a poorly differentiated carcinoma in a solid sheet pattern without perineural invasion, which is consistent with AJCC stage T2 and Gleason's score 10 (5+5). The finding of typical PSA histological patterns in the duodenal tumor is highly suggestive of prostatic origin.

As the survival period of patients with prostate cancer is prolonged, some unusual metastatic sites caused from the origin of prostate cancer have been identified. However, there have been no cases of metastasis to the small intestine except for a single

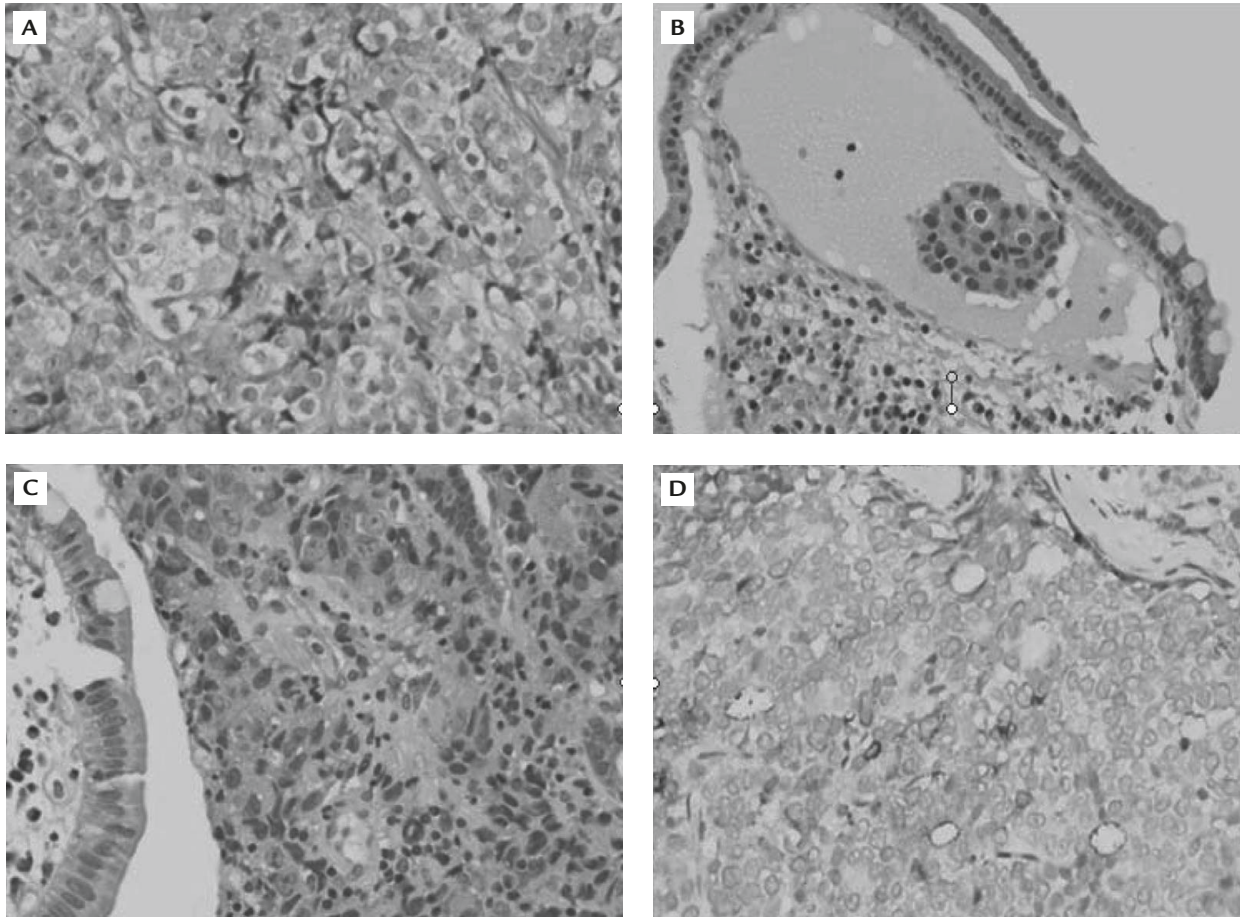


Figure 2. Pathology of the prostate gland and duodenal tumor. (A) Primary tumor in prostate is poorly differentiated carcinoma with a solid sheet pattern without glandular lumen, Gleason grade 5 (hematoxylin & eosin, 400 \times). (B) Duodenal mucosa shows lymphatic tumor thrombus in the mucosal lymphatic duct (hematoxylin & eosin, 400 \times). (C) Biopsy of duodenal tumor shows poorly differentiated carcinoma in sheet-like growth pattern and single-cell infiltration. Normal intestinal villi can be seen on the left (hematoxylin & eosin, 400 \times). (D) Prostate-specific antigen cytoplasmic stain in tumor cells of the duodenal biopsy (immunohistochemical stain, 400 \times).

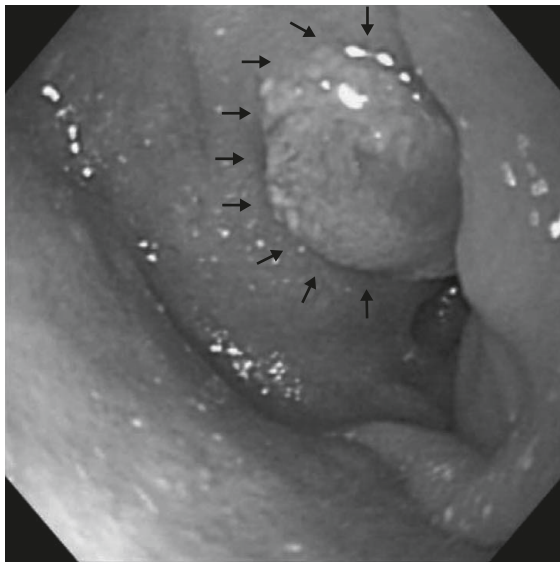


Figure 3. Upper endoscopy shows a soft tumor (arrows) in the secondary portion of the duodenum with partial lumen narrowing.

previous case report; in 2001, Narveet reported a case of a 69-year-old man with a history of prostate cancer, stage T3, and subsequent radical prostatectomy and radiotherapy. He had malignant periportal lymphadenopathy 6 years afterwards, and received upper endoscopy 9 years later due to symptoms of anasarca. Visual inspection of the gastroduodenal mucosa was normal, but biopsy of duodenal mucosa detected infiltrating adenocarcinoma with a positive PSA stain.⁷ The findings of the upper endoscopy was not similar to our patient's. The solitary duodenal tumor found in our patient may be due to direct invasion from a neighboring liver tumor rather than lymphatic metastasis.

According to a previous survey, the lymphatic drainage of the prostate determines the location of the initial metastases, but the subsequent widespread metastases probably originate from the sentinel node.⁶ Although prostate cancer can metastasize to almost any site in

the body, the lymph nodes and bone remain the most common sites.⁵ A study in 1986 of 89 autopsies of prostate cancer patients showed metastasis to serosa, liver, and large bowel accounting for 37%, 30%, and 13%, respectively.⁸ A more recent study in 2008 that included 191 autopsies demonstrated that the 5 most common metastatic targets for prostate cancer were the regional lymph nodes (26.2%), bone (19.7%), distant lymph nodes (18.4%), lung (12.8%), and liver (7.8%).³ However, a study in 2004 documented 2 cases of small intestine involvement out of a total of 30 autopsies with primary prostate cancer.⁹ Therefore, small intestine metastasis should not be ignored in patients with advanced prostate cancer.

In conclusion, we have reported an unusual case of a patient with metastatic duodenal tumor caused by primary prostate cancer. This case should help raise clinical awareness of the possibility of unusual metastatic sites in patients with primary prostate cancer.

References

1. Jemal A, Siegel R, Ward E, Murray T, Xu J, Thun MJ. Cancer statistics, 2007. *CA Cancer J Clin* 2007;57:43–66.
2. Pu YS. Prostate cancer in Taiwan: epidemiology and risk factors. *Int J Androl* 2000;23:234–6.
3. DiSibio G, French SW. Metastatic patterns of cancers: results from a large autopsy study. *Arch Pathol Lab Med* 2008;132:931–9.
4. Augustin H, Graefen M, Palisaar J, Blonski J, Erbersdobler A, Daghofer F, Huland H, et al. Prognostic significance of visible lesions on transrectal ultrasound in impalpable prostate cancers: implications for staging. *J Clin Oncol* 2003;21:2860.
5. Brawn P. Histologic features of metastatic prostate cancer. *Hum Pathol* 1992;23:267–72.
6. Whitmore WF Jr. Proceedings: the natural history of prostatic cancer. *Cancer* 1973;32:1104–12.
7. Malhi-Chowla N, Wolfsen HC, Menke D, Woodward TA. Prostate cancer metastasizing to the small bowel. *J Clin Gastroenterol* 2001;32:439–40.
8. de la Monte SM, Moore GW, Hutchins GM. Metastatic behavior of prostate cancer: cluster analysis of patterns with respect to estrogen treatment. *Cancer* 1986;58:985–93.
9. Macvicar GR, Shah R, Kalikin LM, Rubin MA, Smith DC, Pienta KJ. Update of the rapid autopsy study for procurement of metastatic prostate cancer. *Proc Am Assoc Cancer Res* 2004;45:1034.