

High-resolution Computed Tomography in the Diagnosis of Otosclerosis in Taiwan

Tsung-Lun Lee^{1,3}, Mao-Che Wang^{1,3}, Jiing-Feng Lirng^{2,3}, Wen-Huei Liao^{1,3},
Eric Chen-Hua Yu⁴, An-Suey Shiao^{1,3*}

*Departments of¹Otolaryngology and ²Radiology, Taipei Veterans General Hospital, and
³National Yang-Ming University School of Medicine, Taipei, Taiwan, R.O.C.,
⁴Freeman Spogli Institute for International Studies, Stanford University, U.S.A.*

Background: Otosclerosis is rare in Asians, and the clinical role of imaging remains controversial. We sought to clarify the tomographic findings of otosclerosis in Taiwanese patients and determine the value and necessity of high-resolution computed tomography (HRCT) of the temporal bone in diagnosing the disease in Taiwan.

Methods: This retrospective study enrolled 22 patients (24 ears) with clinically, surgically and pathologically confirmed otosclerosis. All subjects underwent HRCT of the temporal bone; the images were then reviewed at workstations. The control group consisted of 15 patients.

Results: HRCT was positive in 46% of the clinically, surgically and pathologically confirmed otosclerotic ears. Patients with a positive imaging study had a smaller preoperative air–bone gap and a significantly shorter duration of the disease. The duration of the disease also tended to be greater in patients with a larger preoperative air–bone gap.

Conclusion: HRCT has high specificity (100%) but low sensitivity (46%) for the diagnosis of otosclerosis in Taiwanese patients despite progress in radiology. The low image positive rate we found, compared with that in Western literature, may stem from a greater percentage of inactive otosclerosis. [*J Chin Med Assoc* 2009;72(10):527–532]

Key Words: otosclerosis, radiology information systems, X-ray computed tomography

Introduction

Otosclerosis is a primary focal osteodystrophy of the human otic capsule with an initial clinical manifestation of slowly progressive conductive or mixed hearing loss, tinnitus and vestibular symptoms. As the disease progresses, inner ear symptoms, such as sensorineural hearing loss and tinnitus, may manifest themselves, constituting a dynamic clinical feature.¹ Due to the close anatomic relationship between the vestibule and the stapes footplate, vertiginous symptoms can occur in patients with otosclerosis.²

Diagnosis of otosclerosis depends on medical history, physical examination and audiological tests (such as conductive hearing loss, absent stapedial reflexes, Carhart's notch, and type A tympanogram). Previously, audiological measurements such as air–bone gap (ABG) or types of conductive hearing loss have been used to reveal the disease progression.^{3,4} Recently, air

conducted-vestibular evoked myogenic potentials (air conducted-VEMPs) have been used to complement the results obtained with bone conducted-VEMPs to classify the stages of otosclerosis.⁵

So far, the clinical role that computed tomography (CT) plays in otosclerosis remains controversial.^{6,7} Recently, however, the examination process has become more important since positive radiographic findings in Western literature have been about 90%. Hence, high-resolution CT (HRCT) scanning may be helpful in either differentiating middle ear disorders or for confirming the diagnosis of otosclerosis before operative treatment, thereby helping in surgical planning and patient counseling.

Otosclerosis can be divided into 2 types, fenestral and retrofenestral, according to the topography of the lesions. The first is characterized by lesions preferentially located in the lateral wall of the otic capsule, i.e. the regions of the round and oval windows, promontory,



*Correspondence to: Dr An-Suey Shiao, Department of Otolaryngology, Taipei Veterans General Hospital, 201, Section 2, Shih-Pai Road, Taipei 112, Taiwan, R.O.C.

E-mail: asshiao@vghtpe.gov.tw • Received: April 29, 2009 • Accepted: July 14, 2009

and tympanic segment of the fallopian canal. The second is presence of otosclerotic foci in the other regions of the labyrinthine capsule, including the pericochlear region, the semicircular canals, internal acoustic meatus, vestibule, and cochlear and vestibular aqueducts.^{8,9} The area called the fissula ante fenestram, located just before the oval window, is the most common site involved with otosclerotic foci.

Otosclerosis is relatively rare in the Asian population. Compared with Caucasians, there is also relatively little literature discussing whether or not there are different characteristics of CT findings in oriental patients, especially in Taiwanese. The objectives of this study were to evaluate the tomographic findings of otosclerosis in Taiwanese patients, and to determine the value and necessity of HRCT scans of the temporal bone in the diagnosis of the disease in the Taiwanese population.

Methods

Subjects

In this retrospective study, clinically (otorhinolaryngologic exam, pure-tone audiometry and immittance measurement), surgically (evidence of stapedial fixation without any other remarkable cause) and pathologically confirmed otosclerosis patients were enrolled at the Department of Otorhinolaryngology-Head and Neck Surgery of Taipei Veterans General Hospital between June 2002 and December 2008. Patients with known congenital malformations, a history of chronic ear infections, previous operation, or sudden sensorineural hearing loss of the affected ear were excluded.

In addition, 15 patients, aged from 23 to 82 years and diagnosed with sudden sensorineural hearing loss, were enrolled as the control group. The enrolled control subjects were required to have no history of head trauma, middle ear disease or surgery, as defined by an oral history and otologic examination.

Methods

The initial workup for hearing loss included otoscopy, audiometry (pure-tone and speech), tympanogram, and stapedial reflex test. The preoperative air and bone conduction thresholds for the speech frequencies of 500, 1,000 and 2,000 Hz were recorded, and the ABGs (preoperative values) were calculated.

All of the recruited cases underwent preoperative HRCT of the temporal bones between June 2002 and December 2008, using a helical Sensation 16 CT scanner (Siemens, Berlin, Germany), Brilliance-40

CT scanner (Philips, Amsterdam, The Netherlands) or Aquilion Scanner (Toshiba, Tokyo, Japan) under the following parameters: slice thickness, 1 mm; interval, 1 mm; 120–250 mA, 120–140 mV, matrix of 512 × 512, and high-resolution bone algorithm between 3,400 and 4,500 Hounsfield units (HU) (window width) centered at 340–720 HU (window level). No intravenous contrast media was administered. The HRCT images (2 bone window settings with direct axial acquisition and coronal reformation) were reviewed on picture archiving and communication systems (PACS) workstations by 2 experienced otologists in a single-blinded study design, and inconsistencies were agreed upon by both specialists. PACS are computers or networks dedicated to the storage, retrieval, distribution and presentation of images. Reading on an imaging computer workstation, free zoom could be achieved. Otosclerotic lesions were characterized as hypodense areas in the otic capsule or by the presence of focal points of thickening and/or obliteration in the oval and round windows. Patients with positive results were divided into 2 groups: fenestral and retrofenestral otosclerosis.

Statistical analysis

Data for the radiologic findings, preoperative ABG, and duration of the disease were tested using Wilcoxon rank sum test. Fisher's exact test was used for a comparison between radiologic findings and type of hearing loss, and existence of vertiginous symptoms. Relationships between duration of the disease and preoperative ABG were calculated by correlation coefficients. Statistical significance was defined as $p < 0.05$. The software used for statistical analysis was STATA version 8.0 (Stata Corp., College Station, TX, USA) for Windows.

Results

Thirty-five subjects with a diagnosis of otosclerosis were recruited. Thirteen patients were excluded due to unavailability of CT scans. Finally, 22 subjects were enrolled (Table 1), including 14 (63.6%) females and 8 (36.4) males. Two subjects underwent surgery for bilateral lesions during the period, and thus the study consisted of 24 ears for analysis. Age at the time of operation ranged from 27 to 58 years (mean, 41.3 ± 10.13 years). Duration of the disease ranged from 1 month to 37 years (mean, 6.4 years). No patients had a family history of otosclerosis.

The CT scans were positive in 46% (11/24 ears) of the clinically, surgically and pathologically confirmed

Table 1. Clinical information of 22 patients with otosclerosis (24 ears)

No.	Age at surgery (yr)	Sex	Side	HL type	Preop ABG (dB)	Duration of disease (mo)	Radiologic finding	Vertigo
1	38	M	L	Mixed	30	120	–	–
2	51	F	L	Mixed	24	120	Fissula ante fenestram, SCD	–
3	58	M	R	Mixed	31	27	Pericochlear lucency	–
4	46	M	L	Mixed	26	12	Fissula ante fenestram	–
5	48	M	R	Mixed	29	84	Fissula ante fenestram	–
6	43	F	L	Conductive	32	1	–	–
7	28	F	R	Conductive	29	19	Pericochlear lucency	–
8	40	F	R	Conductive	24	1	Pericochlear lucency	+
9	51	M	R	Mixed	29	12	Fissula ante fenestram	–
10	51	F	R	Mixed	26	72	Fissula ante fenestram	+
11	50	F	R	Mixed	33	120	–	–
12	43	M	R	Conductive	20	144	–	–
13	31	F	R	Mixed	37	132	–	+
14	54	M	R	Mixed	25	120	–	–
15	28	F	L	Mixed	18	12	Fissula ante fenestram	–
	29		R	Mixed	15	36	Fissula ante fenestram	–
16	43	F	R	Mixed	35	120	–	–
17	28	F	L	Conductive	25	60	–	+
18	40	F	L	Mixed	33	120	–	–
19	52	M	L	Mixed	47	444	–	–
20	33	F	L	Conductive	25	12	–	+
21	27	F	R	Mixed	23	24	–	–
	27		L	Mixed	20	7	–	–
22	51	F	R	Mixed	13	24	Fissula ante fenestram	–

HL = hearing loss; Preop = preoperative; ABG = air–bone gap; M = male; F = female; L = left; R = right; SCD = superior canal dehiscence; + = present; – = absent.

otosclerotic ears. The fissula ante fenestram was the most prevalent site affected, in 72.7% of CT-positive ears (8/11 ears) (Figure 1), followed by pericochlear lucency (27.3%) (Figure 2). In 1 ear, thickening of the stapes footplate with oval window obliteration was observed (Figure 3). Furthermore, superior semi-circular canal dehiscence was noted in 1 ear.

Patients with presence of otosclerotic foci on imaging study had smaller preoperative ABGs than those with normal imaging results (24 ± 6.08 dB HL *vs.* 29.62 ± 7.68 dB HL; $p=0.098$) (Table 2). Compared with subjects who had positive CT scan findings, patients with undetected otosclerotic foci had a trend of longer duration of disease (109.54 ± 113.90 months *vs.* 38.09 ± 37.52 months; $p=0.065$) (Table 2). The duration of the disease tended to be greater in patients with larger preoperative ABG ($p=0.001$).

In addition, there was no significant association between radiologic findings and the type of hearing loss (conductive hearing loss or mixed hearing loss) ($p=0.647$, Fisher's exact test). No significant difference was observed between radiologic findings (normal, fenestral, retrofenestral) and vertiginous symptoms ($p=0.812$, Fisher's exact test).

The control group consisted of 15 patients (30 ears), including 6 men (40%) and 9 women (60%), ranging in age from 23 to 82 years (mean, 54.7 ± 17.67 years). No definite otosclerotic foci were identified in the control group.

Discussion

In the present study, CT was able to identify otosclerotic foci in 11/24 ears (46%). In the literature, various sensitivities of CT for the diagnosis of otosclerosis have been reported. In more recent studies, the rate of positive imaging results ranged from 77.7% to 100%.^{7,10,11} Japanese race has been implicated in a lower detection rate for otosclerotic foci of 54%.¹² Compared with otosclerosis patients of other ethnicities, Huang et al reported a positive radiographic rate of only 12% in patients with surgically confirmed clinical otosclerosis in a Chinese population in 1991.¹³ In contrast with Caucasians, the positive imaging rate in our study is similar to the rate in the abovementioned Japanese population, which might result from racial differences or delayed diagnosis of the disease.

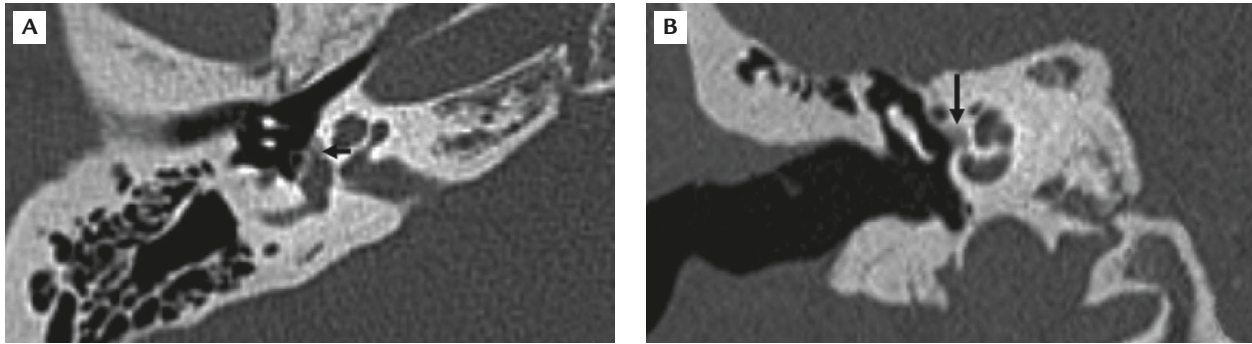


Figure 1. High-resolution computed tomography shows focus of hypodensity (arrows) at the fissula ante fenestram (anterior to the oval window): (A) axial view; (B) coronal view.

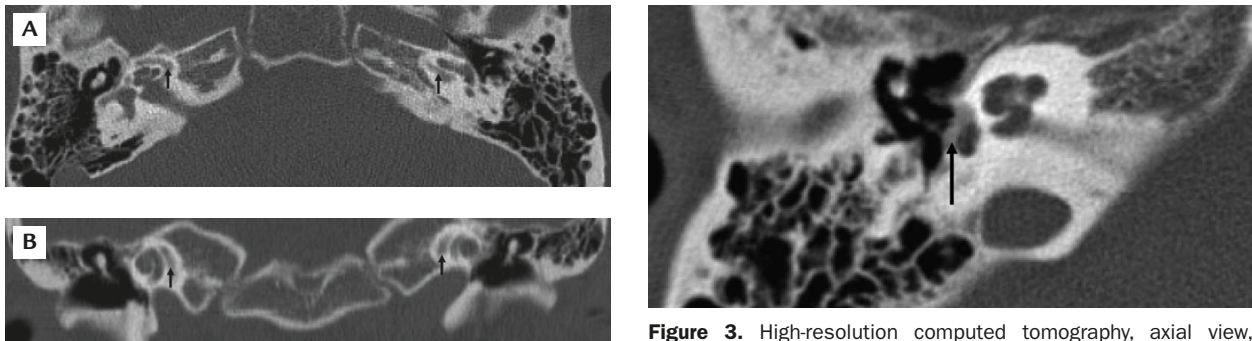


Figure 2. High-resolution computed tomography of a 28-year-old woman who underwent surgery for right otosclerosis: (A) axial view; (B) coronal view. The black arrows indicate pericochlear lucency on both sides.

Figure 3. High-resolution computed tomography, axial view, demonstrates thickening of the stapes footplate with oval window obliteration (arrow) in the right ear.

Table 2. Comparison of preoperative air–bone gap and duration of disease in patients with otosclerosis on tomographic findings

	CT+	CT–	<i>p</i> *
Ears (<i>n</i>)	11	13	
Preop ABG [†] (dB HL)	24 ± 6.08	29.62 ± 7.68	0.098
Duration of disease [†] (mo)	38.09 ± 37.52	109.54 ± 113.90	0.065

*Wilcoxon rank sum test; [†]data are presented as mean ± standard deviation. CT+ = presence of otosclerotic foci on high-resolution computed tomography (HRCT); CT– = absence of otosclerotic foci on HRCT; Preop = preoperative; ABG = air–bone gap.

Otosclerotic foci can be detected in HRCT scans by manual reading or via the workstation-based images. With reconstruction at workstation, Naumann et al found that the detection rate of otosclerotic foci increased by 11% (from 74% to 85%).⁷ Their findings demonstrate that CT scans should be read at the workstation, preferably with free zoom to decrease the rate of false-negative interpretation; the physician should not rely solely on printed films. Under these circumstances, we elevated the detection rate with better sensitivity, from 12% in Huang et al's report in 1991¹³ to 46% in the current study.

We calculated the preoperative ABG from air and bone conduction thresholds for the speech frequencies

of 500, 1,000 and 2,000 Hz. In the Mandarin-speaking Taiwanese population, speech reception thresholds correlate most significantly with pure-tone thresholds >0.5–2.0 kHz.¹⁴ Though the analysis did not demonstrate any significant correlation ($p < 0.05$), patients with the presence of otosclerotic foci on imaging did show trends of having smaller preoperative ABGs ($p = 0.098$) and a shorter duration of disease ($p = 0.065$) than those with normal imaging studies. The small number of cases involved in our study may be one of the reasons why the difference did not reach statistical significance. With the progression of the disease, the results demonstrated a significantly larger preoperative ABG in the patients. The aforementioned results

might provide some clues about the lower detection rate on HRCT for otosclerosis in Taiwanese.

Histomorphologically, active otosclerosis (otospongiosis) is diagnosed in the presence of hypodense or radiolucent foci of demineralization in the otic capsule. Otospongiosis is the early (active) phase of otosclerotic lesions. As the disease progresses, it shifts to the late (inactive) phase of otosclerosis with new spongy bone formation. False-negative radiologic findings may result from inactive otosclerotic foci having the same density as adjacent bone. Accordingly, the foci are undetected. On the other hand, it is easier to detect lesions from active otospongiosis because their density is lower than that of the otic capsule. In addition, there are also other disorders, such as ankylosis or fibrous changes of the annular ligament, as described by Cherukupally et al, that can cause significant ABGs without being detected on CT.¹⁵

Hence, from this and previous studies, we can conclude that CT scans have some limitations in detecting otosclerotic foci. False-negative data may result from inframillimeter lesions, inactive otosclerotic foci and density variations of less than 200 HU which are invisible to the naked eye.¹⁶

Furthermore, the lower detection rate also represents a greater percentage of patients with late-phase otosclerosis, which might be a result of longer duration of disease or ethnic variation. About 10% of Caucasians have histologic findings of otosclerosis. However, of those with histologic changes, only 12% have clinical symptoms; thus, overall, this represents about 1% of the Caucasian population. Joseph and Frazer found clinical otosclerosis to be 2.1 times less frequent among the Japanese population in Hawaii than in Caucasians.¹⁷ Moreover, the disease was found to be 2.5 times less frequent in Chinese compared with Caucasians.¹⁷ Huang and Lee¹⁸ also reported that 1.13% of a Chinese population treated for hearing impairment had clinical otosclerosis, compared with 50% among Caucasians as reported by Nager.¹⁹

The rarity of otosclerosis in Asians has led to there being fewer experienced otologists in the field of stapes surgery, and those doctors tend to take a less aggressive attitude (surgery) toward the disease. Meanwhile, most patients in Taiwan prefer conservative management (hearing aid or follow-up) instead of surgical intervention with its potential risks. Due to these factors, the duration of the disease is longer, resulting in a greater proportion of patients who will present with a late phase of otosclerosis.

Although the detection rate of otosclerotic foci on HRCT with axial/coronal views and PACS workstations for Taiwanese is not as high as that for

Caucasians, the images are valuable for a precise preoperative evaluation and may be used to exclude patients who have a high surgical risk or other causes of conductive hearing loss, such as superior semicircular canal dehiscence, congenital ossicular chain anomalies, primary cholesteatoma, gusher syndrome, tympanic facial nerve neuroma blocking the stapes and so on.

In conclusion, our study suggests that HRCT has high specificity (100%) but low sensitivity (46%) for the diagnosis of otosclerosis in Taiwanese.^{7,10,11} The main cause of the low CT-positive rate compared with rates reported in the Western literature might stem from a greater percentage of inactive otosclerosis in our patients.

References

- Gros A, Vatovec J, Sereg-Bahar M. Histologic changes on stapedial footplate in otosclerosis: correlations between histologic activity and clinical findings. *Otol Neurotol* 2003;24:43-7.
- Yoon TH, Paparella MM, Schachern PA. Otosclerosis involving the vestibular aqueduct and Meniere's disease. *Otolaryngol Head Neck Surg* 1990;103:107-12.
- Schuknecht HF, Barber W. Histologic variants in otosclerosis. *Laryngoscope* 1985;95:1307-17.
- Hannley MT. Audiologic characteristics of the patient with otosclerosis. *Otolaryngol Clin North Am* 1993;26:373-87.
- Yang TL, Young YH. Vestibular-evoked myogenic potentials in patients with otosclerosis using air- and bone-conducted tone-burst stimulation. *Otol Neurotol* 2007;28:1-6.
- Roland PS, Meyerhoff WL. Otosclerosis. In: Bailey BJ, ed. *Otolaryngology-Head and Neck Surgery*, 4th ed. Philadelphia: Lippincott Williams & Wilkins, 2006:2129.
- Naumann IC, Porcellini B, Fisch U. Otosclerosis: incidence of positive findings on high-resolution computed tomography and their correlation to audiological test data. *Ann Otol Rhinol Laryngol* 2005;114:709-16.
- Valvassori GE. Imaging of the otosclerosis. *Otolaryngol Clin North Am* 1993;26:359-71.
- Swartz JD, Faerber EN, Wolfson RJ, Marlowe FI. Fenestral otosclerosis: significance of preoperative CT evaluation. *Radiology* 1984;151:703-7.
- Vicente Ade O, Yamashita HK, Albernaz PL, Penido Nde O. Computed tomography in the diagnosis of otosclerosis. *Otolaryngol Head Neck Surg* 2006;134:685-92.
- Chammakhi-Jemli C, Ben Hassine L, Daghfous A, Shili-Briki S, Mzabi H, Mbarek C, Lekhdim A, et al. CT findings in otosclerosis: a series of 11 cases. *Tunis Med* 2006;84:177-81.
- Kiyomizu K, Tono T, Yang D, Haruta A, Kodama T, Komune S. Correlation of CT analysis and audiometry in Japanese otosclerosis. *Auris Nasus Larynx* 2004;31:125-9.
- Huang TS, Lee FP, Chen LK. Radiographically confirmed cochlear otospongiosis among the Chinese. *Ann Otol Rhinol Laryngol* 1991;100:232-5.
- Chien CH, Tu TY, Shiao AS, Chien SF, Wang YF, Li AC, Yang MJ. Prediction of the pure-tone average from the speech reception and auditory brainstem response thresholds in a Chinese data. *ORL* 2008;70:366-72.

15. Cherukupally SR, Merchant SN, Rosowski JJ. Correlations between pathologic changes in the stapes and conductive hearing loss in otosclerosis. *Ann Otol Rhinol Laryngol* 1998;107:319–26.
16. Huizing EG, de Groot JAM. Densitometry of the cochlear capsule and correlation between bone density loss and bone conduction hearing loss in otosclerosis. *Acta Otolaryngol* 1987;103:464–8.
17. Joseph BP, Frazer JP. Otosclerosis incidence in Caucasians and Japanese. *Arch Otolaryngol* 1964;80:256–62.
18. Huang TS, Lee FP. Surgically confirmed clinical otosclerosis among the Chinese. *Arch Otolaryngol Head Neck Surg* 1988; 114:538–44.
19. Nager GT. Histopathology of otosclerosis. *Arch Otolaryngol Head Neck Surg* 1969;89:341–63.