

Gastric Necrosis and Perforation as a Severe Complication of Pancreatic Pseudocyst

Chia-Yang Hsu^{1,4}, Kuei-Chuan Lee¹, Che-Chang Chan^{1,3*}, Fa-Yauh Lee^{2,3}, Han-Chieh Lin^{1,3}

Divisions of¹Gastroenterology and²General Medicine, Department of Medicine, Taipei Veterans General Hospital, and³National Yang-Ming University School of Medicine, Taipei, and⁴Division of Gastroenterology, Department of Medicine, National Yang-Ming University Hospital, Yilan, Taiwan, R.O.C.

Patients with acute pancreatitis may present with stress-related gastrointestinal mucosal lesions. But severe gastrointestinal complications such as gastric perforation are very rare. Here, we report a 40-year-old man who was admitted due to acute pancreatitis and pseudocyst formation. During hospitalization, panendoscopic examination found multiple scattered stress ulcers over the gastric antrum and a large ulcerative area with suspicious malignant features at the body and fundus. The patient received surgical intervention due to worsening of his clinical condition. Postoperative findings showed a perforation of the gastric wall at the region in contact with the pseudocyst, and microscopic examination found diffuse ischemia and necrosis with intravascular thrombus and emboli in gastric vessels. We suggest keeping in mind that pancreatic pseudocyst may cause serious gastrointestinal complications including massive necrosis and perforation of the gastric wall. [*J Chin Med Assoc* 2009;72(11):603–606]

Key Words: gastric perforation, pancreatitis, pseudocyst

Introduction

Acute pancreatitis is a rapid-onset inflammatory process of the pancreas. It is commonly related to gallstone, alcoholism, hyperlipidemia or other causes. Acute pancreatitis may lead to severe systemic complications involving the lung, kidney and gastrointestinal tract. Previous studies reported that more than half of patients with acute pancreatitis might present with upper gastrointestinal mucosal lesions.^{1,2} Acute gastrointestinal mucosal lesions in patients with acute pancreatitis can range from simple gastritis and erosions to ulceration or bleeding. However, severe gastric necrosis with perforation is rarely encountered. Here, we report a case of acute pancreatitis and pseudocyst formation complicated with gastric perforation caused by ischemic mucosal injury.

Case Report

This 40-year-old man visited our hospital due to fever, abdominal fullness and intermittent epigastric pain for

3 days after binge alcohol intake. On admission, he was found to have mild fever of 37.8°C and tenderness over the left upper quadrant of his abdomen. The patient complained of cramping pain with stabbing feeling without precipitating or alleviating factors. Persistent compressing sensation was noted at the same time. The patient denied radiation or referral of pain or other concomitant extra-abdominal discomfort. There was no palpable abdominal mass or rebounding pain found during physical examination. The patient had past histories of hepatitis B and hepatitis C virus-related liver cirrhosis and type 2 diabetes mellitus. He was a heavy smoker and his daily alcohol consumption was ≥ 40 g for the past 2 decades.

Initially, laboratory studies showed leukocytosis (white blood cell count, 18,700/mm³), elevated liver enzymes (aspartate aminotransferase, 74 U/L) and positive fecal occult blood test. His serum lipase level was mildly elevated (236 U/L). Upper gastrointestinal panendoscopic examination showed multiple small clean-based ulcers at the antrum (Figure 1A) and a giant ulcer over the greater curvature side of the body extending upward to the fundus (Figures 1B and 1C).



ELSEVIER

*Correspondence to: Dr Che-Chang Chan, Division of Gastroenterology, Department of Medicine, Taipei Veterans General Hospital, 201, Section 2, Shih-Pai Road, Taipei 112, Taiwan, R.O.C.
E-mail: ccchan@vghtpe.gov.tw • Received: April 27, 2009 • Accepted: October 12, 2009

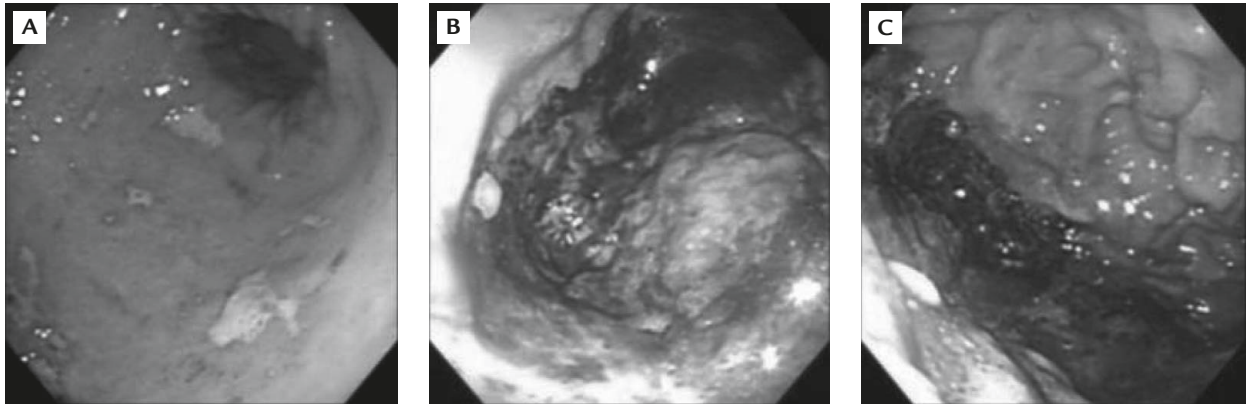


Figure 1. Endoscopic findings. (A) Several small clean-based ulcers at the antrum. (B, C) A giant area of necrosis and ulceration over the body with extension up to the fundus of the stomach. Massive mucosal sloughing and necrosis were found.

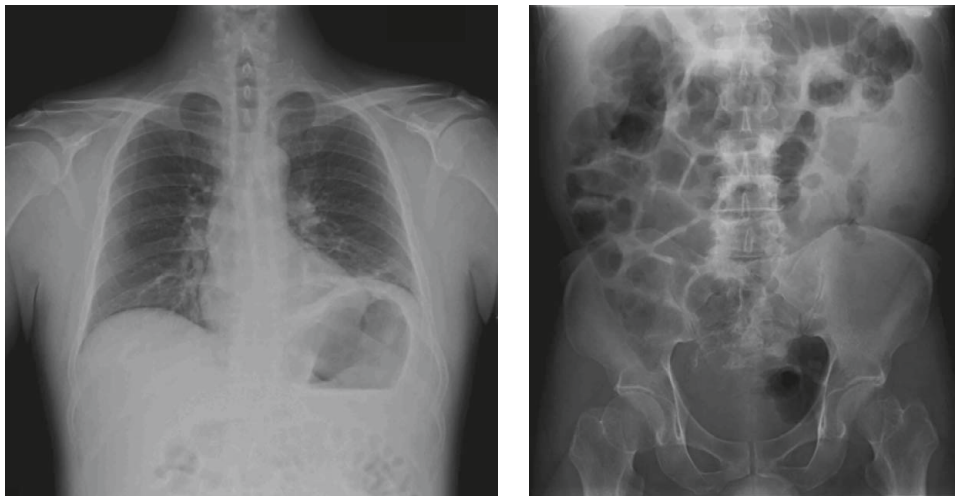


Figure 2. Chest and abdominal X-rays on admission showed no soft tissue lesion but only ileus and bowel gas.

This wide gastric ulcer presented with a dirty base, irregular margins and nodular surface. Also, massive necrosis, sloughing of epithelium and darkish discoloration of surrounding mucosa were observed. Physical examination after the endoscopic procedure found no evidence of hollow organ perforation-related signs.

Although gastric malignancy was suspected, endoscopic biopsies demonstrated inflammatory exudate with chronic inflammatory cell infiltration in the lamina propria. There was no *Helicobacter pylori* infection. Routine X-rays of the chest and abdomen showed ileus without definite soft tissue lesion or intra-abdominal free air (Figure 2). Abdominal sonography disclosed a cystic lesion over the left upper quadrant of the abdomen near the splenic hilum. Magnetic resonance imaging and computed tomography of the abdomen revealed pancreatitis with regional edematous change and a cystic lesion measuring 8.8×4.8 cm in size located at the pancreatic tail (Figure 3). Chronic pancreatitis with pseudocyst formation was diagnosed. After cessation of

oral intake and intravenous fluid supplement for 1 week, aggravated abdominal pain accompanied by unstable vital signs developed. Surgical intervention was performed under the impression of pseudocyst rupture with hemo-peritoneum.

Hemorrhagic and necrotizing pancreatitis with distal pancreatic pseudocyst was recognized by the surgeons. Moreover, it was found that the greater curvature of the stomach was eroded to perforation by the pancreatic pseudocyst. The patient received distal pancreatectomy, splenectomy and subtotal gastrectomy with B-II anastomosis uneventfully. Macroscopic pathologic inspection disclosed a large gangrenous area measuring 14×5 cm and gastric perforation measuring 4×3 cm. Microscopic findings showed diffuse ischemia and necrosis with thrombus and emboli in gastric vessels (Figures 4 and 5). There were also fat necrosis, hemorrhage and inflammatory cell infiltration in the omentum. The operation was executed smoothly, and wound healing, postoperative care and nutrition restoration were uneventful.

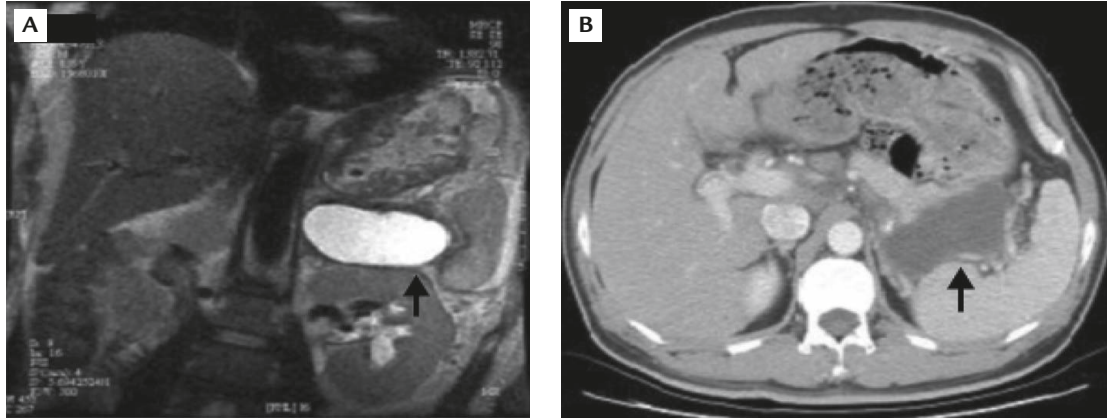


Figure 3. (A) Magnetic resonance imaging and (B) computed tomography of the abdomen revealed pancreatitis with regional edematous change and a cystic lesion measuring 8.8×4.8 cm in size at the pancreatic tail.

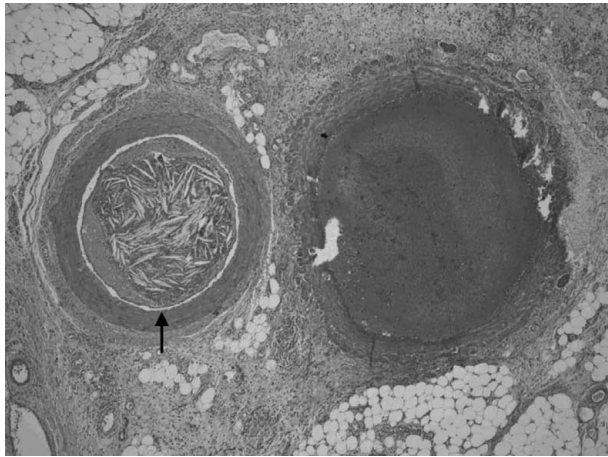


Figure 4. Microscopic examination shows emboli in gastric vessel (hematoxylin & eosin, $100\times$).

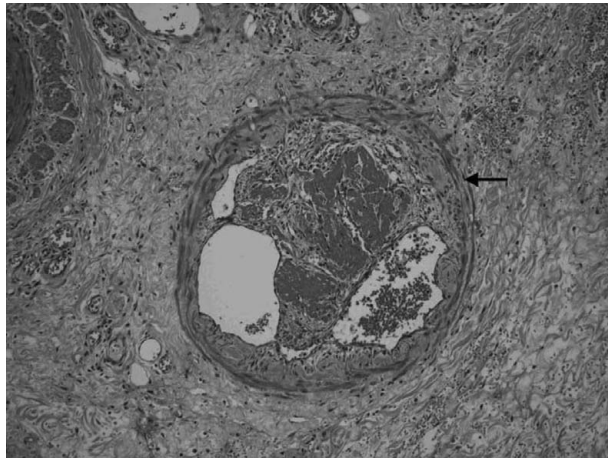


Figure 5. Microscopic examination shows thrombosis formation in gastric vessel (hematoxylin & eosin, $100\times$).

Discussion

It has been proposed that acute gastrointestinal mucosal lesions under stress condition tend to occur as multiple

shallow ulcers located frequently at the fundus.³ In our patient, endoscopic examination showed multiple scattered small ulcers at the antrum. These ulcers might, in part, be related to the stressful condition due to acute pancreatitis. However, the morphology and location of the other giant ulcer, which mainly involved the gastric body, were apparently different. Ulcerative crater was not found by endoscopic study; in addition, the distinct dark discoloration, irregular margins and sloughing of epithelial tissue implied an uncommon underlying etiology and mechanism of mucosal injury.

Acute gastrointestinal mucosal lesion is one of the complications of acute pancreatitis. Previous reports have shown that 50–65% of patients with acute pancreatitis may have acute gastrointestinal mucosal lesions.^{1,2} The majority of ulcers are located in the stomach and duodenum, and concomitant esophageal ulcers are not uncommon.^{1,4} The occurrence of acute mucosal injury is unrelated to the etiologies of acute pancreatitis.^{1,2} Whether or not the incidence of acute ulcers is higher in severe cases of pancreatitis remains open to debate.² Because the manifestations of pancreatitis and ulcer disease are hard to distinguish from each other, it is suspected that, in clinical practice, there is an underestimation of the number of acute mucosal lesions caused by pancreatitis.

Due to worsening of his clinical condition, our patient underwent surgical intervention. The postoperative findings showed gangrenous change of the gastric wall with perforation. The development of gastric perforation might be the underlying mechanism that explains the extreme pain our patient suffered after 1 week of intensive treatment. According to previous reports, the gastrointestinal complications of pancreatitis include ileus, obstruction, regional bowel edema, ischemic necrosis and intramural hematoma.⁵ Severe complications such as colonic

perforation and subsequent peritonitis have been mentioned.⁶ However, gastric perforation associated with pseudocyst has never been described. Chometowski et al⁷ reported a patient with both gastric and colonic perforation; intravascular coagulation was proposed as the possible mechanism of perforation. Kubo et al⁸ described a patient with acute pancreatitis who presented with hematemesis and gastric perforation, which was caused by gastric erosion and rupture of a pseudoaneurysm. Recently, Kirschniak et al⁹ reported a patient with necrotizing pancreatitis who received laparoscopic necrosectomy and highlighted the development of delayed gastric perforation of the stomach. In our case, the diffusely gangrenous ischemic change and microscopic vascular thromboemboli formation over the region of perforation were suggestive of a lack of mucosal perfusion. Given the normal coagulation profiles (prothrombin time and international normalized ratio, 1.03; activated partial thromboplastin time, 28 seconds [normal range, 25–33 seconds]) and adequate platelet count (150,000/mm³) on the day of operation, there was no evidence of disseminated intravascular coagulation in this patient. In combination with the imaging studies and surgical findings, the compromised blood supply could either be due to physical compression of the pseudocyst or to the severe regional inflammatory process promoted by cytokines released from the pancreatitis.

Although one third or more of pancreatic pseudocysts resolve spontaneously, interventional therapy is needed for persistent direct compression, suspicion of pseudocyst rupture or complicated cyst with abscess formation. Percutaneous drainage, endoscopic transpapillary drainage, or surgical resection may be used to treat pseudocyst according to different conditions such as location, size of the pseudocyst and general condition of the individual patient.¹⁰ Traditionally, the management of gastric perforation is mainly surgical. With improvements in endoscopic therapeutic techniques, it is now feasible to close gastric perforations using endoscopic clipping devices.^{9,11–13} A case report has demonstrated that gastric perforation in necrotizing pancreatitis can be successfully treated with endoscopic clips.⁹ However, the experience of endoscopic clip treatment for gastric perforation secondary to intra-abdominal inflammation such as pancreatitis is insufficient, and further investigation is needed.

In conclusion, pseudocyst development in acute pancreatitis may compromise the functional integrity of adjacent organs. It would be prudent to bear in mind that pancreatic pseudocyst may cause severe gastrointestinal complications, including massive ischemic necrosis and perforation of the gastric wall.

References

1. Lin CK, Wang ZS, Lai KH, Lo GH, Hsu PI. Gastrointestinal mucosal lesions in patients with acute pancreatitis. *J Chin Med Assoc* 2002;65:275–8.
2. Chen TA, Lo GH, Lin CK, Lai KH, Wang HY, Yu HC, Hsu PI, et al. Acute pancreatitis-associated acute gastrointestinal mucosal lesion: incidence, characteristics, and clinical significance. *J Clin Gastroenterol* 2007;41:630–4.
3. Cook DJ. Stress ulcer prophylaxis: gastrointestinal bleeding and nosocomial pneumonia: best evidence synthesis. *Scand J Gastroenterol Suppl* 1995;210:48–52.
4. Chebli JM, de Souza AF, Gaburri PD, Bastos KV, Ribeiro TC, Filho RJ, Chebli LA, et al. Prevalence and pathogenesis of duodenal ulcer in chronic alcoholic pancreatitis. *J Clin Gastroenterol* 2002;35:71–4.
5. Chen CY, Lu CL, Chang FY, Lee SD. Duodenal lesions following severe acute pancreatitis: review of 10 years' clinical experience. *Hepatogastroenterology* 2001;48:869–71.
6. Calleja Subiran MC, Urien Blazquez LM. Colonic perforation, a rare complication of acute necrotizing pancreatitis. *An Med Interna* 2006;23:235–7. [In Spanish]
7. Chometowski S, Bourde J, Assadourian R, Pietri H, Lamy J. Double gastric perforation and colonic perforation during necrotizing pancreatitis submitted to arteriography. *Ann Chir* 1976;30:621–4.
8. Kubo K, Nakamura H, Hirohata Y, Abe S, Onari N, Otsuki M. Ruptured aneurysm and gastric perforation associated with acute pancreatitis: a rare cause of hematemesis. *Gastrointest Endosc* 2001;53:658–60.
9. Kirschniak A, Kueper T, Stuker K, Konigstrainer S, Kratt K. Endoscopic treatment of gastric perforation caused by acute necrotizing pancreatitis using over-the-scope clips: a case report. *Endoscopy* 2007;39:1100–2.
10. Bhattacharya D, Ammori BJ. Minimally invasive approaches to the management of pancreatic pseudocysts: review of the literature. *Surg Laparosc Endosc Percutan Tech* 2003;13:141–8.
11. Binmoeller KF, Grimm H, Soehendra N. Endoscopic closure of a perforation using metallic clips after snare excision of a gastric leiomyoma. *Gastrointest Endosc* 1993;29:172–4.
12. Albuquerque W, Arantes V. Large gastric perforation after endoscopic mucosa resection treated by application of metallic clips (video). *Endoscopy* 2004;36:752–3.
13. Minami S, Gotada T, Ono H, Oda I, Hamanaka H. Complete endoscopic closure of gastric perforation induced by endoscopic resection of early gastric cancer using endoclips can prevent surgery (with video). *Gastrointest Endosc* 2006;63:596–601.