

A Cardiac Pseudo-tumor Associated With Pseudo-infarction Electrocardiographic Pattern

Tze-Fan Chao, Shih-Hsien Sung*

Division of Cardiology, Department of Medicine, Taipei Veterans General Hospital, and National Yang-Ming University School of Medicine, Taipei, Taiwan, R.O.C.

The electrocardiographic presentation of Q waves is an important diagnostic indication of myocardial infarction and other differential diagnoses. We report a case in which the electrocardiography revealed significant Q waves in V1 to V4. In addition, echocardiography disclosed an encapsulated mass lesion over the interventricular septum. Rather than confirm a cardiac tumor, magnetic resonance imaging disclosed hypertrophy of the myocardium with the ventricular septum showing prominent thickness >3 cm. Hypertrophic cardiomyopathy was diagnosed. Cardiac pseudo-tumor with a pseudo-infarction electrocardiography pattern can be a rare presentation of hypertrophic cardiomyopathy. [*J Chin Med Assoc* 2009;72(12):643–645]

Key Words: cardiac pseudo-tumor, hypertrophic cardiomyopathy, pseudo-infarction electrocardiography pattern

Introduction

Abnormal cardiac masses (tumors, thrombi, and vegetations) are usually life-threatening and therefore must be distinguished from normal cardiac structures to avoid inappropriate medical therapy and even inappropriate surgery. The Eustachian valve, Chiari network, crista terminalis, pectinate muscles, moderator band, trabeculations, interatrial septal aneurysm, and lipomatous hypertrophy of the interatrial septum are examples of normal structures that are frequently mistaken for pathologic entities.¹ However, careful examination usually results in correct identification. Here, we report a case with an interventricular cardiac mass and pseudo-infarction electrocardiography pattern in which a hypertrophic cardiomyopathy rather than a cardiac tumor was diagnosed by cardiac magnetic resonance imaging.

Case Report

A 24-year-old man was accidentally found to have a cardiac murmur and was referred from a local clinic. On history taking, the patient stated that he did not

have any systemic disease such as diabetes, hypertension or hyperlipidemia, did not smoke, and did not have a family history of arrhythmia, congenital heart disease or sudden cardiac death. Cardiac auscultation disclosed only grade II/VI systolic murmur at the left upper sternal border. Electrocardiography revealed significant Q waves in V1 to V4, indicative of an old anteroseptal myocardial infarction (Figure 1A). The patient did not have dyspnea, chest pain, syncope or other symptoms. A treadmill exercise test showed no evidence of ischemic heart disease. The following echocardiography disclosed an encapsulated mass lesion over the interventricular septum with systolic anterior motion of the mitral leaflet (Figures 1B–1D). However, there was no pressure gradient in the left ventricular outflow tract, and there was increased flow velocity of the right ventricular outflow tract, 130 cm/sec, indicating a peak pressure gradient of 7 mmHg. The measured area of the mass lesion in parasternal long-axis view was 9.42 cm². No skin lesions or past seizure episodes were noted. Magnetic resonance imaging showed no obvious signal change or anomalies on T1-weighted and T2-weighted imaging but did show hypertrophy of the myocardium with prominent thickening (>3 cm) of the ventricular septum (Figures 1E



*Correspondence to: Dr Shih-Hsien Sung, Division of Cardiology, Department of Medicine, Taipei Veterans General Hospital, 201, Section 2, Shih-Pai Road, Taipei 112, Taiwan, R.O.C.
E-mail: shsang@vghtpe.gov.tw • Received: July 15, 2009 • Accepted: October 27, 2009

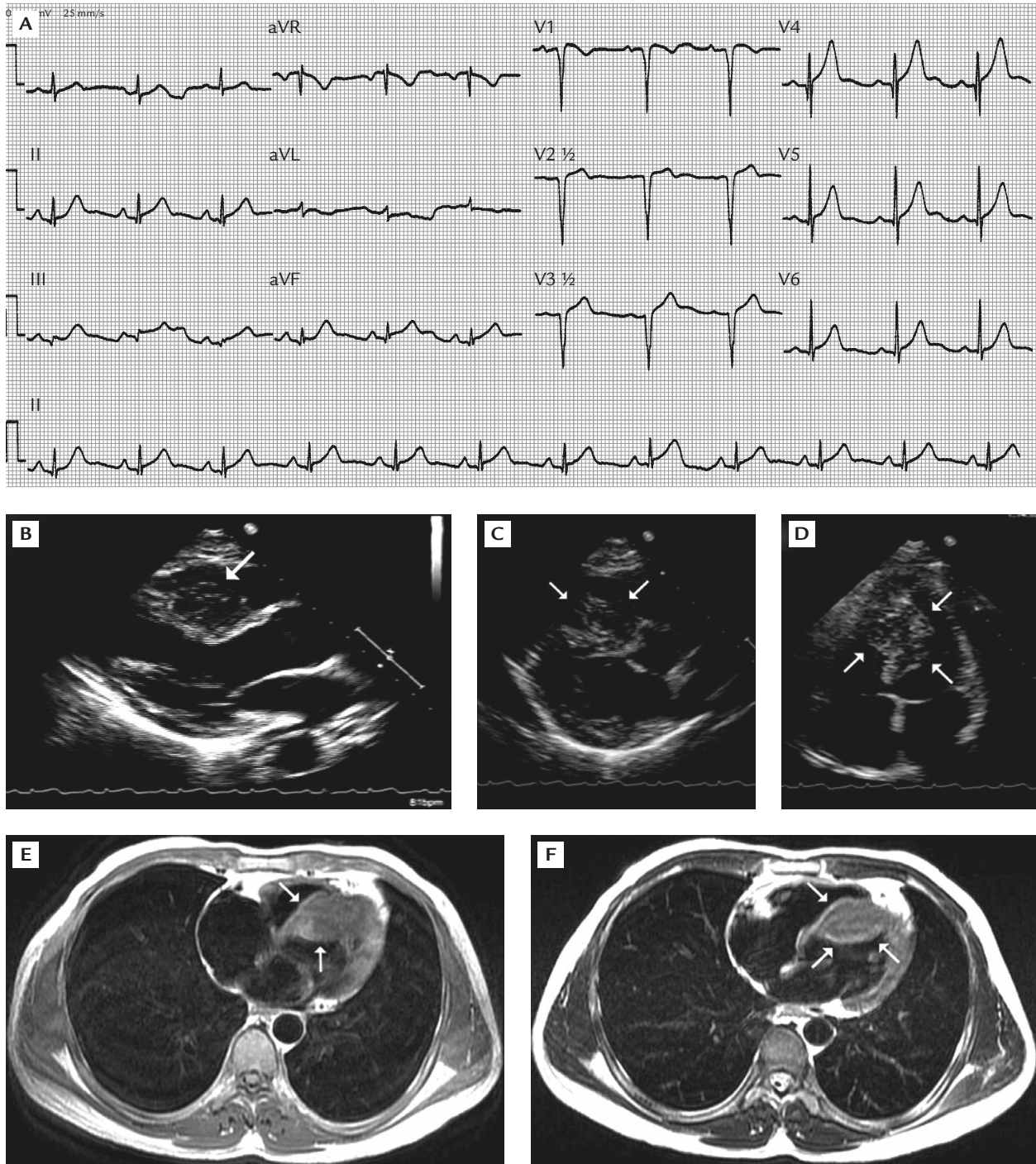


Figure 1. (A) Q wave electrocardiography pattern in V1 to V4. Interventricular septal mass lesion is shown on transthoracic echocardiography in: (B) parasternal long-axis view; (C) parasternal short-axis view; and (D) apical 4-chamber view. Heart magnetic resonance imaging shows hypertrophy of the myocardium with prominent thickness >3 cm of the ventricular septum: (E) T1-weighted imaging; (F) T2-weighted imaging.

and 1F). Hypertrophic cardiomyopathy with right ventricular outflow tract obstruction instead of cardiac tumor was diagnosed. Specific management was not given, and the patient was followed-up at the outpatient department.

Discussion

Cardiac mass lesion found by echocardiography may have various etiologies. Myxomas are the most common benign cardiac tumors, accounting for 30% of all

primary cardiac tumors. They most commonly occur in the left atrium (75%), but can arise in the right atrium (23%) or the ventricles (2%).² Lipomas are the second most common benign cardiac tumors (with a frequency of 10% of benign cardiac tumors),¹ and are usually seen in the left ventricle, right atrium, and interatrial septum. A quarter of all cardiac tumors are malignant, the majority of which are angiosarcomas or rhabdomyosarcomas.³ The presence of atrial fibrillation, poor left ventricular systolic function, and left ventricular aneurysm—all risk factors of intracardiac thrombi—can also be misinterpreted as a cardiac tumor. Some rare conditions, such as hypertrophic ventricular septum, can also be mistaken for a cardiac tumor, as seen in our case. In contrast, a true cardiac tumor located at the interventricular septum may be mistaken for a septal hypertrophic cardiomyopathy on echocardiography unless further tests are carried out.⁴

The outcome of hypertrophic cardiomyopathy depends on whether it causes left ventricular outflow tract obstruction. For patients with obstructive hypertrophic cardiomyopathy but without severe cardiac symptoms, the hazard ratio of all-cause mortality is 1.01 for every 1 mmHg increase in the resting left ventricular outflow tract pressure gradient.⁵ However, hypertrophic cardiomyopathy with right ventricular outflow obstruction is very rare, and there are no reported prognostic factors of hypertrophic cardiomyopathy with right ventricular outflow tract obstruction.⁶

The cause of abnormal Q waves in hypertrophic cardiomyopathy remains controversial. Two main mechanisms have been proposed based on intracoronary electrophysiological studies. One is loss of electrical forces due to transmural myocardial fibrosis, and the other is altered direction of the resultant initial QRS

vector due to increased electrical forces of the disproportionately hypertrophic ventricular wall.^{7,8} The disproportional thickness of the upper anterior septum plays an important role in the prevalence of abnormal Q waves in precordial electrocardiography.⁸

Any patient with atypical presentation of ventricular hypertrophy that mimics a cardiac tumor should be assessed carefully for the possibility of malignant transformation during follow-up.

References

1. Ragland MM, Tak T. The role of echocardiography in diagnosing space-occupying lesions of the heart. *Clin Med Res* 2006;4: 22–32.
2. Meng Q, Lai H, Lima J, Tong W, Qian Y, Lai S. Echocardiographic and pathologic characteristics of primary cardiac tumors: a study of 149 cases. *Int J Cardiol* 2002;84:69–75.
3. Shapiro LM. Cardiac tumours: diagnosis and management. *Heart* 2001;85:218–22.
4. Wage R, Kafka H, Prasad S. Cardiac rhabdomyoma in an adult with a previous presumptive diagnosis of septal hypertrophy. *Circulation* 2008;117:e469–70.
5. Sorajja P, Nishimura RA, Gersh BJ, Dearani JA, Hodge DO, Wiste HJ, Ommen SR. Outcome of mildly symptomatic or asymptomatic obstructive hypertrophic cardiomyopathy: a long-term follow-up study. *J Am Coll Cardiol* 2009;54:234–41.
6. Satoh R, Okada T, Oimatsu H, Sawai K, Ogawa T, Tuchida A. A case of hypertrophic cardiomyopathy with right ventricular outflow obstruction manifested during three-year follow-up study. *Kokyu To Junkan* 1990;38:913–7.
7. Koga Y, Yamaga A, Hiyamuta K, Ikeda H, Toshima H. Mechanisms of abnormal Q waves in hypertrophic cardiomyopathy assessed by intracoronary electrocardiography. *J Cardiovasc Electrophysiol* 2004;15:1402–8.
8. Lemery R, Kleibenne A, Nihoyannopoulos P, Aber V, Alfonso F, McKenna WJ. Q waves in hypertrophic cardiomyopathy in relation to the distribution and severity of right and left ventricular hypertrophy. *J Am Coll Cardiol* 1990;16:368–74.