

Primary Hyperparathyroidism With Brown Tumor Mimicking Metastatic Bone Malignancy

Alvin W. Su^{1,3}, Cheng-Fong Chen^{1,3}, Ching-Kuei Huang^{1,3}, Paul Chih-Hsueh Chen²,
Wei-Ming Chen^{1,3*}, Tain-Hsiung Chen^{1,3}

Departments of¹Orthopedics and Traumatology, and²Pathology, Taipei Veterans General Hospital, and³Department of Surgery, National Yang-Ming University School of Medicine, Taipei, Taiwan, R.O.C.

Bone and joint pain are commonly encountered conditions in daily practice. In the elderly, when osteolytic lesions are identified in imaging studies, metastatic bone tumor is the first impression that comes to the clinician's mind. Although the worst-case scenario should be ruled in, other differential diagnoses such as metabolic bone disease should be considered as well. We report a case of brown tumor caused by parathyroid adenoma. The patient had initial presentation of diffuse bone pain and multiple osteolytic lesions on imaging studies similar to metastatic bone tumor. With a systematic approach and awareness of metabolic bone disease, an accurate diagnosis was finally reached. Appropriate treatments, including preventive internal fixation of the impending femoral fracture and surgical excision of the parathyroid adenoma were performed accordingly. The key treatment for the condition was surgical excision of the parathyroid adenoma. After normalization of serum intact-parathyroid hormone level, the bony lesions resolved and required no further orthopedic surgery. The patient is now symptom-free. In addition to suspecting malignancy, the clinician should be highly alert to other possible causes of bony lesions. Brown tumor should be kept in mind during daily practice. [*J Chin Med Assoc* 2010;73(3):177-180]

Key Words: bone neoplasm, brown tumor, hypercalcemia, metabolic bone disease, parathyroid adenoma

Introduction

Bone and soft tissue tumors are pitfalls in general orthopedic practice. Early diagnosis of the disease can lead to effective treatment strategy and significantly improve patient outcome.¹ In daily orthopedic practice, hip and groin pain are commonly attributed to arthritis or soft tissue inflammation.² An unusual pain pattern will commonly alert the clinician to underlying malignancies but not to metabolic bone disease. When multiple osteolytic lesions are seen on plain films, routine studies such as serum electrolyte and parathyroid hormone (PTH) levels are often neglected as suspicion of metastatic bone malignancies directly leads attending physicians to tumor survey imaging studies. We herein present a case of parathyroid adenoma and subsequent brown tumor of the bone that presented with persistent bone pain and that was initially misdiagnosed as metastatic bone tumor.

Case Report

A 67-year-old male who had been a farmer for decades visited our office complaining of persistent right groin pain, left thigh pain and left upper arm soreness for over 2 years. He had been diagnosed with right hip joint osteoarthritis by a local health care provider. Nonsteroidal anti-inflammatory drugs had been prescribed, but there was only slight relief of the symptoms. Follow-up X-ray taken at a local hospital showed multiple osteolytic lesions in the pelvic area. He was referred to our institution under the impression of metastatic bone tumor.

The patient's medical history was significant only for thalassemia minor. The pain had been persistent and progressing with variable severity. Visual analog scale pain score ranged from 5 to 7; the pain was exaggerated when walking or standing, but was slightly better when lying in bed. The pain disturbed him during sleep



*Correspondence to: Dr Wei-Ming Chen, Department of Orthopedics and Traumatology, Taipei Veterans General Hospital, 201, Section 2, Shih-Pai Road, Taipei 112, Taiwan, R.O.C.
E-mail: wmchen@vghtpe.gov.tw • Received: May 14, 2009 • Accepted: January 14, 2010

from time to time. On physical examination, Patrick test was positive for right hip, and mild limping gait was noted. There was no local tenderness or pattern of radiation. No neurovascular deficit was identified. Serial plain film examination revealed multiple well-defined pure osteolytic lesions in the pelvic girdle and both proximal femoral shafts, as well as in the skull (salt-and-pepper pattern) and left humeral shaft (Figure 1).

Considering the patient's old age and the clinical manifestations, serial imaging and laboratory studies were conducted in light of the possibility of multiple bony metastatic lesions. Magnetic resonance imaging of the pelvis showed low signals on both T1-weighted

and T2-weighted images of multiple pure osteolytic lesions. Whole-body bone scan showed multiple uptakes over the skull, left humerus, the pelvic girdle and the ribs (Figure 2). Although all of the above findings indicated metastatic bone tumor, the levels of tumor markers (α -fetoprotein, prostate-specific antigen, carcinoembryonic antigen) were all within normal limits. Computed tomography of the chest and abdomen to search for the tumor origin showed no abnormalities. At this point, all the clinical evidence rationally indicated a diagnosis of metastasis of unknown origin.

Laboratory studies, however, unveiled the differential diagnosis of metabolic bone disease. Blood cell

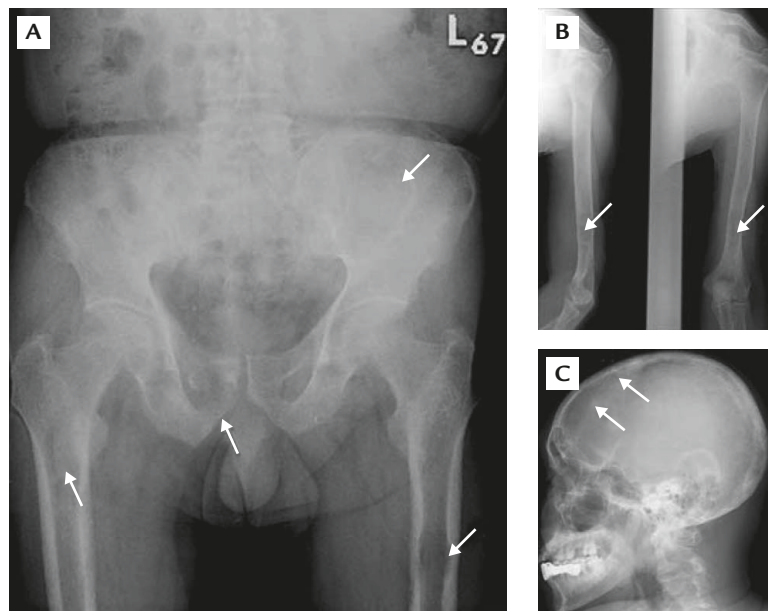


Figure 1. Multiple osteolytic lesions on X-ray examination. (A) Lesions in proximal femurs and pelvic girdle (arrows). (B) Lesions in left humeral shaft (arrows). (C) Typical salt-and-pepper pattern of brown tumor on the skull (arrows).

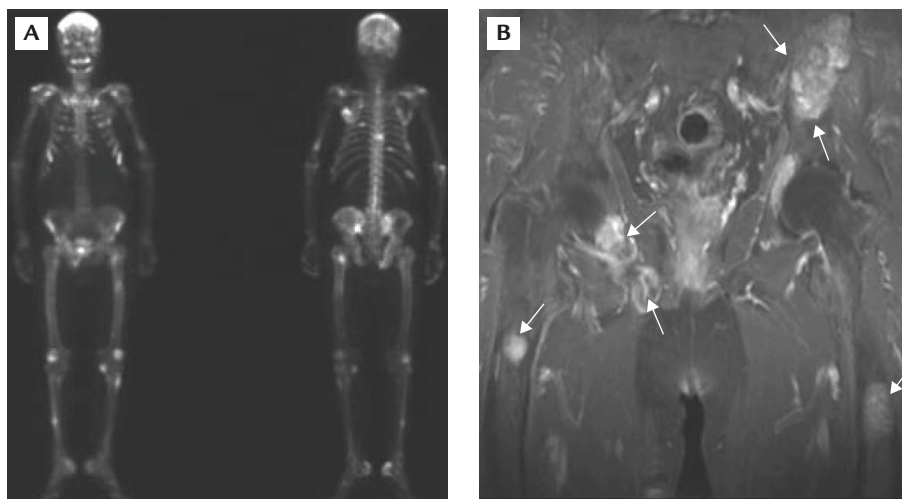


Figure 2. (A) Whole-body bone scan reveals increased uptake in the skeleton. (B) Magnetic resonance image is compatible with multiple osteolytic lesions (arrows).

counts and routine biochemical analyses were normal except for an elevated serum calcium level of 14.3 mg/dL, which led to the consideration of underlying hyperparathyroidism. Subsequent check-ups revealed a high intact-PTH level of 986 pg/mL. For the purposes of ruling out the cause of hyperparathyroidism, sonographic examination was performed and revealed an adenoma, 2.8 cm in diameter, in the right parathyroid gland. Taking account of the new evidence, brown tumor caused by parathyroid adenoma was considered the most likely diagnosis.

To reach the final diagnosis, pathologic analysis was essential. At the same time, the impending pathologic fracture of the patient's left femur was of concern. We therefore performed surgery for the following 2 reasons: (1) to obtain tissue from the lesions for a definite diagnosis; (2) to provide rigid internal fixation to prevent fracture. Subsequent pathologic analysis confirmed the diagnosis of brown tumor (Figure 3). Internal fixation with dynamic compression plate and cemented intramedullary pins was performed successfully. The patient was then able to ambulate with normal gait and without pain.

A general surgeon was consulted and performed right-side parathyroidectomy. Two weeks postoperatively, the serum levels of calcium and PTH had declined to within their normal ranges. The multiple osteolytic lesions resolved, and the patient was symptom-free at the latest follow-up visit.

Discussion

Brown tumor, also known as generalized osteitis fibrosa cystica or Von Recklinghausen disease of the bone, comprises only a small percentage of osteolytic bony pathologies.³ It is caused by hyperparathyroidism, which may be primary, secondary or tertiary. Primary parathyroidism due to parathyroid adenoma is one of the leading causes of brown tumor. In our case, the increased secretion of intact-PTH from the parathyroid adenoma triggered high osteoclast turnover activity, leading to multiple pure osteolytic lesions.⁴

Metastatic bone tumor is a rational consideration for every clinician whenever multiple osteolytic lesions are found. It would be logical to complete a tumor survey including bone scan, chest and abdominal imaging and relevant laboratory studies including cell counts, biochemical analyses and tumor marker levels.^{5,6} However, since other etiologies such as multiple myeloma or brown tumor should also be considered,^{7,8} serum phosphate, calcium and PTH levels and serum protein electrophoresis should be checked before the

whole set of tumor survey is initiated. In our case, the increased uptake on whole-body bone scan and lack of albumin/globulin ratio reversal rendered multiple myeloma less likely. The significantly elevated serum calcium level was a clue that pointed toward metabolic bone disease.⁹ Although hypercalcemia with high intact-PTH level and imaging evidence of parathyroid adenoma all indicated that brown tumor was highly possible, it was only with pathologic proof after surgical biopsy that a definite diagnosis was reached.

From an orthopedic point of view, the risk of pathologic fracture is of concern when the brown tumor corrupts over 2 thirds of the cortex of the long bone, especially in the weight-bearing area.¹⁰ In our patient, the current practice standard of preventive internal fixation with bone cement augmentation was performed to manage the impending fracture. Open biopsy was done concurrently for diagnosis. The remaining brown tumors were expected to resolve after treatment of the primary hyperparathyroidism.^{11,12} Preventive internal fixation is not indicated if the tumor does not involve more than two-thirds of the weight-bearing long bone cortex.

The importance of accurate diagnosis cannot be overemphasized. The patient would have been treated with chemotherapy if the diagnosis had been metastasis of unknown origin. This would have not only left the true problems unsolved but also harmed the patient. Instead, with the correct diagnosis of brown tumor caused by parathyroid adenoma, the key treatment was excision of the adenoma. Except for impending pathologic fracture, the multiple osteolytic lesions require no further orthopedic surgery since they would resolve following normalization of serum intact-PTH level.

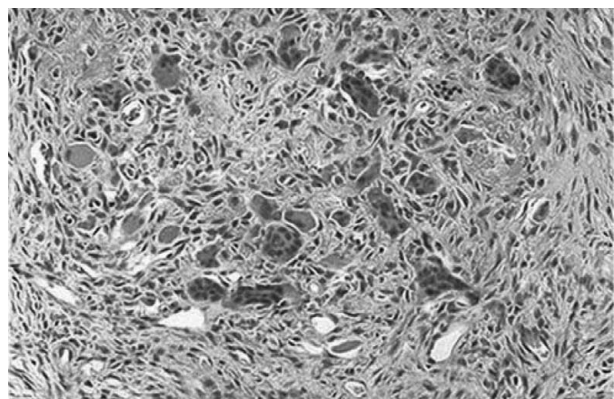


Figure 3. Pathology of the tumor sample taken from the patient's left femur. The center of the brown tumor contains osteoclasts, mononuclear cells and fibroblasts. Focal hemorrhage containing hemosiderin produces the grossly brown color.

Accordingly, we summarize the keystones of accurately diagnosing the rarely seen brown tumor as follows. First, be highly alert. Always review the patient's profile and laboratory data. Serum phosphate, calcium and PTH levels and serum protein electrophoresis should be included in routine survey for multiple osteolytic lesions. Second, brown tumor should always be on the clinician's list of differential diagnoses when multiple osteolytic lesions are encountered.

We have reported a case of rarely seen metabolic bony pathology mimicking the presentation of metastatic bone tumor. Accurate diagnosis enabled the proper treatment to be carried out, avoiding unnecessary harm to the patient. The patient became free from the fear of malignancies, and the risk of pathologic fractures was also diminished.

References

1. Souza ER, Scignoli JA, Bezerra FC, Ribeiro SL, Passos LF. Devastating skeletal effects of delayed diagnosis of complicated primary hyperparathyroidism because of ectopic adenoma. *J Clin Rheumatol* 2008;14:281-4.
2. Damron TA, Morris C, Rougraff B, Tamurian R. Diagnosis and treatment of joint-related tumors that mimic sports-related injuries. *Instr Course Lect* 2009;58:833-47.
3. Khalil PN, Heining SM, Huss R, Ihrler S, Siebeck M, Hallfeldt K, Euler E, et al. Natural history and surgical treatment of brown tumor lesions at various sites in refractory primary hyperparathyroidism. *Eur J Med Res* 2007;12:222-30.
4. Syed Z, Khan A. Skeletal effects of primary hyperparathyroidism. *Endocr Pract* 2000;6:385-8.
5. Rougraff BT, Kneisl JS, Simon MA. Skeletal metastases of unknown origin: a prospective study of a diagnostic strategy. *J Bone Joint Surg Am* 1993;75:1276-81.
6. Sim FH. *Diagnosis and Management of Metastatic Bone Disease: A Multidisciplinary Approach*. New York: Raven Press, 1998.
7. Gould CF, Ly JQ, Lattin GE Jr, Beall DP, Sutcliffe JB 3rd. Bone tumor mimics: avoiding misdiagnosis. *Curr Probl Diagn Radiol* 2007;36:124-41.
8. Polat P, Kantarci M, Alper F, Koruyucu M, Suma S, Onbaş O. The spectrum of radiographic findings in primary hyperparathyroidism. *Clin Imaging* 2002;26:197-205.
9. Lafferty FW. Differential diagnosis of hypercalcemia. *J Bone Miner Res* 1991;6(Suppl):S51-9; discussion S61.
10. Khosla S, Melton J 3rd. Fracture risk in primary hyperparathyroidism. *J Bone Miner Res* 2002;17(Suppl):N103-7.
11. VanderWalde LH, Liu IL, O'Connell TX, Haigh PI. The effect of parathyroidectomy on bone fracture risk in patients with primary hyperparathyroidism. *Arch Surg* 2006;141:885-91.
12. Simon MA, Springfield D. *Surgery for Bone and Soft Tissue Tumors*. Philadelphia: Lippincott-Raven, 1998.