

# Comparisons of Mechanical Versus Phase-array Intracardiac Echocardiography-assisted Transseptal Puncture in Patients With Dilated Left Atrium Undergoing Percutaneous Transvenous Mitral Commissurotomy

Kae-Woei Liang<sup>1,2,3\*</sup>, Yun-Ching Fu<sup>4,5</sup>, Wen-Lieng Lee<sup>1,2,3</sup>, Kuo-Yang Wang<sup>1,6</sup>, Chih-Tai Ting<sup>1,2,3</sup>, Sheng-Ling Jan<sup>4,5</sup>, Wei-Wen Lin<sup>1,7</sup>, I-Hsiang Lin<sup>8</sup>

<sup>1</sup>Cardiovascular Center and <sup>4</sup>Department of Pediatrics, Taichung Veterans General Hospital, Taichung; <sup>2</sup>Cardiovascular Research Center, and Departments of <sup>3</sup>Medicine and <sup>5</sup>Pediatrics, National Yang-Ming University School of Medicine, Taipei; <sup>6</sup>Department of Medicine, Chung Shan Medical University, and <sup>7</sup>Department of Medicine, China Medical University, Taichung; <sup>8</sup>Department of Medicine, Nantou Hospital, Nantou, Taiwan, R.O.C.

**Background:** Percutaneous transvenous mitral commissurotomy (PTMC) is an effective treatment for mitral stenosis, but transseptal puncture carries a certain risk of complications. Our previous report has shown the effectiveness of phase-array intracardiac echocardiography (ICE)-guided transseptal puncture in patients with dilated left atrium undergoing PTMC. However, there are few reports comparing the new-generation mechanical versus phase-array ICE-guided transseptal puncture in PTMC.

**Methods:** Between March 2007 and March 2008, 6 consecutive patients with symptomatic mitral stenosis with dilated left atrium (range, 4.1–6.1 cm) underwent transseptal puncture by mechanical ICE guidance in PTMC by the same experienced operator. The procedural, echocardiographic and clinical results were retrospectively retrieved and analyzed. In addition, phase-array ICE-guided transseptal cases ( $n=7$ ), which included consecutive cases from May to December 2008, were compared.

**Results:** All 6 patients could have fossa ovalis visualized by ICE, and none of them had false transseptal puncture. Mechanical ICE provided a panoramic wider view of the interatrium septum, and offered better knowledge of the needle's geographic contact to the fossa ovalis than did the phase-array system. The fluoroscopic time of PTMC in the mechanical ICE-guided group ( $37 \pm 9$  minutes,  $n=6$ ) was similar ( $p=0.465$ ) to that of phase-array guidance ( $31 \pm 15$  minutes,  $n=7$ ).

**Conclusion:** Mechanical ICE is effective in guiding transseptal puncture in PTMC. [*J Chin Med Assoc* 2010;73(9): 471–476]

**Key Words:** cardiac catheterization (transseptal, percutaneous transvenous mitral commissurotomy, PTMC), echocardiography (intracardiac echocardiography, ICE), mitral valve stenosis

## Introduction

Percutaneous transvenous mitral commissurotomy (PTMC) is an effective and minimally invasive treatment for symptomatic mitral stenosis.<sup>1,2</sup> In patients with suitable mitral valve scores, it can produce benefits

equal to those of open commissurotomy.<sup>3</sup> Traditional PTMC was first undertaken by making a transseptal puncture guided by landmarks generated by an atrial angiogram.<sup>1</sup> However, in cases with giant left atrium or other unique anatomy that distorted the traditional landmarks, difficulties were encountered.<sup>4</sup> It also



\*Correspondence to: Dr Kae-Woei Liang, Cardiovascular Center, Taichung Veterans General Hospital, 160, Section 3, Taichung Kang Road, Taichung 407, Taiwan, R.O.C.  
E-mail: ekwliang@gmail.com • Received: February 1, 2010 • Accepted: May 26, 2010

involved the risk of false puncture with cardiac tamponade, contrast medium exposure and prolonged fluoroscopic time.

Intracardiac echocardiography (ICE) can help better delineate the border of the septum, clearly visualize the relative positions of the catheter, needle, and septum, and confirm entry into the left atrium.<sup>5,6</sup> It also eliminates the need for contrast medium exposure, and spares unnecessary multiple or false punctures. ICE-guided transseptal puncture preserves the advantages of transesophageal echocardiography guidance while eliminating the need for intravenous sedation or prolonged oral scope intubation, and improves patient comfort.<sup>7</sup> Presently, there are 2 types of commercial ICE systems: phase-array and mechanical transducer. Our previous report documented the usefulness of phase-array ICE guidance in transseptal puncture for PTMC.<sup>8,9</sup> The mechanical ICE catheter is only equipped with a 2-dimensional function, is not flexible, and is similar to an intravascular ultrasound catheter, with a rotating ultrasound transducer driven by a motor unit at the opposite end of a braided drive shaft, generating a 360-degree image perpendicular to the catheter.<sup>6,10</sup> Phase-array ICE catheter has flexibility with 4-way steering capability, and color Doppler function and uses electronically controlled multiple transducers affixed to 1 side of the catheter shaft, producing a wedge-shaped image sector, similar to that of the transesophageal echocardiography probe. Mechanical transducer ICE guidance is easy for image reading and catheter manipulation, demanding only simple advancement of ICE catheter into the right atrium.<sup>11</sup> Mechanical ICE also has a better near-field (right atrium) view and has much cheaper catheter cost compared to phase-array ICE. To date, there are only a limited number of reports about new-generation mechanical ICE-guided transseptal puncture in PTMC and few reports comparing it with phase-array ICE or conventional atrial angiogram guidance. Herein, we retrospectively review our experiences with mechanical ICE-guided transseptal puncture, particularly regarding its effectiveness in image guidance and procedural fluoroscopic time in patients undergoing PTMC.

## Methods

### *Study patients*

Phase-array ICE (Cypress Echocardiography System; Siemens Medical, Mountain View, CA, USA) was available in this institution beginning from the year 2005. However, it was out of order from March 2007 to March 2008. Before it was repaired, we used a

mechanical ICE system (Galaxy Echocardiography System; Boston Scientific, Natick, MA, USA). Between March 2007 and March 2008, 6 consecutive patients with symptomatic mitral stenosis with dilated left atrium (range, 4.1–6.1 cm) underwent transseptal puncture by mechanical ICE guidance in PTMC by the same experienced operator at Taichung Veterans General Hospital in Taichung, Taiwan. Another 7 consecutive cases from May to December 2008 with phase-array ICE assistance were used for comparison. The procedural, echocardiographic and clinical results were retrospectively retrieved and analyzed. Informed consent was obtained from the patients. The study protocol was approved by the Institutional Review Board of Taichung Veterans General Hospital.

### *Imaging modalities*

Complete transthoracic echo and transesophageal echocardiography examinations were performed prior to the PTMC procedure. For mechanical catheter, a Convoy (9 Fr) long sheath (Boston Scientific) was first placed via the left femoral vein to the inferior vena cava, and then an ICE catheter (9 Fr) (Ultra ICE; Boston Scientific) was introduced via the long sheath into the right atrium. For phase-array catheter, a 10-Fr ICE catheter (AcuNav Catheter; Siemens Medical) was introduced via an 11-Fr short sheath placed in the left femoral vein and advanced into the right atrium. The right femoral vein was used for transseptal access to the left atrium and insertion of the Inoue balloon catheter. Mechanical ICE images were displaced on a Galaxy Echocardiography System (Boston Scientific); while phase-array ICE images were shown on a Cypress Echocardiography System (Siemens Medical). Fluoroscopy was performed with a biplane digital angiographic system (Philips Medical Systems, Andover, MA, USA).

### *PTMC procedures*

Coronary angiograms and routine hemodynamic measurements including cardiac output (Fick method), pulmonary artery, left atrial, and left ventricular pressures, and transmitral pressure gradients were obtained according to standard and conventional PTMC procedures (except the transseptal puncture). Using real-time ICE image guidance, the interatrium septum border and fossa ovalis could be clearly delineated. A tenting sign could be obtained in all the patients once the Mullins catheter abutted the fossa ovalis with probing pressure. After catheter contact with the fossa ovalis was confirmed, the Brockenbrough needle was forced across the interatrium septum. The mitral valve balloon crossing and inflation were undertaken with

fluoroscopic guidance according to conventional practice. After initial balloon inflation, immediate assessment of mitral commissure splitting, and mitral valve area by 2-dimensional planimetry and mitral regurgitation by color Doppler were performed by on-site transthoracic echocardiography. Repeat measurements of hemodynamic parameters (including pulmonary artery and left atrial pressure, transmitral pressure gradient, left-to-right shunting and cardiac outputs) were performed according to standard protocol. Procedural and fluoroscopic times (for the entire PTMC procedure) were recorded. Transthoracic echocardiography was repeated 1 month after PTMC to assess mitral valve area increment post treatment.

### Statistical analysis

The mean ( $\pm$  standard deviation) was used for continuous variables. Differences in continuous variables were assessed by Student's *t* test or Mann-Whitney U test as appropriate. Pre- and post-PTMC mitral valve areas were compared using paired Student's *t* test. Categorical variables were compared by  $\chi^2$  test with or without Yates' correction or Fisher's exact test as indicated. SPSS version 12.1 (SPSS Inc., Chicago, IL, USA) was used for all calculations. A *p* value of less than 0.05 was accepted as being statistically significant.

## Results

### Baseline demographic data

Baseline demographic data were similar in the mechanical and phase-array ICE groups. The mean pre-procedure mitral valve score was  $6 \pm 1$  in both groups.<sup>12</sup> Baseline mitral valve area was  $1.3 \pm 0.3$  cm<sup>2</sup>, pre-PTMC transmitral pressure gradient was  $19 \pm 8$  mmHg, and left atrium size ranged from 4.1 to 6.1 cm in the mechanical ICE group, which were not statistically different from those of the phase-array ICE group (Table 1).

### Transseptal puncture under mechanical catheter vs. phase-array ICE guidance

In the mechanical ICE-guided group, there was a clear image of the interatrium septal border and fossa ovalis in all patients and, in particular, a better near-field panoramic geographic relationship between the transseptal needle and right atrium for avoiding false right atrium free wall probing (Figure 1A). Before transseptal needle puncture was performed, the septal tenting sign as the Mullin catheter probed against the septum was seen in all patients (Figure 1B). Further, we could visualize a clear real-time image of the catheter

**Table 1.** Baseline data of patients undergoing PTMC with mechanical versus phase-array ICE guidance in transseptal puncture\*

	Mechanical ICE (n=6)	Phase-array ICE (n=7)	<i>p</i>
Age (yr)	56 $\pm$ 14	54 $\pm$ 10	0.822
Sex (M/F)	0/6	2/5	0.462
Baseline MV area (cm <sup>2</sup> )	1.3 $\pm$ 0.3	1.0 $\pm$ 0.2	0.060
MV score	6 $\pm$ 1	6 $\pm$ 1	0.975
LA size (cm)	5.0 $\pm$ 0.7	5.4 $\pm$ 0.4	0.237
Baseline PA pressure (mmHg)	46 $\pm$ 12	59 $\pm$ 20	0.188
Pre-PTMC trans-MV PG (mmHg)	19 $\pm$ 8	11 $\pm$ 5	0.054

\*Data presented as mean  $\pm$  standard deviation or *n*. PTMC=percutaneous transvenous mitral commissurotomy; ICE=intracardiac echocardiography; MV=mitral valve; LA=left atrium; PA=pulmonary artery; PG=pressure gradient.

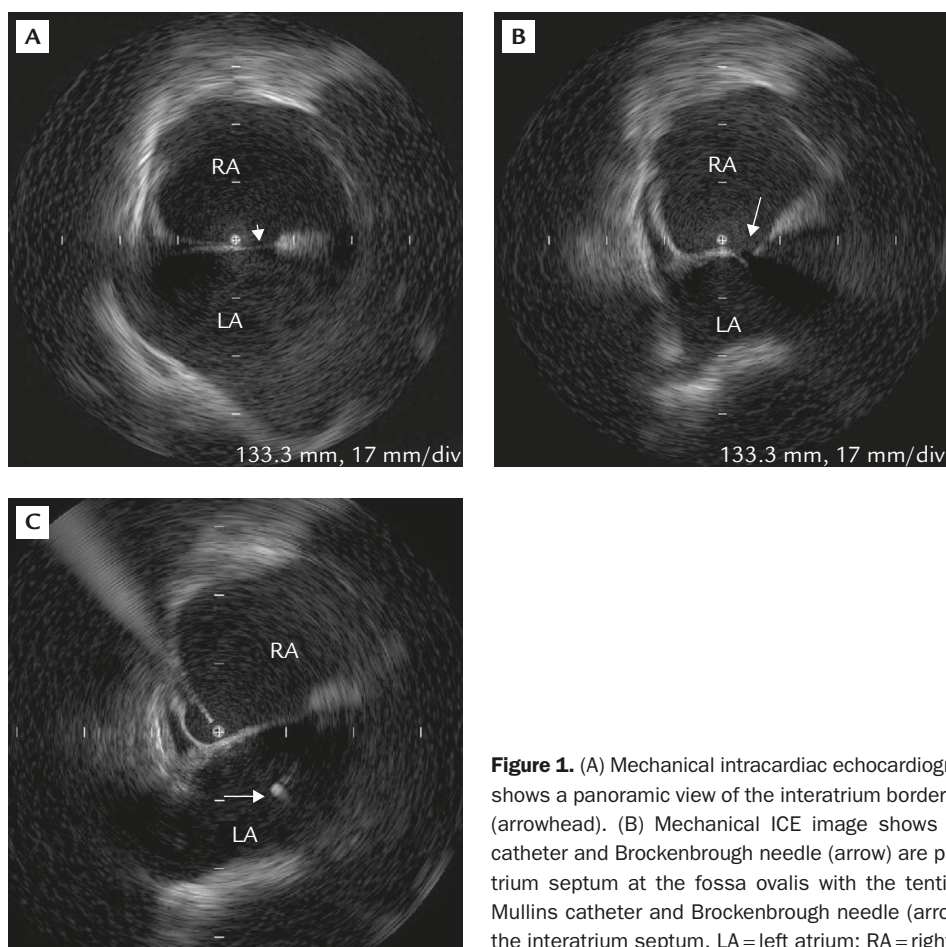
and needle entering the left atrium (Figure 1C). In the phase-array ICE-guided group, a clear image of the interatrium septal border and fossa ovalis was also seen in all patients (Figure 2A). However, the scanned interatrial border width was limited by a pie-shaped wedge sector view of the phase-array system. Before performance of transseptal needle puncture, the septal tenting sign as the Mullin catheter probed against the septum was seen in all patients (Figure 2B). Further, in phase-array ICE, we could visualize a clear real-time image of the catheter and needle entering the left atrium as well (Figure 2C).

### Immediate results of PTMC

The mean decrease in transmitral valve pressure gradient was  $10 \pm 5$  mmHg in the mechanical ICE group (*n*=6) and  $6 \pm 5$  mmHg in the phase-array ICE group (*n*=7) (*p*=0.228). None of the patients in either the phase-array or mechanical group experienced false transseptal puncture or embolic event. Mean fluoroscopy time was  $37 \pm 9$  minutes in the mechanical group and  $31 \pm 15$  minutes in the phase-array ICE group (*p*=0.465) during the total PTMC. Mean procedural time for PTMC was  $144 \pm 47$  minutes in the mechanical group (*n*=6) and  $134 \pm 23$  minutes in the phase-array group (*n*=7), which was not significantly different (*p*=0.613; Table 2). ICE-guided transseptal puncture also spared 50 mL of contrast medium used for right atrial angiogram by the Inoue method.

## Discussion

PTMC has been an effective and well-documented treatment for mitral stenosis since the 1980s. Though application of mechanical ICE in PTMC was reported



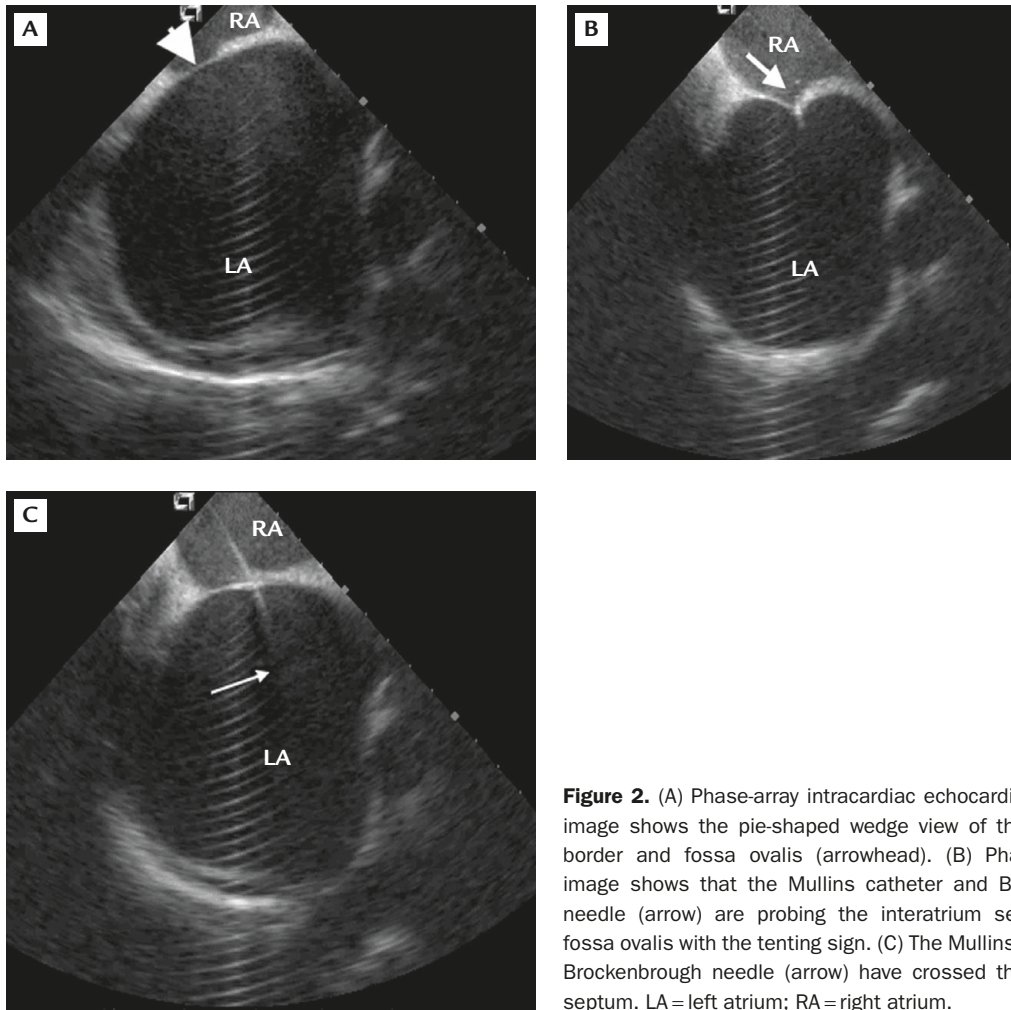
**Figure 1.** (A) Mechanical intracardiac echocardiography (ICE) image shows a panoramic view of the interatrium border and fossa ovalis (arrowhead). (B) Mechanical ICE image shows that the Mullins catheter and Brockenbrough needle (arrow) are probing the interatrium septum at the fossa ovalis with the tenting sign. (C) The Mullins catheter and Brockenbrough needle (arrow) have crossed the interatrium septum. LA = left atrium; RA = right atrium.

as early as 1993, the ICE catheter at that time had a higher echo beam frequency, shorter scan depth and poor resolution.<sup>6,10,13</sup> In recent years, the mechanical ICE catheter profile (9 Fr), echo beam frequency (9 MHz) and imaging quality have greatly improved. To date, there are only a few reports on newer-generation mechanical ICE-guided transseptal puncture for PTMC, and limited reports on comparisons of mechanical versus phase-array ICE or atrial angiogram-guided transseptal puncture. Our experiences showed that newer generation mechanical ICE is simple and safe in guiding transseptal puncture in PTMC, with fluoroscopic and procedural time similar to those of phase-array guidance.

In patients with rheumatic mitral stenosis, a dilated or huge left atrium is not an uncommon problem. ICE guidance to ascertain fossa ovalis position before transseptal puncture can ensure procedure safety for PTMC. Mechanical ICE has an echo beam frequency of 9 MHz with a penetration depth of about 5 cm.<sup>14</sup> It has a better 360-degree panoramic near-field image of the right atrium, interatrial border, fossa ovalis and

the transseptal needle, but poorer distal scan of the left atrium, left atrial appendage and mitral apparatus. Mechanical ICE is easier to use for the transseptal procedure because of a better geographic knowledge of the transseptal needle and a wider interatrial border scanned by rotational panoramic echo beams. The cost of mechanical ICE catheters is much cheaper, about US\$1,000, which is about one-third the cost of a phase-array catheter. All 6 patients in our series had their fossa ovalis visualized by mechanical ICE, and all showed a reassuring tenting sign before puncture.

Phase-array ICE (AcuNav; Siemens Medical) has an echo beam frequency of 5–10 MHz with a penetration depth up to 16 cm. It has a pie-shaped wedge view, which limits its near-field sight in the right atrium and interatrial border, but has a better distal view of the left atrium, appendage and mitral apparatus. In addition, phase-array ICE has Doppler (pulse wave, continuous wave, and color Doppler) function and an expanded usage in evaluating shunt, valve regurgitation and pressure gradient. Moreover, the phase-array ICE catheter is deflectable and steerable and can be



**Figure 2.** (A) Phase-array intracardiac echocardiography (ICE) image shows the pie-shaped wedge view of the interatrium border and fossa ovalis (arrowhead). (B) Phase-array ICE image shows that the Mullins catheter and Brockenbrough needle (arrow) are probing the interatrium septum at the fossa ovalis with the tenting sign. (C) The Mullins catheter and Brockenbrough needle (arrow) have crossed the interatrium septum. LA = left atrium; RA = right atrium.

**Table 2.** Immediate results of PTMC with mechanical versus phase-array ICE-guided transseptal puncture

	Mechanical ICE (n=6)	Phase-array ICE (n=7)	p
Post-PTMC trans-MV PG* (mmHg)	9 ± 6	4 ± 2	0.127
Reduction of trans-MV PG* (mmHg)	10 ± 5	6 ± 5	0.228
Post-PTMC MV area* (cm <sup>2</sup> )	1.9 ± 0.4	1.8 ± 0.4	0.605
Fluoroscopy time*† (min)	37 ± 9	31 ± 15	0.465
Procedural time*† (min)	144 ± 47	134 ± 23	0.613
Visualizing fossa ovalis by ICE (+tenting sign) (%)	100	100	> 0.99
Number of erroneous transseptal punctures	0 ± 0	0 ± 0	> 0.99
Contrast medium exposure for atrial angiogram (mL)	0	0	> 0.99
Tamponade (%)	0	0	> 0.99
Embolic events (%)	0	0	> 0.99

\*Data presented as mean ± standard deviation; †fluoroscopy or procedural time of PTMC included the times of pre- and post-PTMC hemodynamic measurements, ICE catheter placement, manipulations, transseptal procedure, coronary angiography and balloon mitral commissurotomy. PTMC = percutaneous transvenous mitral commissurotomy; ICE = intracardiac echocardiography; MV = mitral valve; PG = pressure gradient.

advanced to the right ventricle and pulmonary artery to obtain multiple views without the need for a long guide sheath for advancement.

As public health improves, the prevalence of rheumatic mitral stenosis has declined dramatically in the

past 20 years, especially in developed countries, thus limiting interventionists to accumulate PTMC experience and transseptal competence. The fluoroscopic time of PTMC in the mechanical ICE-guided group (37 ± 9 minutes, n = 6) from our series was similar to that

from atrial angiogram-guided data ( $30 \pm 17$  minutes,  $n=64$ ) by Park et al<sup>7</sup> ( $p=0.325$ ). Though ICE did not help shorten the fluoroscopic time of PTMC, as shown by our data, it could help beginners to perform the transeptal procedure safely and confidently with online real-time guidance.

The limitations of this study included its small case number, procedures performed by a single experienced operator, and being a retrospective experience review in a single center. Further large-scale prospective study is needed to provide statistical comparisons.

In conclusion, mechanical ICE is effective in guiding transeptal puncture and offers a simple and safe approach for patients with dilated left atrium undergoing PTMC.

## Acknowledgments

This study was supported in part by grants from Taichung Veterans General Hospital (TCVGH grant numbers 973102B and 973109C) and the Yen Tjing Ling Medical Foundation, Taiwan (CI-97-12). The authors would like to thank the Biostatistics Taskforce of Taichung Veterans General Hospital for statistical support.

## References

- Inoue K, Owaki T, Nakamura T, Kitamura F, Miyamoto N. Clinical application of transvenous mitral commissurotomy by a new balloon catheter. *J Thorac Cardiovasc Surg* 1984;87:394-402.
- Hung JS, Chern MS, Wu JJ, Fu M, Yeh KH, Wu YC, Cherng WJ, et al. Short- and long-term results of catheter balloon percutaneous transvenous mitral commissurotomy. *Am J Cardiol* 1991;67:854-62.
- Lau KW, Ding ZP, Hung JS. Percutaneous transvenous mitral commissurotomy versus surgical commissurotomy in the treatment of mitral stenosis. *Clin Cardiol* 1997;20:99-106.
- Hung JS. Atrial septal puncture technique in percutaneous transvenous mitral commissurotomy: mitral valvuloplasty using the Inoue balloon catheter technique. *Cathet Cardiovasc Diagn* 1992;26:275-84.
- Green NE, Hansgen AR, Carroll JD. Initial clinical experience with intracardiac echocardiography in guiding balloon mitral valvuloplasty: technique, safety, utility, and limitations. *Catheter Cardiovasc Interv* 2004;63:385-94.
- Hung JS, Fu M, Yeh KH, Wu CJ, Wong P. Usefulness of intracardiac echocardiography in complex transeptal catheterization during percutaneous transvenous mitral commissurotomy. *Mayo Clin Proc* 1996;71:134-40.
- Park SH, Kim MA, Hyon MS. The advantages of on-line transesophageal echocardiography guide during percutaneous balloon mitral valvuloplasty. *J Am Soc Echocardiogr* 2000;13:26-34.
- Liang KW, Fu YC, Lee WL, Liu TJ, Wang KY, Hsueh CW, Lin IH, et al. Intra-cardiac echocardiography guided trans-septal puncture in patients with dilated left atrium undergoing percutaneous transvenous mitral commissurotomy. *Int J Cardiol* 2007;117:418-21.
- Chang WC, Lin IH, Ting CT, Liang KW. Balloon mitral commissurotomy for mitral stenosis after resolution of a large mobile left atrial thrombus by 2-year warfarin treatment. *J Chin Med Assoc* 2009;72:646-9.
- Hung JS, Fu M, Yeh KH, Chua S, Wu JJ, Chen YC. Usefulness of intracardiac echocardiography in transeptal puncture during percutaneous transvenous mitral commissurotomy. *Am J Cardiol* 1993;72:853-4.
- Cooper JM, Epstein LM. Use of intracardiac echocardiography to guide ablation of atrial fibrillation. *Circulation* 2001;104:3010-3.
- Wilkins GT, Weyman AE, Abascal VM, Block PC, Palacios IF. Percutaneous balloon dilatation of the mitral valve: an analysis of echocardiographic variables related to outcome and the mechanism of dilatation. *Br Heart J* 1988;60:299-308.
- Chiang CW, Huang HL, Ko YS. Echocardiography-guided balloon mitral valvotomy: transesophageal echocardiography versus intracardiac echocardiography. *J Heart Valve Dis* 2007;16:596-601.
- Kim SS, Hijazi ZM, Lang RM, Knight BP. The use of intracardiac echocardiography and other intracardiac imaging tools to guide noncoronary cardiac interventions. *J Am Coll Cardiol* 2009;53:2117-28.