

# MRI Diagnosis of Fibrolipomatous Hamartoma of the Median Nerve and Associated Macrodystrophia Lipomatosa

Chia-Ling Chiang<sup>1</sup>, Meng-Yuan Tsai<sup>1</sup>, Clement Kuen-Huang Chen<sup>1,2,3\*</sup>

<sup>1</sup>Department of Radiology, Kaohsiung Veterans General Hospital, Kaohsiung, <sup>2</sup>Department of Medical Imaging, Chi Mei Medical Center, Tainan, and <sup>3</sup>National Yang-Ming University School of Medicine, Taipei, Taiwan, R.O.C.

Fibrolipomatous hamartoma is an uncommon congenital disorder, which is characterized by disproportionate hyperplasia of adipose tissue infiltrating along the perineurium, the epineurium and the affected nerve trajectory. We present a case of combined fibrolipomatous hamartoma and macrodystrophia lipomatosa of the median nerve. The involved sites included the left palm, wrist and forearm. Part of the patient's middle finger had been amputated due to previous macrodystrophia lipomatosa; however, the lesion continued to enlarge and was accompanied by numbness. Magnetic resonance imaging demonstrated a typical fibrolipomatous hamartoma with high signal intensity of fat on both T1-weighted and T2-weighted images, characteristic coaxial cable appearance on axial images, and spaghetti appearance on sagittal images. A similar skipped lesion at the median nerve of the middle forearm was also noted. To the best of our knowledge, this has not been reported in the English literature. [*J Chin Med Assoc* 2010;73(9):499–502]

**Key Words:** fibrolipomatous hamartoma, macrodystrophia lipomatosa, magnetic resonance imaging, median nerve

## Introduction

Fibrolipomatous hamartoma is a rare benign tumor, characterized by an anomalous overgrowth of fibroadipose tissue between and around nerve bundles, which thus causes enlargement of the affected nerve.<sup>1</sup> The median nerve and its branches are most commonly affected, followed by the radial nerve, ulnar nerve, nerves at the dorsal aspect of the foot, brachial plexus and cranial nerves.<sup>1,2</sup> About two-thirds of patients with nerve fibrolipomatous hamartoma may have coexisting macrodystrophia lipomatosa.<sup>3</sup> Macrodystrophia lipomatosa is a rare non-hereditary congenital macrodactyly, manifesting diffuse mesenchymal hyperplasia, especially fibroadipose tissue. It is usually accompanied by periosteal and endosteal new bone formation.<sup>4–6</sup>

We present a case of macrodystrophia lipomatosa associated with fibrolipomatous hamartoma of the median nerve at the wrist with an unusual proximal extension to the forearm and a skipped lesion. To our

knowledge, skipped lesion of affected median nerve has never been reported.

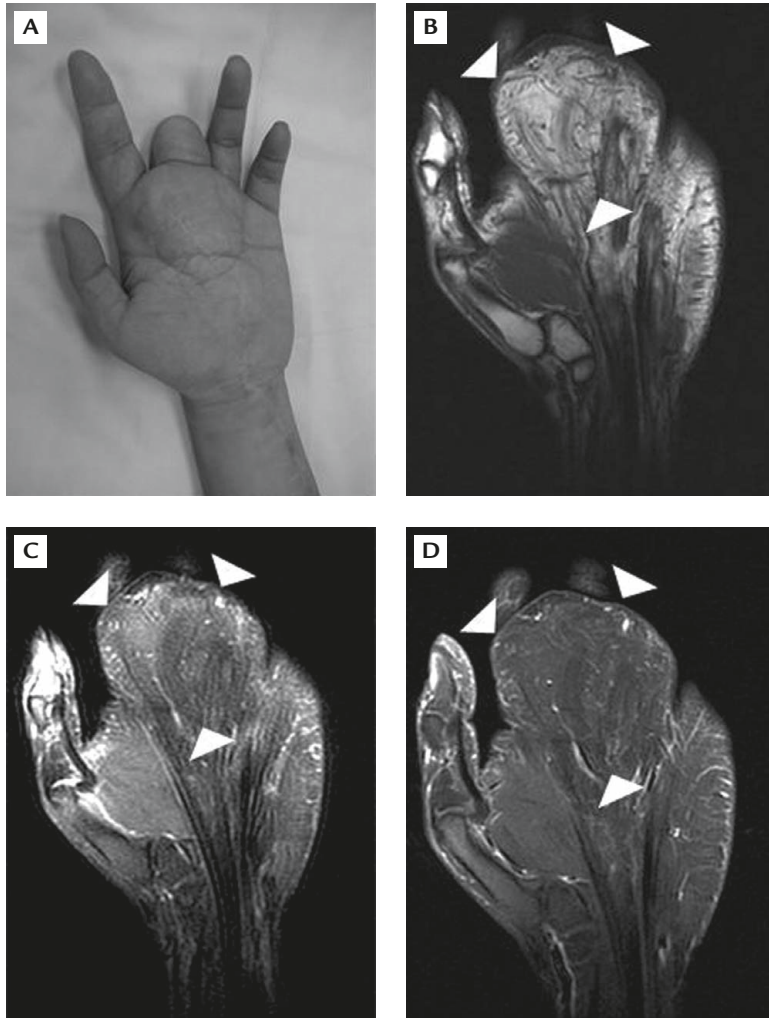
## Case Report

A 28-year-old man was referred to our plastic surgery clinic with complaints of large left middle finger and puffy hand. He had a palpable, nontender mass of the volar aspect of his left middle finger, extending to the palm and the wrist. The slowly growing mass had been noticed since his birth. There was no discoloration, nevus, skin defect, or pitting edema over the mass. Because of the enlarged distal and middle phalanges, his middle finger had been amputated for cosmetic reasons when he was 4 years old (Figure 1).

He was born a term baby without any other congenital disorder or associated family history. The patient complained about the persistent growing of the mass and numbness sensation over the palm and the 1<sup>st</sup> to



\*Correspondence to: Dr Clement Kuen-Huang Chen, Department of Medical Imaging, Chi Mei Medical Center, 901, Chung Hwa Road, Yong Kang City, Tainan 710, Taiwan, R.O.C.  
E-mail: ckhc821@gmail.com • Received: June 4, 2009 • Accepted: June 8, 2010



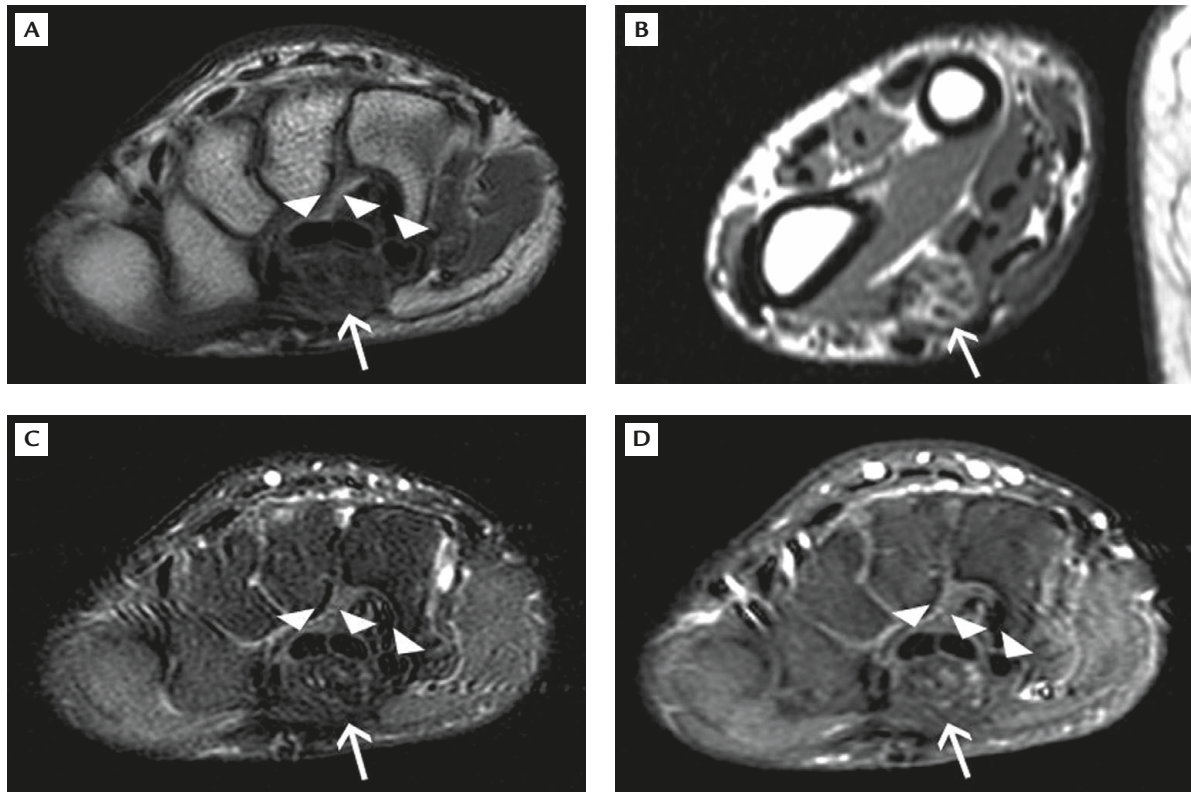
**Figure 1.** A 28-year-old man with macrodystrophia lipomatosa at the 3<sup>rd</sup> ray of the left hand. Part of his enlarged middle finger had been amputated when he was 4 years old. (A) Photograph of the volar aspect of the left hand showing local gigantism with a large palpable and hard mass along the 3<sup>rd</sup> ray, extending from the carpus to the stump of the long finger. The mass lesion (arrowheads): (B) exhibited a typical fat signal with hyperintensity on coronal spin echo T1-weighted imaging; (C) was signal void on fat-suppressed fast spin echo proton density-weighted imaging; and (D) showed no enhancement after intravenous gadolinium administration on fat-suppressed spin echo T1-weighted imaging.

4<sup>th</sup> fingers after the amputation. At the age of 25 years, he had a second operation in another hospital that specialized in symptom relief. During the operation, the surgeon noted a large amount of adipose tissue along the trajectory of the median nerve, which extended to the proximal forearm. The wrist lesion was confirmed to be neural fibrolipoma after biopsy. His symptoms improved postoperatively but relapsed several months later. The patient was then referred to our hospital owing to recurrent tumor growth and symptoms.

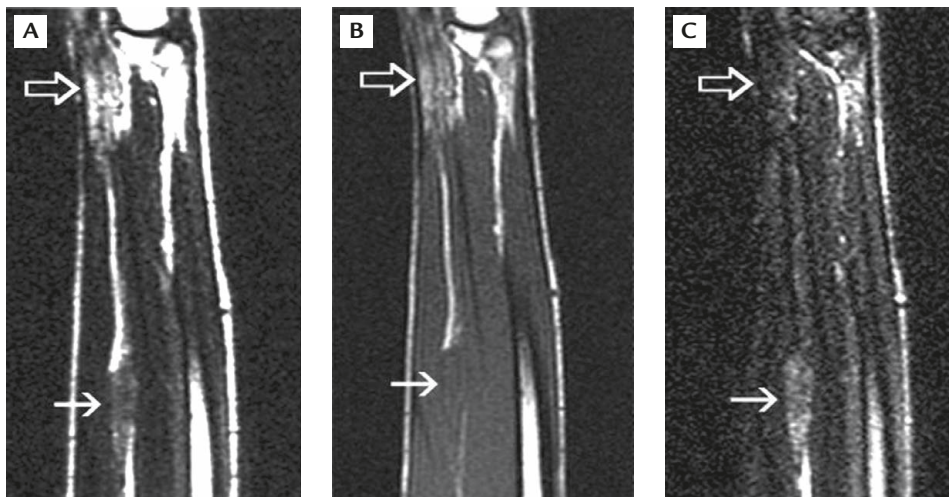
At our plastic surgery clinic, a neurological examination revealed decreased sensation in the 1<sup>st</sup> to 4<sup>th</sup> fingers and the palm. Nerve conduction study demonstrated chronic axonal degeneration of the median nerve. Sonographic and magnetic resonance imaging (MRI) studies were requested to evaluate carpal tunnel syndrome.

Radiographs of the affected hand, wrist and forearm revealed mild enlargement of the proximal phalanx of the 3<sup>rd</sup> finger stump accompanied by prominent low density soft tissue surrounding the finger stump and

3<sup>rd</sup> metacarpal, which extended to the volar aspect of the wrist. MRI of the hand confirmed soft tissue hypertrophy along the volar aspect of the 3<sup>rd</sup> metacarpal and the finger stump. The soft tissue lesion had high signal intensity on spin echo (SE) T1-weighted imaging, was signal void on fat-suppressed imaging, and had no contrast enhancement after intravenous gadolinium administration (Figure 1). At the level of the carpal tunnel and distal forearm, the deposition of fat tissue along the nerve fascicles resulted in prominent enlargement of the median nerve with characteristic coaxial cable appearance on axial imaging (Figure 2) and spaghetti appearance on sagittal imaging (Figure 3). The MRI features were consistent with fibrolipomatous hamartoma of the median nerve associated with macrodystrophia lipomatosa. Another skipped lesion of the median nerve was noted in the middle third of the forearm. It presented with fusiform enlargement, fat signal and poor contrast enhancement. The intervening segment of the median nerve between the 2 lesions was normal in caliber and signal intensity.



**Figure 2.** Fibrolipomatous hamartoma of the median nerve, presenting with numbness over the 1<sup>st</sup> to 4<sup>th</sup> fingers, palm and distal forearm of the left upper extremity. Axial spin echo T1-weighted imaging of the: (A) wrist and (B) distal forearm shows the enlarged median nerve with characteristic coaxial cable appearance (arrows in A–D) of fibrolipomatous hamartoma and dorsal displacement of the flexor tendons (arrowheads in A, C, D). (C) Axial fat-suppressed fast spin echo proton density-weighted imaging and (D) gadolinium-enhanced spin echo T1-weighted imaging of the wrist show fat suppression and poor contrast enhancement.



**Figure 3.** Sagittal magnetic resonance imaging of the forearm shows spaghetti appearance (open arrows) of the enlarged median nerve and a skipped lesion (arrows) in the proximal forearm: (A) spin echo T1-weighted image; (B) fast spin echo T2-weighted image; (C) fast spin echo T2-weighted image with fat suppression.

## Discussion

Fibrolipomatous hamartoma, also known as neural fibrolipoma or lipomatosis of nerve (WHO classification),<sup>4</sup> was first reported in the English literature in 1953.<sup>1</sup> Fibrolipomatous hamartoma is composed of a disproportionate amount of fibroadipose tissue

infiltrating the perineurium and epineurium surrounding nerve bundles and causes fusiform enlargement of the affected nerve.<sup>2</sup> The median nerve and its branches are most commonly affected, followed by the radial nerve, ulnar nerve, nerves at the dorsal aspect of the foot, brachial plexus and cranial nerves.<sup>1,2</sup> MRI is the key diagnostic tool. Surgical biopsy is unnecessary for

fibrolipomatous hamartoma lesions that demonstrate the typical MRI findings of coaxial cable appearance on axial imaging and spaghetti appearance on coronal or sagittal imaging.<sup>1,2,7</sup> The etiopathogenesis remains unknown, but a congenital, abnormal growth of fibroadipose tissue of the nerve sheath is believed to be the most likely mechanism.<sup>2</sup> Histological examination usually discloses fibrolipomatous proliferation that surrounds and separates the nerve bundles and follows their branching pattern.<sup>1,3,8</sup> The reported age of onset ranges from birth to 25 years. About 22–67% of patients with fibrolipomatous hamartoma may have associated macrodactyly, or macrodystrophia lipomatosa if it is present at birth.<sup>1</sup>

Macrodystrophia lipomatosa was first described by Feriz in 1925.<sup>9</sup> In addition to the proliferation of fibroadipose tissue unilaterally, conventional radiographs show characteristic findings of hypertrophic bone overgrowth, involving the median or plantar nerve trajectory of 1 or more of the digits of the extremities. But it ceases spontaneously at puberty for unknown reason.<sup>8</sup>

The relationship between fibrolipomatous hamartoma and macrodystrophia lipomatosa is not clear, and may be confusing due to similar MRI findings and histological expression of fat deposition and nerve fibrosis. Therefore, fibrolipomatous hamartoma with or without associated macrodactyly is thought to be a proper term.<sup>1</sup>

Fibrolipomatous hamartoma is usually located in the carpal tunnel and extends distally to the palm or fingers. The proximal portion of the median nerve above the wrist is rarely involved. In a review study, the proximal end of lesions of 5 of 6 patients with isolated fibrolipomatous hamartoma of the median nerve were identified in the distal forearm at the level of the pronator quadratus.<sup>7</sup> In our case, the skipped lesion of the affected median nerve in the proximal forearm was confirmed by imaging studies and pathology. The finding of skipped lesion of affected median nerve, to

the best of our knowledge, has not been previously reported.

The main goals of management of fibrolipomatous hamartoma with or without macrodystrophia lipomatosa are symptomatic relief and cosmetic considerations since total tumor resection cannot be achieved without sacrificing the affected nerve. Multiple or debulking surgeries, instead, are often adopted.<sup>8</sup>

Fibrolipomatous hamartoma with or without macrodystrophia lipomatosa is an uncommon disease. Radiographic, ultrasonographic and MRI features may lead to accurate diagnosis and obviate unnecessary biopsy. Finally, in addition to the wrist, fibrolipomatous hamartoma of the median nerve may co-occur in the middle forearm.

## References

1. Van Breuseghem I, Scirot R, Pans S, Geusens E, Brys P, De Wever I. Fibrolipomatous hamartoma in the foot: atypical MR imaging findings. *Skeletal Radiol* 2003;32:651–5.
2. Nouira K, Belhiba H, Baccar S, Miaaoui A, Ben Messaoud M, Turki I, Cheour I, et al. Fibrolipoma of the median nerve. *Joint Bone Spine* 2007;74:98–9.
3. Kakitsubata Y, Theodorou SJ, Theodorou DJ, Shibata M, Yuge M, Yuki Y, Hatakeyama K, et al. MR imaging of uncommon recurrence of fibrolipomatous hamartoma of the ulnar nerve. *Acta Radio* 2003;44:326–8.
4. Blacksin M, Barnes FJ, Lyons MM. MR diagnosis of macrodystrophia lipomatosa. *AJR Am J Roentgenol* 1992;158:1295–7.
5. Watt AJ, Chung KC. Macrodystrophia lipomatosa: a reconstructive approach to gigantism of the foot. *J Foot Ankle Surg* 2004; 43:51–5.
6. Turkington JRA, Grey AC. MR imaging of macrodystrophia lipomatosa. *Ulster Med J* 2005;74:47–50.
7. Toms AP, Anastakis D, Bleakney RR, Marshall TJ. Lipofibromatous hamartoma of the upper extremity: a review of the radiologic findings for 15 patients. *AJR Am J Roentgenol* 2006;186: 805–11.
8. Brodwater BK, Major NM, Goldner RD, Layfield LJ. Macrodystrophia lipomatosa with associated fibrolipomatous hamartoma of the median nerve. *Pediatr Surg Int* 2000;16:216–8.
9. Feriz H. Makrodystrophia lipomatosa progressive. *Virchows Arch* 1925;260:308–68.